

Imaging Features and Sonographically Guided Core-Needle Biopsy of Facial Myopericytoma: A Case Report¹

안면부 근혈관주위세포종의 영상소견 및 초음파유도하 핵심검: 증례 보고¹

Sang Kwon Lee, MD¹, Sun Young Kwon, MD²

Departments of ¹Radiology, ²Pathology, Dongsan Medical Center, Keimyung University School of Medicine, Daegu, Korea

We report imaging and pathologic findings of myopericytoma of the face, in a 75-year-old woman, which was diagnosed by a sonographically guided core-needle biopsy (US-CNB). The mass was well-demarcated and intensely enhanced on a CT scan and was markedly hypervascular on a power Doppler ultrasonography. Histological findings of the specimens, obtained by US-CNB, were consistent with myopericytoma. While myopericytoma of the face appears markedly hypervascular on imaging, the histological diagnosis can be established safely with US-CNB, without significant bleeding, if sufficient manual compression is applied.

Index terms

Face
Myopericytoma
Tomography, X-Ray Computed
Ultrasonography
Needle Biopsy

INTRODUCTION

Myopericytoma is a rare recently delineated truly pericytic neoplasm, characterized by a perivascular proliferation of round-to-spindle pericytic cells of myoid differentiation (1-3). Several series of myopericytoma cases have been reported, but most of them were focused on clinical and pathologic features (3-5). As such, the imaging features of myopericytoma of the head and neck have rarely been described in the literature (6-8), to our knowledge. The use of sonographically guided core-needle biopsy (US-CNB) for histological diagnosis of myopericytoma seems to be troublesome, presumably because of the highly vascular nature of this entity, thus, the risk of bleeding. We recently have tested the availability of US-CNB in the histological diagnosis of myopericytoma of the neck, and demonstrated that US-CNB can be safely used for this purpose without significant complications (8).

We, herein, report a case of myopericytoma of the face, diag-

nosed preoperatively by US-CNB in a 75-year-old woman, along with its CT, sonographic, and pathologic features.

CASE REPORT

A 75-year-old woman was presented with a palpable mass on her face, which was noticed 12 years ago. She had visited our medical center 10 years prior when she had felt pain at the site of the mass. Physical exam at that time had disclosed a bean-sized mass on the left lower face. Palpation-guided fine-needle aspiration biopsy had been non-diagnostic. She had left the lesion alone thereafter. On physical examination, approximately 10 × 20-mm-sized, non-tender, mobile mass was found at the left lower face, adjacent to the mandibular body. No palpable mass elsewhere or cervical lymphadenopathy was noted. All laboratory tests were within normal limits. Multidetector CT performed by using a Sensation 64 scanner (Siemens, Erlangen, Germany) showed an approximately 20 × 14 × 14-mm-sized mass on the

Received June 10, 2012; Accepted July 16, 2012

Corresponding author: Sang Kwon Lee, MD
Department of Radiology, Dongsan Medical Center,
Keimyung University School of Medicine,
56 Dalseong-ro, Jung-gu, Daegu 700-712, Korea.
Tel. 82-53-250-7735 Fax. 82-53-250-7766
E-mail: sklee@dsmc.or.kr

Copyrights © 2012 The Korean Society of Radiology

left lower face, just lateral to the left mandibular body (Fig. 1A, B). The mass was well-demarcated and slightly hypoattenuating, compared with muscular structures of the neck on a non-enhanced CT (NECT) (Fig. 1A), and showed homogeneous, intense enhancement (as intense enhancement as vascular structures) on contrast-enhanced CT (CECT) (Fig. 1B). Sonographic examination was performed using an Acuson Sequoia 512 scanner (Siemens Medical Solutions, Mountain View, CA, USA), equipped with an 8- to 15-MHz linear array transducer. The mass was well-demarcated, homogeneous, and markedly hypoechoic on gray-scale ultrasonography (US) (Fig. 1C), and showed marked hypervascularity on a power Doppler (PD) US (Fig. 1D). In view of CT and sonographic features, our tentative

diagnosis was myopericytoma. The surgeon requested US-CNB for histological diagnosis and to exclude other possible diagnoses, such as schwannoma, Castleman disease of hyaline vascular type, angioleiomyoma, and solitary fibrous tumor. Because of the intense enhancement and marked hypervascularity of the mass on CECT and PD US, bleeding could be a major possible complication. We reevaluated the raw data CT images with slice thickness of 1.0 mm and PD US, and noticed that there were no identifiable arterial feeders around the mass or large vascular structures within the mass. We cautiously performed US-CNB by using a freehand technique with a 16-gauge needle (Bard Peripheral Technologies, Covington, GA, USA) and spring-loaded, single-action biopsy gun (Pro-Mag 2.2,

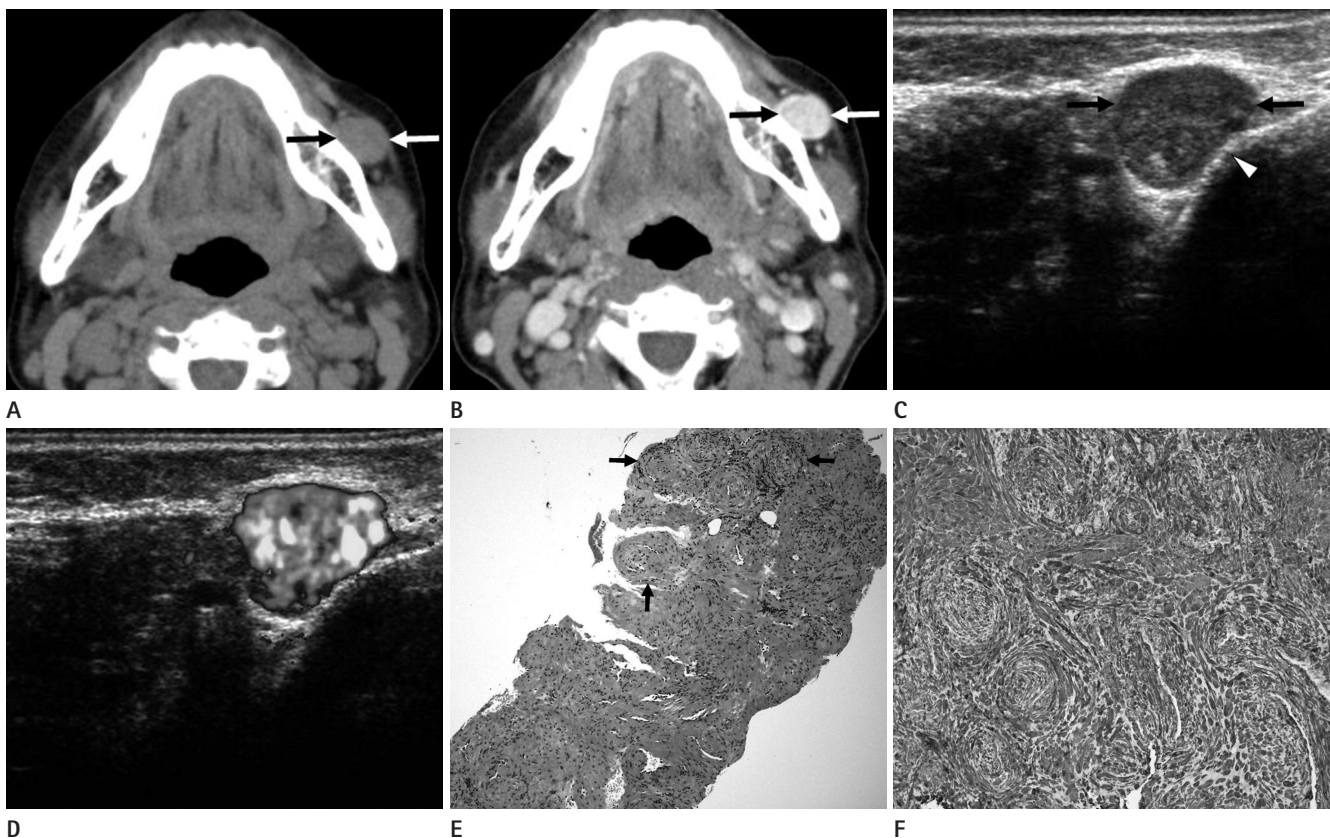


Fig. 1. Myopericytoma of the face, diagnosed by sonographically guided core-needle biopsy (US-CNB), in a 75-year-old woman.

A. A non-enhanced CT image shows an ovoid mass (arrows) at the left lower face adjacent to the mandibular body. The mass is slightly hypoattenuating compared with the sternocleidomastoid muscle.

B. A contrast-enhanced CT image reveals homogeneous, intense enhancement (as intense enhancement as vascular structures) of the mass (arrows).

C. A gray-scale sonographic image shows a well-demarcated, homogeneous, and markedly hypoechoic solid mass (arrows), adjacent to the mandibular body (arrowhead).

D. A power Doppler sonographic image reveals marked hypervascularity of the mass.

E. A photomicrograph of low-power view of the specimen obtained by US-CNB of the mass reveals distinctive multilayered, concentric, perivascular arrangement of the spindle-shaped cells around the blood vessels (arrows) (Hematoxylin & Eosin staining, $\times 40$).

F. The immunohistochemical staining of the specimen, obtained by US-CNB, for smooth muscle actin (SMA) reveals diffuse and strong immunoreactivity of the perivascular myoid cells (SMA, $\times 200$).

Manan Medical Products, Northbrook, IL, USA) with the excursion length of 15 mm. Three samples were obtained from the mass for histological examination and immunohistochemical study. No findings of hemorrhage were noted within and around the mass on sonographic monitoring, during and after the procedure. With the application of a manual compression of the lesion for approximately 20 minutes, the patient experienced no significant bleeding during and after the procedure. The histological and immunohistochemical examinations of the specimen obtained by US-CNB demonstrated distinctive multilayered, concentric, perivascular arrangement of the spindle-shaped cells, around the blood vessels (Fig. 1E), and diffuse and strong immunoreactivity of the perivascular myoid cells for smooth muscle actin (SMA) (Fig. 1F), respectively. These findings were consistent with myopericytoma. The patient underwent surgical excision of the mass. The final pathology of the surgical specimen confirmed the diagnosis. The postoperative course was uneventful, and there has been no evidence of tumor recurrence until 20 months after surgery.

DISCUSSION

Pericytes were first described by Zimmermann (9), as specialized cells normally present around the capillaries. They were thought to be modified smooth muscle cells. Histologically, myopericytomas are recognized by the presence of a distinctive concentric perivascular proliferation of round-to-spindle pericytes with eosinophilic cytoplasm and a myoid appearance, which are arranged circumferentially around vascular lumina in an "onion skin" (multilayered) pattern (1-3). These perivascular cells are characteristically reactive for muscle-specific actin and SMA, which are consistent with pericytic/myoid differentiation (1-3). Myopericytoma has a propensity to occur in the dermis and subcutaneous layer of the extremities in middle-aged adults (3). Most myopericytomas are benign lesions, though a few malignant cases have also been described (4). Recurrence has been reported in 10-20% of patients with myopericytoma. Recurrence has been hypothesized because of the extension of cords of tumor beyond the main lesion, or as a reflection of multifocal disease (10). Myopericytoma may be associated with trauma (10).

We have previously reported two case of myopericytoma of

the neck, one in a 51-year-old man and the other in a 70-year-old woman (6, 8), diagnosed by excisional biopsy and US-CNB, respectively. Common imaging features of the previous two cases and present case of myopericytoma were a well-demarcated, slightly hypoattenuating mass, compared with the muscular structures with homogeneous, intense enhancement (as intense enhancement as vascular structures) on NECT and CECT, and a markedly hypoechoic mass with marked hypervascularity on gray-scale and PD US. Except for the heterogeneity of the mass of the first case (6) in a 51-year-old man, which might be associated with the size of the mass, the sonographic and CT features of the previous cases were nearly identical to those of the present case. Chu et al. (7) reported CT features of a case of myopericytoma, involving the superficial lobe of the parotid gland. The mass was 5 cm in size, poorly defined, heterogeneous with central hypoattenuating area on NECT, and revealed central irregular non-enhancing area and peripheral enhancement on CECT. The CT features of Chu et al. (7) were quite different from those of our previously reported (6, 8) and present cases. We hypothesized that the difference in size of the mass may be responsible for the difference in CT features between the case of Chu et al. (7) and those of ours (6, 8). In addition to myopericytoma, the differential diagnosis of a well-demarcated, highly vascular soft tissue mass of the head and neck includes hypervascular metastasis (especially from the papillary thyroid carcinoma, renal cell carcinoma, and choriocarcinoma), Castleman disease of hyaline vascular type, paraganglioma, schwannoma, hemangioma, angioleiomyoma, solitary fibrous tumor, and nodular fasciitis. In most studies regarding myopericytoma, the diagnosis has been established by histological and immunohistochemical examinations of the surgical specimen (3, 7). Although, it is a simple, safe, and inexpensive procedure, sonographically guided fine-needle aspiration biopsy (US-FNAB) is of limited value for lesions that require immunohistochemical staining, as in myopericytoma. In contrast, US-CNB is a safe, effective, and time-efficient procedure if it were performed by an experienced physician. The use of coaxial guiding needle might diminish the tissue injury. Furthermore, immunohistochemical examination of the specimens, which were obtained by US-CNB, will enhance the diagnostic accuracy.

Our case represents myopericytoma of the face, the preoper-

ative diagnosis of which was established by US-CNB. In the previous case (6), we had performed US-FNAB. The cytological findings consisted of scattered cellular nests, which comprised oval-to-spindle tumor cells. These cytological features might be seen in various entities; thus, these were not fully diagnostic of myopericytoma. In contrast, the histological and immunohistochemical findings of the specimens, obtained by US-CNB in the previous (8) and present cases, provided a definitive diagnosis.

The rationale of US-CNB for preoperative diagnosis of myopericytoma is that it enables therapeutic option to be determined and explained, preoperatively. Given the intense enhancement on CECT and extensive color signals, throughout the entire mass on PD US, there was a risk of bleeding associated with US-CNB. However, no significant bleeding was noted during and after the procedure. Because of the superficial location of the mass, manual compression was sufficient for preventing the post-procedural bleeding.

We suggest myopericytoma as an alternative diagnostic possibility for a well-demarcated, highly vascular soft tissue mass of the face. Despite of its marked hypervascularity, on CECT and PD US, US-CNB may be available and even safe for the histological diagnosis of myopericytoma of the head and neck, because its superficial location enables the manual compression possible; thus, it can prevent bleeding during and after the procedure.

REFERENCES

1. Granter SR, Badizadegan K, Fletcher CD. Myofibromatosis in adults, glomangiopericytoma, and myopericytoma: a spectrum of tumors showing perivascular myoid differentiation. *Am J Surg Pathol* 1998;22:513–525
2. Gengler C, Guillou L. Solitary fibrous tumour and haemangiopericytoma: evolution of a concept. *Histopathology* 2006;48:63–74
3. Mentzel T, Dei Tos AP, Sapi Z, Kutzner H. Myopericytoma of skin and soft tissues: clinicopathologic and immunohistochemical study of 54 cases. *Am J Surg Pathol* 2006;30:104–113
4. McMenamin ME, Fletcher CD. Malignant myopericytoma: expanding the spectrum of tumours with myopericytic differentiation. *Histopathology* 2002;41:450–460
5. Dray MS, McCarthy SW, Palmer AA, Bonar SF, Stalley PD, Marjoniemi V, et al. Myopericytoma: a unifying term for a spectrum of tumours that show overlapping features with myofibroma. A review of 14 cases. *J Clin Pathol* 2006;59:67–73
6. Lee SK, Kwon SY. Gray-scale and power Doppler sonography and CT findings of myopericytoma of the posterior cervical space. *AJNR Am J Neuroradiol* 2009;30:1604–1606
7. Chu ZG, Yu JQ, Yang ZG, Zhu ZY, Yuan HM. Myopericytoma involving the parotid gland as depicted on multidetector CT. *Korean J Radiol* 2009;10:398–401
8. Rho BH, Lee SK, Kwon SY. Myopericytoma of the neck: sonographic appearance and sonographically guided needle biopsy. *J Clin Ultrasound* 2011;39:469–472
9. Zimmermann KW. Der feinere Bau der Blutcapillaren. *Z Anat Entwicklungsgesch* 1923;68:29–109
10. Laga AC, Tajirian AL, Islam MN, Bhattacharyya I, Cohen DM, Plamondon CJ, et al. Myopericytoma: report of two cases associated with trauma. *J Cutan Pathol* 2008;35:866–870

안면부 근혈관주위세포종의 영상소견 및 초음파유도하 핵생검: 증례 보고¹

이상권¹ · 권선영²

초음파유도하 핵생검에 의해 진단된 75세 여자 환자의 안면부에 발생한 근혈관주위세포종의 영상소견과 병리소견을 보고하고자 한다. 근혈관주위세포종은 CT에서 경계가 분명하며, 강한 조영증강을 보이는 종괴로, 강화도플러 초음파검사에서는 현저히 과다한 혈관분포를 보이는 종괴로 관찰되었다. 초음파유도하 핵생검에 의해 얻어진 검체의 조직학적 소견은 근혈관주위세포종과 일치하였다. 안면부의 근혈관주위세포종은 영상에서 현저히 과다한 혈관분포를 보이지만, 조직학적 진단을 위한 초음파유도하 핵생검은 충분한 압박만으로도 출혈 없이 안전하게 시행될 수 있을 것으로 생각된다.

계명대학교 의과대학 동산의료원 ¹영상의학과, ²병리과