

## Urachal Actinomycosis : CT Findings in Two Patients<sup>1</sup>

Jin Young Jung, M.D., Hee Jin Kim, M.D., Sang-Wook Yoon, M.D., Kyoung Ah Kim, M.D.,  
Man Deuk Kim, M.D., Jin-hyung Heo, M.D.<sup>2</sup>

Actinomycosis involving the urachal remnant is extremely rare. Urachal actinomycosis may mimic urachal carcinoma and other infectious conditions of the urachal remnant or the abdominal wall. We report computed tomography (CT) findings of actinomycosis involving the urachal remnant in two patients who were surgically treated.

**Index words :** Urachus

Actinomycosis

Carcinoma

Tomography, X-ray computed

Actinomycosis is a rare, chronic suppurative infection caused by the Gram-positive anaerobic filamentous bacterium, *Actinomyces Israeli*. Actinomycosis involving the urachal remnant is extremely rare and can mimic urachal carcinoma or other infectious conditions (1, 2). Because of the nonspecific clinical presentation, the diagnosis of urachal actinomycosis is usually made by surgery followed by a histopathologic examination. The radiologic findings of urachal actinomycosis are rarely reported. We report the CT findings of actinomycosis involving the urachal remnant in two patients who were treated and confirmed by wide excision and partial cystectomy.

### Case Report

#### Case 1

A 45-year-old woman presented with a progressively enlarging, painful infraumbilical mass for a month. No other symptoms, such as fever, weight loss or changes in bowel or urinary habits, were present. An intrauterine contraceptive device had been in place for two years. White blood cell count was 8,600 /mm<sup>3</sup>, with 76.7% of segmented neutrophils. Upon physical examination, a 20 cm sized tender firm mass was palpable at the infraumbilical region.

Transabdominal ultrasonography revealed a predominantly solid mass abutted on the dome of the urinary bladder, with a diffusely thickened urinary bladder wall (Fig. 1A). Contrast enhanced abdominal and pelvic CT showed an ill-defined, densely enhancing mass at the midline of the lower abdomen, present from the umbilicus to the dome of the urinary bladder along the course of the urachus, just beneath the abdominal wall (Figs. 1B-D). It contained multiple, small, low attenuating foci, suggesting necrosis. Diffuse mural thickening with dense enhancement was also seen in the adjacent ileum

<sup>1</sup>Department of Radiology, CHA Bundang Medical Center, CHA University

<sup>2</sup>Department of Pathology, CHA Bundang Medical Center, CHA University

Received December 1, 2008 ; Accepted July 17, 2009

Address reprint requests to : Hee Jin Kim, M.D., Department of Radiology, CHA Bundang Medical Center, CHA University, 351, Yatap-dong, Bundang-gu, Seongnam-si, Gyeonggi-do 463-712, Korea.

Tel. 82-31-780-5384 Fax. 82-31-780-5381

E-mail: orionphil@yahoo.co.kr

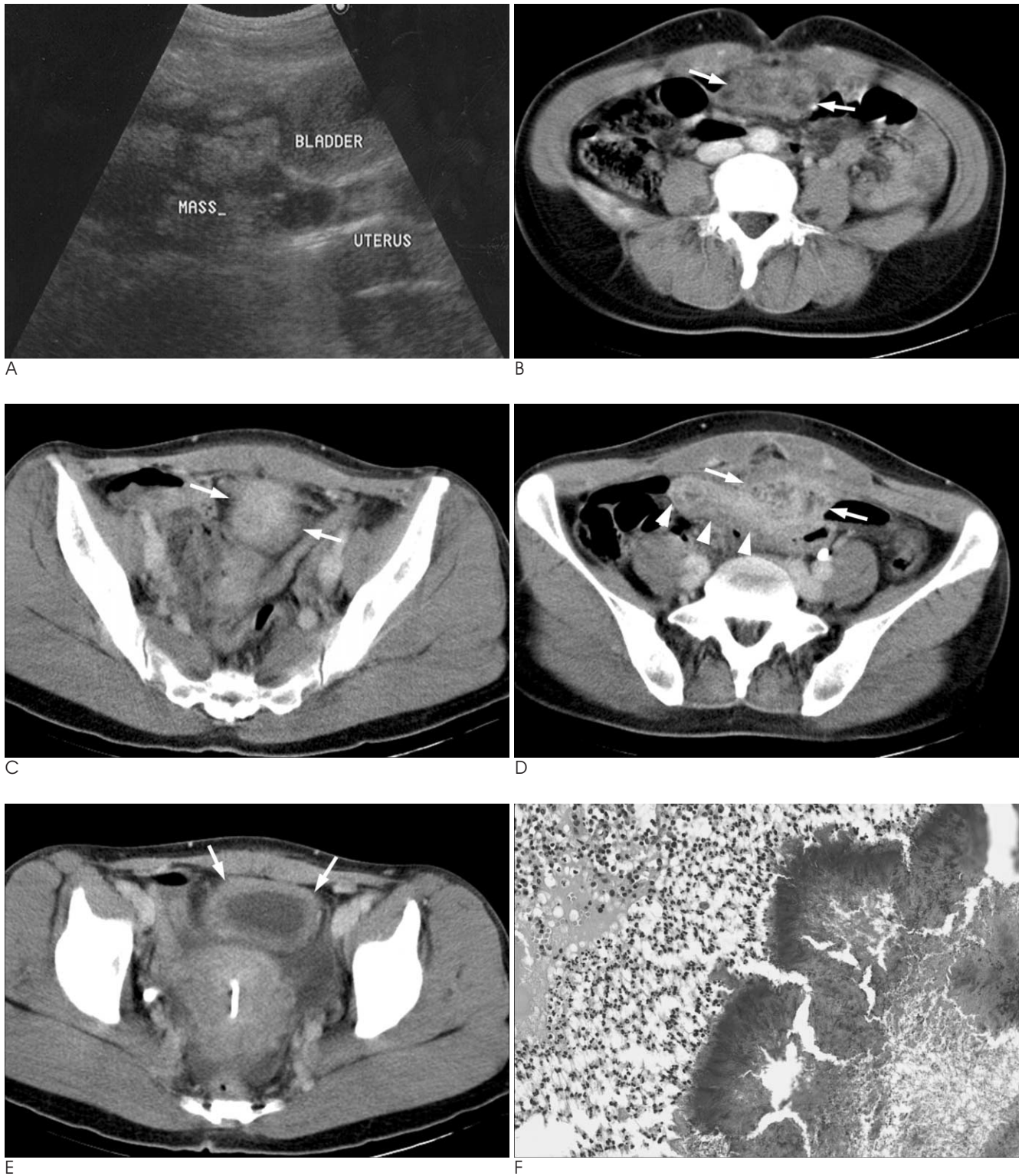


Fig. 1. A 45-year-old woman with urachal actinomycosis. Transabdominal ultrasonography (A) shows a predominantly solid mass abutted to the bladder dome with contiguous, diffuse thickening of the bladder wall. Contrast enhanced abdominal and pelvic CT show an ill-defined heterogeneously enhancing mass (arrows) in the midline of the lower abdomen from the umbilicus to the dome of the bladder, just beneath the abdominal wall, along the course of the urachus (B-D). It contains multiple small, low attenuating foci, suggesting necrosis. Diffuse mural thickening with dense enhancement (arrowheads) is also noted in the adjacent ileum (D). A linear high density intrauterine contraceptive device in the endometrial cavity of the uterus and diffuse mural thickening of the bladder (arrows) are seen (E). Microphotography of the mass (H-E,  $\times 200$ ) illustrates sulfur granules surrounded by neutrophils (F).

and the urinary bladder (Figs. 1D, E). A linear high density intrauterine contraceptive device was seen in the endometrial cavity of the uterus (Fig. 1E). There was no calcification within the mass or any distant metastasis. We therefore could not exclude malignant urachal neoplasm. Infected urachal remnant and malignant urachal neoplasm were included in the differential diagnosis.

Explorative laparotomy found a 15-cm mass involving the dome of the urinary bladder, compatible with an urachal origin, that was severely adhered to the adjacent colon and small bowel. Pathologic examination of frozen sections revealed the lesion to be nonmalignant. The mass, including the adherent small bowel and the dome of the urinary bladder, was excised. Gross examination of the urachal mass revealed small, yellowish abscess pockets. Severe, acute nonspecific suppurative inflammation was demonstrated histologically along the

vesico-urachal sinus tract with an abscess and sulfur granules. Many gram-positive filamentous microorganisms, consistent with *Actinomyces*, were also found (Fig. 1F). Postoperatively, she was treated with high doses of penicillin intravenously for 2 weeks, then orally for an additional 5 months. She remained asymptomatic without evidence of recurrence for 6 years.

## Case 2

A 70-year-old woman presented with abdominal discomfort and infraumbilical abdominal pain for 2 months. She had neither fever nor changes in urinary habits. She had not used an intrauterine contraceptive device before. On the initial laboratory tests, white blood cell count was 10,300 /mm<sup>3</sup>, with 67.1% of segmented neutrophils. The physical examination found no palpable mass in the infraumbilical abdomen.

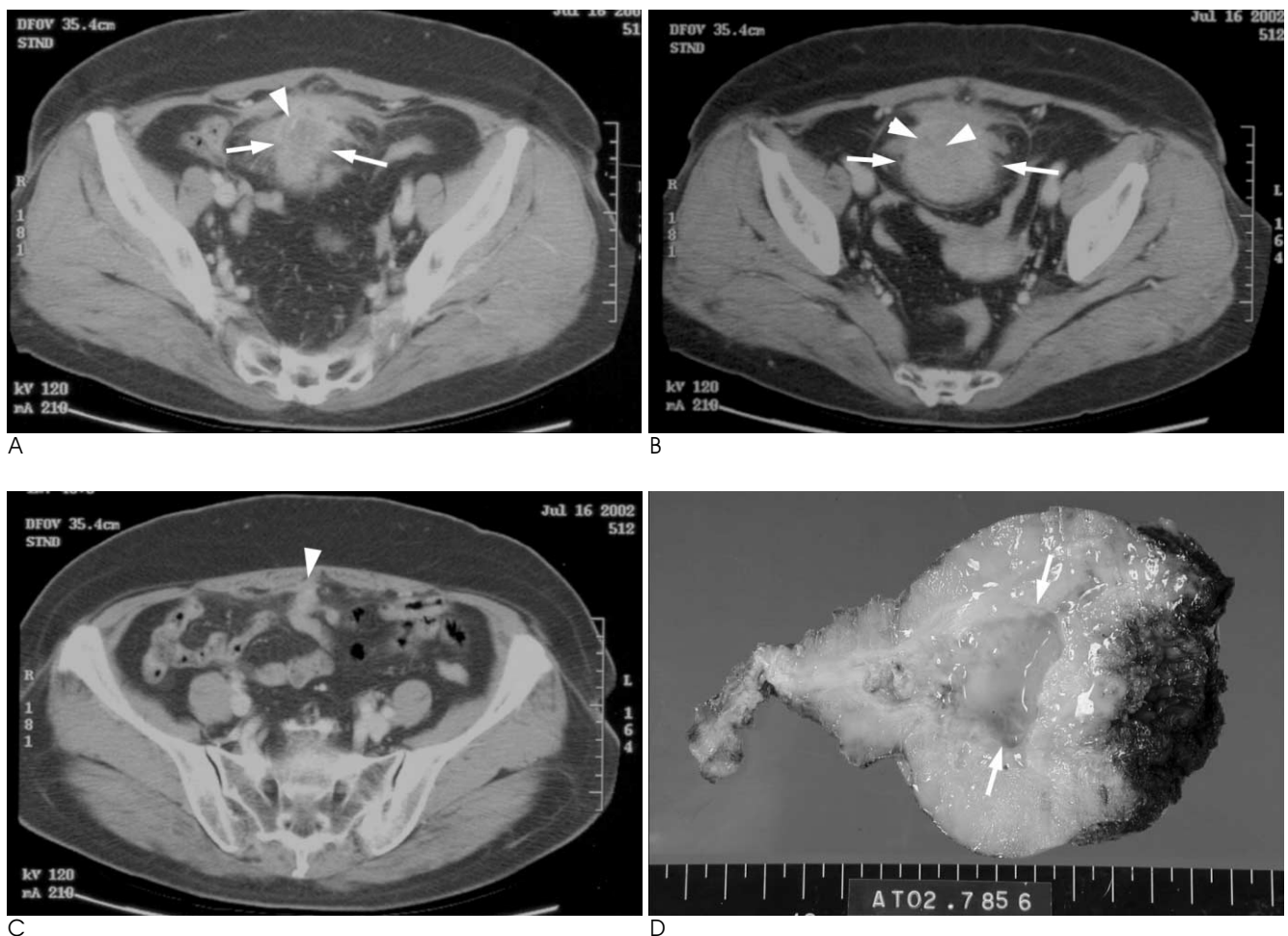


Fig. 2. A 70-year-old woman with urachal actinomycosis. Contrast-enhanced abdominal and pelvic CT (A-C) show a 6 × 5 cm, densely enhancing infiltrative mass (arrows) with internal, low attenuating necrotic foci (arrowheads) in the midline of the lower abdomen (A, B). It shows diffuse mural thickening and dense enhancement with infiltrative borders contiguous to the bladder. At the upper portion of the mass, a thickened median umbilical ligament (arrowhead) is shown (C). Gross examination of the mass on multiple sections revealed an abscess cavity (arrows) containing yellowish pus (D).

Cystoscopy performed at an outside hospital revealed multiple papillary masses at the dome of the urinary bladder. Contrast enhanced abdominal and pelvic CT showed a 6-cm densely enhancing infiltrative mass with internal, low attenuating necrotic foci at the midline of the lower abdomen (Figs. 2A, B). It was abutted on the dome of the urinary bladder. A thickened median umbilical ligament was demonstrated at its upper portion (Fig. 2C). These findings also mimicked malignant urachal neoplasm and she was referred to the urology department for surgery. Laparotomy found a 6-cm supravescical mass contiguous to the dome of the urinary bladder, which is compatible with urachal origins. The mass, together with the dome of the urinary bladder, was excised. Gross examination of the urachal mass on multiple sections revealed an abscess cavity containing yellowish pus (Fig. 2D). Dense inflammatory infiltration with abscess formation and sulfur granules were demonstrated on microscopic examination. Thus, she was diagnosed with actinomycosis involving the urachal remnant and received high doses of penicillin for 6 months. She had no recurrence for 6 years, but did develop urinary incontinence and severe bilateral hydronephrosis with a hydroureter.

## Discussion

Actinomycosis is a rare infectious condition caused by the anaerobic Gram-positive filamentous bacterium, *Actinomyces Israeli*. *Actinomyces Israeli* normally inhabits the oral cavity (especially the tonsils and teeth), the gastrointestinal tract (usually the appendix and colon), and the genital tract in humans. The three most common clinical manifestations of actinomycosis are presented in the cervicofacial, thoracic, and abdominal areas (3). An increased prevalence of actinomycosis in women using intrauterine contraceptive devices has also been reported (1, 4, 5). Prolonged use of an intrauterine contraceptive device can cause a foreign body reaction and concurrent anaerobic pelvic infection. Clinical findings of actinomycosis are nonspecific and variable, depending on the primary or principal site of involvement and the duration of the disease. As a result of the chronic inflammatory nature of actinomycosis, abundant granulation of tissue and dense, fibrous tissue are characteristic pathologic findings. In addition, *Actinomyces* can penetrate through the mucosal barrier by producing proteolytic enzymes, and can directly spread to adjacent tissue. This may result in abscesses, sinus tracts, and fistu-

las surrounded by indurated firm fibrotic tissue. Thus, an aggressive, infiltrative mass with dense enhancement and internal, low attenuating necrotic foci is an important radiologic finding of actinomycosis (3, 6). The definite diagnosis of actinomycosis is usually achieved by histologic identification of sulfur granules, culture of the *Actinomyces*, or both. Actinomycosis is usually treated with antibiotics, but surgery is considered to rule out malignancy, to remove persistent sinuses, to drain abscesses, or to excise necrotic tissue when necessary.

Actinomycosis involving the urachal remnant has rarely been reported. To our knowledge, three previous cases of urachal actinomycosis have been reported, mimicking invasive bladder cancer or malignant urachal neoplasm (1, 2, 7). CT images demonstrated infiltrative masses with heterogeneous enhancement, which were suspected of being invasive bladder cancer or malignant urachal neoplasm in all three cases. *Actinomyces* gains access to the urachus through the umbilicus and an underlying urachal abnormality, such as a cyst or a sinus, can make it susceptible to anaerobic infection (7). Patients with urachal actinomycosis have nonspecific symptoms such as painful palpable masses, weight loss, anorexia, constipation, fever, or chills (1). One of our two patients had a painful palpable abdominal mass, whereas the other had nonspecific abdominal pain and discomfort. CT is generally regarded as a useful imaging modality in determining the anatomic location, extent and characteristics of actinomycosis (3). Actinomycosis involving the urachal remnant is typically located in the midline of the abdomen from the umbilicus to the dome of the bladder, just beneath the abdominal wall, along the course of the urachus (2). However, the typical location of actinomycosis involving the urachal remnant may not differentiate urachal actinomycosis from malignant urachal neoplasm.

Most urachal tumors are adenocarcinomas (90%), although the urachus is normally lined with transitional epithelium. These result from metaplasia of the urachal mucosa into columnar epithelium, followed by malignant transformation (8). Mucin production is found in histologic analysis in up to 75% of all urachal adenocarcinomas. In addition, as with some other mucinous adenocarcinomas of the abdominal organs, calcifications that are depicted by CT occur in 50%–70% of cases. These may be punctate, stippled, or curvilinear and peripheral. Even though the signs and symptoms of urachal carcinoma are nonspecific, the most common sign is hematuria, which occurs in 71% of patients. Less



common findings are suprapubic masses, abdominal pain, irritative voiding symptoms, and the discharge of blood, pus, or mucus from the umbilicus (8). A CT feature of urachal carcinoma is a midline or paramedian mass anterosuperior to the dome of the bladder, which may be solid, cystic, or a combination of the two. Low-attenuation components are seen in 60% of cases, reflecting the mucin content. Calcifications in a midline supravescical mass are considered nearly diagnostic for urachal carcinoma (9, 10).

Although abscesses in urachal actinomycosis and mucin in urachal carcinoma are pathologically different, it may be difficult to distinguish them on CT due to similar manifestations such as low attenuating foci within a midline or paramedian lower abdominal solid or as cystic masses just beneath the abdominal wall. Although calcifications within the mass are considered pathognomonic for urachal carcinoma, it may be hard to differentiate urachal carcinoma from urachal actinomycosis if there is no calcification within the mass. Our two patients with urachal actinomycosis manifested densely enhancing infiltrative masses with internal necrotic foci on CT, similar to actinomycosis involving other sites, and calcification was not found within the masses. These characteristic CT findings of urachal actinomycosis in typical locations can help differentiate it from malignant urachal neoplasms and may help to avoid unnecessary surgery.

In conclusion, radiologists should be aware of the CT findings suggesting urachal actinomycosis. Whenever a CT image shows a densely enhanced infiltrative solid

mass with internal, low attenuation necrotic foci lacking calcification in the midline of the lower abdomen and along the course of the urachal remnant, urachal actinomycosis should be included in the differential diagnosis to avoid unnecessary surgery.

## References

1. Hsiao HL, Shen JT, Yeh HC, Wu WJ, Wang CJ, Huang CH. Intra- and extra-abdominal actinomycosis mimicking urachal tumor in an intrauterine device carrier: a case report. *Kaohsiung J Med Sci* 2008;24:35-40
2. Yeung Y, Cheung MC, Chan GSW, Cheung ANY, Tam PC. Primary actinomycosis mimicking urachal carcinoma. *Urology* 2001;58:462
3. Ha HK, Lee HJ, Kim H, Ro HJ, Park YH, Cha SJ, et al. Abdominal actinomycosis: CT findings in 10 patients. *AJR Am J Roentgenol* 1993;161:791-794
4. Lely RJ, van Es HW. Case 85: pelvic actinomycosis in association with an intrauterine device. *Radiology* 2005;236:492-494
5. O'Connor KF, Bagg MN, Croley MR, Schabel SI. Pelvic actinomycosis associated with intrauterine devices. *Radiology* 1989;170:559-560
6. Lee IJ, Ha HK, Park CM, Kim JK, Kim JH, Kim TK, et al. Abdominopelvic actinomycosis involving the gastrointestinal tract: CT features. *Radiology* 2001;220:76-80
7. Lee KR, Ko YS, Yu JW, Yoon CY, Kim CH, Yoon DK. Primary vesical actinomycosis: a case diagnosed by multiple transabdominal needle biopsies. *J Korean Med Sci* 2002;17:121-124
8. Brick SH, Friedman AC, Pollack HM, Fishman EK, Radecki PD, Siegelbaum MH, et al. Urachal carcinoma: CT findings. *Radiology* 1988;169:377-381
9. Yu JS, Kim KW, Lee HJ, Lee YJ, Yoon CS, Kim MJ. Urachal remnant diseases: spectrum of CT and US findings. *Radiographics* 2001;21:451-461
10. Koster IM, Cleyndert P, Giard RW. Best cases from the AFIP: urachal carcinoma. *Radiographics* 2009;29:939-942

대한영상의학회지 2009; 61 : 335-339

## 요막관 방선균증의 전산화 단층촬영 소견: 증례 보고<sup>1</sup>

<sup>1</sup>차의과대학교 분당차병원 영상의학과

<sup>2</sup>차의과대학교 분당차병원 병리과<sup>2</sup>

정진영 · 김희진 · 윤상욱 · 김경아 · 김만득 · 허진형<sup>2</sup>

요막관 방선균증은 매우 드물어 요막관이나 복벽에 생긴 악성종양이나 다른 감염 질환으로 오인될 수 있다. 요막관 방선균증의 임상증상이 비특이적이어서 수술 후에 조직학적으로 진단되는 경우가 대부분이며 요막관 방선균증의 영상소견에 대해서도 거의 보고된 바가 없다. 이에 저자들은 수술로 진단된 2예의 요막관 방선균증의 전산화단층촬영 소견에 대해 보고하고자 한다.