

Importance of Regular Follow-Up Examination during Active Surveillance: a Case of Anaplastic Transformation of Papillary Thyroid Microcarcinoma

Jin Seo Kim, Han Ju Moon, Jung Suk Han and Min Joo Kim

Department of Internal Medicine, Korea Cancer Center Hospital, Seoul, Korea

Because papillary thyroid carcinoma (PTC) is indolent and has an excellent prognosis, active surveillance, without immediate surgery, can be considered for small PTC. However, rarely, PTC can transform to anaplastic thyroid carcinoma (ATC), over a period of 5-20 years. We report 73-year-old man with rapid anaplastic transformation of a PTC. He was diagnosed with colorectal cancer, and a 1-cm-sized thyroid nodule was found incidentally and confirmed as PTC on fine-needle aspiration. He underwent transanal excision and chemotherapy for colorectal cancer. However, he was not concerned about the PTC, and no follow-up examination was performed. After 37 months, he suddenly noticed an enlarging neck mass, which was diagnosed as an ATC. Despite total thyroidectomy, locally advanced recurrence with lung metastasis developed, and he eventually died. Although PTC is indolent and progresses slowly in elderly people, it can transform to ATC. Therefore, during active surveillance in the elderly, follow-up examinations should be performed regularly.

Key Words: Anaplastic thyroid carcinoma, Papillary thyroid carcinoma, Thyroid neoplasm

Introduction

Papillary thyroid carcinoma (PTC) is the most common thyroid cancer and accounts for 95% of all thyroid cancers in Korea. PTC has a favorable prognosis, with a 10-year survival rate of more than 90%.¹⁾ Papillary thyroid microcarcinoma (PTMC), defined as a tumor of 1 cm or less in size, has a better outcome. Therefore, some investigators insist on active surveillance without immediate surgery for PTMC. Observational studies for PTMC showed no distant metastasis or cancer-specific death,²⁻⁴⁾ supporting active surveillance management. However, tumor enlargement

and clinically apparent lymph node (LN) metastasis developed in 8% and 3.8% of patients without surgery, respectively, after 10 years of observation.⁴⁾ Moreover, LN metastasis in PTMC has been reported to range from 24% to 64% on the surgical pathology, and more than half of them are clinically unapparent preoperatively.⁵⁻⁸⁾ Therefore, active surveillance implies a lack of action, other than regular follow-up examination, in order to detect any significant progression.

On the other hand, anaplastic thyroid carcinoma (ATC) accounts for only 1-2% of all thyroid cancers.⁹⁾ ATC is very aggressive and shows a poor prognosis, with a 5-year survival rate of 1-7%,^{10,11)} in contrast to differentiated thyroid cancer (DTC). Anaplastic

Received May 12, 2016 / Revised July 1, 2016 / Accepted July 14, 2016

Correspondence: Min Joo Kim, MD, PhD, Department of Internal Medicine, Korea Cancer Center Hospital, 75 Nowon-ro, Nowon-gu, Seoul 01812, Korea

Tel: 82-2-970-2151, Fax: 82-2-970-2438, E-mail: chorong24@gmail.com

Copyright © 2016, the Korean Thyroid Association. All rights reserved.

© This is an open-access article distributed under the terms of the Creative Commons Attribution Non-Commercial License (<http://creativecommons.org/licenses/by-nc/4.0/>), which permits unrestricted non-commercial use, distribution, and reproduction in any medium, provided the original work is properly cited.

transformation of DTC is a well-known process and seems to account for a large proportion of ATC cases. The coexistence of ATC and DTC supports the hypothesis that ATC arises from pre-existing DTCs.¹⁰⁾ During surgery for ATC, 14–90% of ATC cases have been found to coexist with DTC.¹²⁾ Conversely, ATC has been detected incidentally on pathological examination after surgery for DTC.^{13–15)} Several mutations such as *BRAF* and *RAS*, that occur in DTC, have also been reported in ATC.¹⁶⁾

We here report a rare case of rapid anaplastic transformation of PTMC 3 years after the initial diagnosis. This case suggests that regular follow-up examination is important, even in elderly people with PTMC, during active surveillance.

Case Report

A 73-year-old man presented with a neck mass. He had been diagnosed with colorectal cancer 37 months earlier at another hospital. On preoperative positron emission tomography-computed tomography (PET-CT), a hypermetabolic lesion was incidentally found in the thyroid gland (Fig. 1A). Neck ultra-

sonography (US) revealed a 1.0-cm rim-calcified nodule in the right thyroid gland and a 0.8-cm calcified nodule in the left thyroid gland (Fig. 1B). The results of the US-guided core-needle biopsy revealed PTC in the right thyroid gland (Fig. 1C). Because colorectal cancer has priority over thyroid cancer and the patient was elderly, it was decided to observe the PTC without performing surgery at the time. After neoadjuvant concurrent chemo-radiotherapy with capecitabine, the patient underwent transanal excision, followed by adjuvant chemotherapy with a combination of 5-fluorouracil and leucovorin. No further evidence of colorectal cancer was evident thereafter.

Unfortunately, the patient was not concerned about his thyroid cancer at the time and underwent no follow-up examinations. After 37 months, he eventually visited our hospital because of an enlarging neck mass. During neck US, it was found that the right thyroid nodule had increased from 1.0 cm to 4.8 cm (Fig. 2A). An ATC was suspected based on the results of the fine-needle aspiration cytology. A hypermetabolic mass in the right thyroid gland was observed on PET-CT (Fig. 2B). Total thyroidectomy with central LN dissection was performed. The surgical specimen

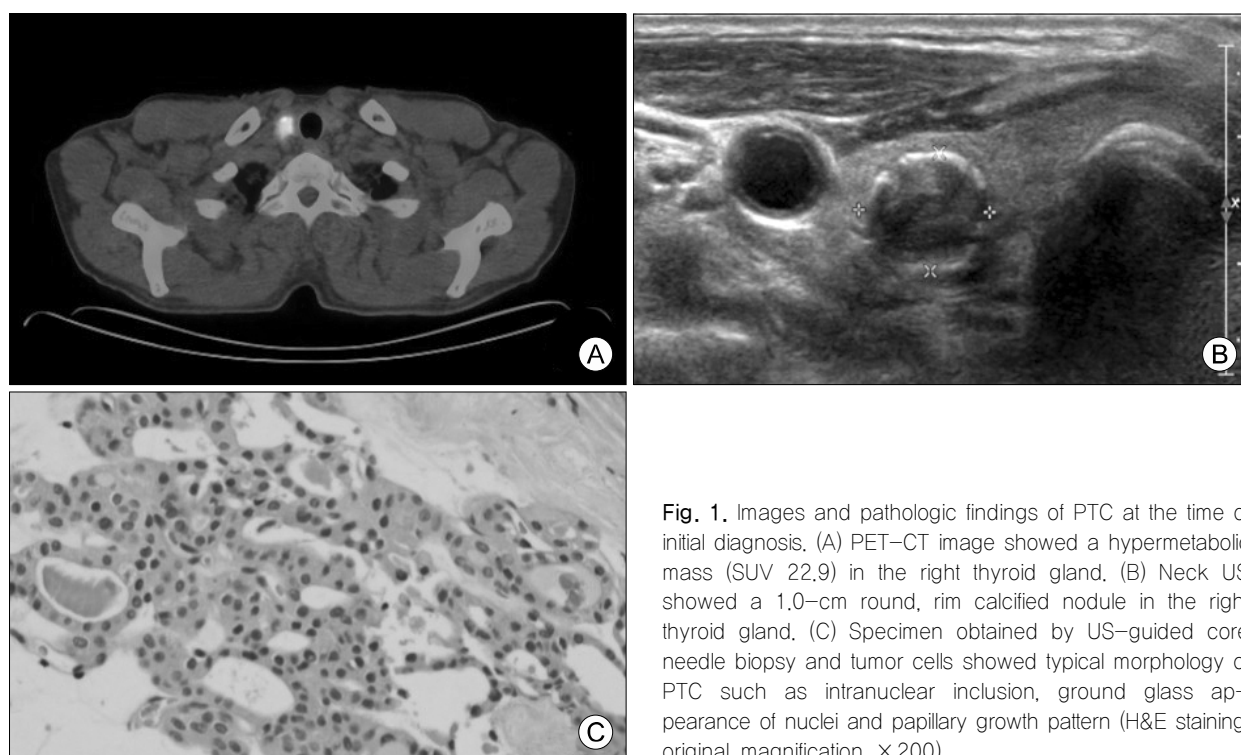


Fig. 1. Images and pathologic findings of PTC at the time of initial diagnosis. (A) PET-CT image showed a hypermetabolic mass (SUV 22.9) in the right thyroid gland. (B) Neck US showed a 1.0-cm round, rim calcified nodule in the right thyroid gland. (C) Specimen obtained by US-guided core needle biopsy and tumor cells showed typical morphology of PTC such as intranuclear inclusion, ground glass appearance of nuclei and papillary growth pattern (H&E staining, original magnification $\times 200$).

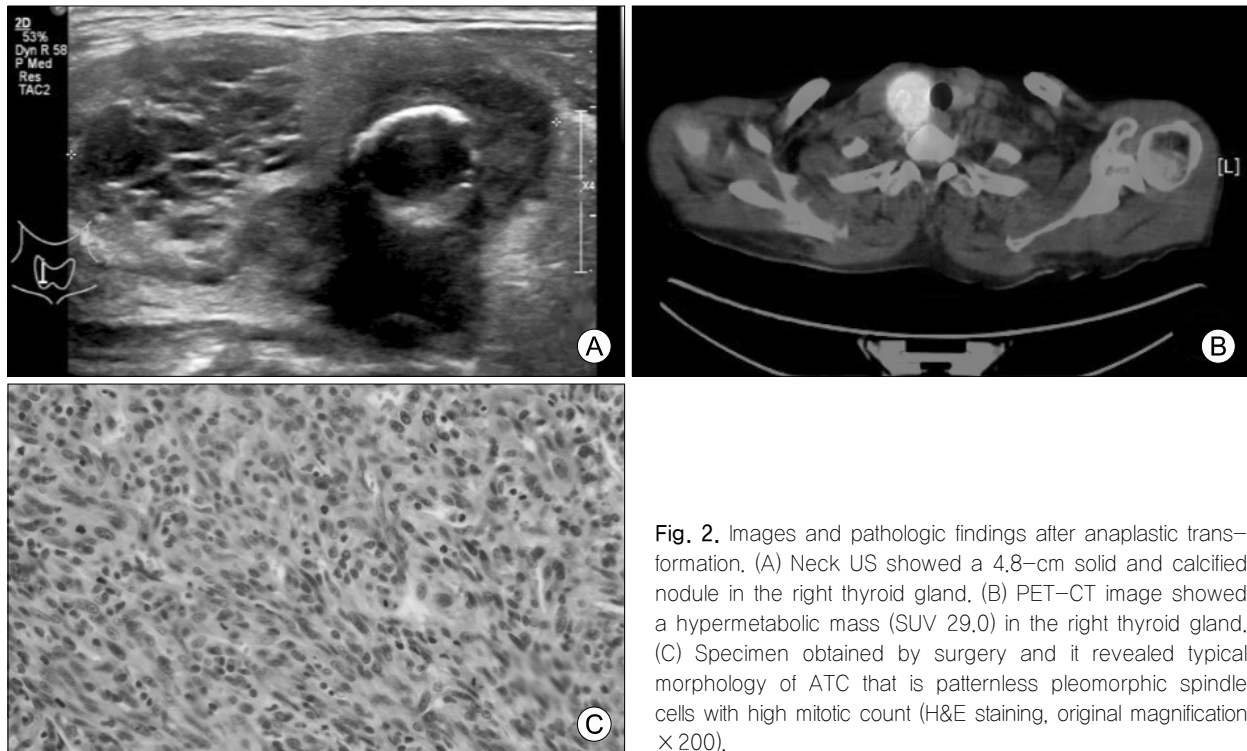


Fig. 2. Images and pathologic findings after anaplastic transformation. (A) Neck US showed a 4.8-cm solid and calcified nodule in the right thyroid gland. (B) PET-CT image showed a hypermetabolic mass (SUV 29.0) in the right thyroid gland. (C) Specimen obtained by surgery and it revealed typical morphology of ATC that is patternless pleomorphic spindle cells with high mitotic count (H&E staining, original magnification $\times 200$).

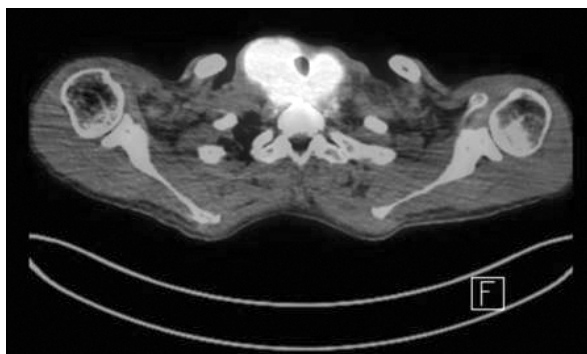


Fig. 3. PET-CT scan 4 months after total thyroidectomy. PET-CT image showed a markedly increased hypermetabolic mass (SUV 43.9) in the neck.

showed the presence of a 5.1×3.0 cm ATC with extrathyroidal extension in the right thyroid gland (Fig. 2C) and a 1.1×1.0 cm PTC in the left thyroid gland; no LN metastasis was observed. After surgery, there was no voice defect. Radiation therapy was recommended, but the patient refused.

Four months after surgery, his voice changed and right vocal cord palsy was observed on laryngoscopy. Locally advanced recurrence and lung metastasis were found on PET-CT (Fig. 3). To avoid airway obstruction, the patient underwent tracheostomy, followed

by radiation therapy (30 Gy). Thereafter, chemotherapy (dabrafenib and trametinib) was administrated, but it had to be stopped because of hyponatremia. Despite these treatments, the patient died because of airway obstruction 7 months after the diagnosis of ATC.

Discussion

The incidence of PTC has increased, probably owing to the increased early detection of PTMC on neck US and US-guided fine-needle aspiration.^{17,18)} Because PTMC is indolent and has an excellent prognosis, active surveillance without immediate surgery can be one of management approaches. However, patients should be carefully selected for active surveillance and followed-up regularly, because some PTMCs can increase in size and metastasize to LNs.²⁻⁴⁾ In previous observational studies, subjects with unfavorable features were excluded, such as those in whom the tumor was adjacent to the trachea or recurrent laryngeal nerve and those with the presence of clinically apparent LN metastasis.^{3,4)} Therefore, the results from these observational studies cannot be applied to all patients with PTMC. In addition, 7–16% of subjects

underwent surgery after observation in such studies, due to tumor enlargement, LN metastasis, or a change of mind in the patient.^{2,4)} This may be the reason for the absence of distant metastasis or cancer-specific death in the observational studies, although 2.8% of patients died of thyroid cancer and small PTCs of 2.0 cm or less accounted for 12% of cancer-specific deaths.¹⁾ Therefore, regular examination and surgery, if the PTMC progresses significantly, is important during active surveillance.

Anaplastic transformation usually arises in long-standing DTCs, and the time interval between the diagnosis of DTC and anaplastic transformation has been reported to range from 5 to 20 years.^{11,19)} However, in this case, anaplastic transformation was noticed at only 37 months after the initial diagnosis of PTMC. This is markedly faster than that reported in previous studies. It is possible that anaplastic foci existed at the time of the initial PTC diagnosis. The proportion of DTC with anaplastic foci, as compared to that of conventional ATC, has been increasing.^{13,15)} Anaplastic foci can also be detected in PTMC. The early detection and surgery of DTC owing to the frequent use of neck US may have increased DTC with anaplastic foci.

PTMC in the elderly, which was found to be less progressive in the observational study, is considered the best candidate for observation.⁴⁾ However, ATC manifests in the 6th to 7th decade of life,^{20,21)} which is the age during which anaplastic transformation usually occurs. Our patient was also 73 years old. This case highlights that it can be dangerous to neglect DTC in the elderly. After anaplastic transformation, thyroid cancer follows the same disease pattern as classical ATC, as it also did in this case.^{10,11,21)}

The mean survival time for ATC is approximately 5–6 months; this patient died 7 months after initial diagnosis. A young age and small tumor size have been associated with lower mortality for ATC.²²⁾ DTC with anaplastic foci has a better outcome than does conventional ATC.^{13,14,23)} ATC does not respond well to various treatment modalities. For resectable disease, surgery (total thyroidectomy and therapeutic LN dissection) and adjuvant radiation therapy should be

considered.²⁴⁾ Survival is significantly higher in patients with resectable tumors than in those with unresectable tumors. In patients with unresectable ATC, radiation therapy can be considered, and it can improve survival.

In conclusion, although PTC is indolent and generally has a good prognosis, it can progress and transform to ATC. Anaplastic transformation is rare, but fatal. Therefore, when active surveillance is opted for in elderly people, follow-up examinations should be performed regularly.

Acknowledgments

This study was supported by a grant of the RTR (Radiological Translational Research program), Korea Institute of Radiological & Medical Sciences (KIRMAS), funded by ministry of Science, ICT and Future Planning, Republic of Korea (1711031800/50472–2016).

References

- 1) Nilubol N, Kebebew E. *Should small papillary thyroid cancer be observed? A population-based study.* *Cancer* 2015;121(7):1017-24.
- 2) Sugitani I, Toda K, Yamada K, Yamamoto N, Ikenaga M, Fujimoto Y. *Three distinctly different kinds of papillary thyroid microcarcinoma should be recognized: our treatment strategies and outcomes.* *World J Surg* 2010;34(6):1222-31.
- 3) Ito Y, Miyauchi A, Inoue H, Fukushima M, Kihara M, Higashiyama T, et al. *An observational trial for papillary thyroid microcarcinoma in Japanese patients.* *World J Surg* 2010;34(1):28-35.
- 4) Ito Y, Miyauchi A, Kihara M, Higashiyama T, Kobayashi K, Miya A. *Patient age is significantly related to the progression of papillary microcarcinoma of the thyroid under observation.* *Thyroid* 2014;24(1):27-34.
- 5) Wada N, Duh QY, Sugino K, Iwasaki H, Kameyama K, Mimura T, et al. *Lymph node metastasis from 259 papillary thyroid microcarcinomas: frequency, pattern of occurrence and recurrence, and optimal strategy for neck dissection.* *Ann Surg* 2003;237(3):399-407.
- 6) Chow SM, Law SC, Chan JK, Au SK, Yau S, Lau WH. *Papillary microcarcinoma of the thyroid-prognostic significance of lymph node metastasis and multifocality.* *Cancer* 2003;98(1):31-40.
- 7) Hay ID, Hutchinson ME, Gonzalez-Losada T, McIver B, Reinalda ME, Grant CS, et al. *Papillary thyroid microcarcinoma: a study of 900 cases observed in a 60-year period.*

- Surgery* 2008;144(6):980-7; discussion 7-8.
- 8) Cho SY, Lee TH, Ku YH, Kim HI, Lee GH, Kim MJ. Central lymph node metastasis in papillary thyroid microcarcinoma can be stratified according to the number, the size of metastatic foci, and the presence of desmoplasia. *Surgery* 2015;157(1):111-8.
- 9) Oh CM, Jung KW, Won YJ, Shin A, Kong HJ, Lee JS. Age-period-cohort analysis of thyroid cancer incidence in Korea. *Cancer Res Treat* 2015;47(3):362-9.
- 10) Wiseman SM, Loree TR, Rigual NR, Hicks WL Jr, Douglas WG, Anderson GR, et al. Anaplastic transformation of thyroid cancer: review of clinical, pathologic, and molecular evidence provides new insights into disease biology and future therapy. *Head Neck* 2003;25(8):662-70.
- 11) McIver B, Hay ID, Giuffrida DF, Dvorak CE, Grant CS, Thompson GB, et al. Anaplastic thyroid carcinoma: a 50-year experience at a single institution. *Surgery* 2001;130(6):1028-34.
- 12) Venkatesh YS, Ordonez NG, Schultz PN, Hickey RC, Goepfert H, Samaan NA. Anaplastic carcinoma of the thyroid. A clinicopathologic study of 121 cases. *Cancer* 1990;66(2):321-30.
- 13) Lee DY, Won JK, Lee SH, Park do J, Jung KC, Sung MW, et al. Changes of clinicopathologic characteristics and survival outcomes of anaplastic and poorly differentiated thyroid carcinoma. *Thyroid* 2016;26(3):404-13.
- 14) Yoshida A, Sugino K, Sugitani I, Miyauchi A. Anaplastic thyroid carcinomas incidentally found on postoperative pathological examination. *World J Surg* 2014;38(9):2311-6.
- 15) Han JM, Bae Kim W, Kim TY, Ryu JS, Gong G, Hong SJ, et al. Time trend in tumour size and characteristics of anaplastic thyroid carcinoma. *Clin Endocrinol (Oxf)* 2012;77(3):459-64.
- 16) Smallridge RC, Marlow LA, Copland JA. Anaplastic thyroid cancer: molecular pathogenesis and emerging therapies. *Endocr Relat Cancer* 2009;16(1):17-44.
- 17) Ahn HS, Kim HJ, Welch HG. Korea's thyroid-cancer "epidemic"--screening and overdiagnosis. *N Engl J Med* 2014;371(19):1765-7.
- 18) Davies L, Welch HG. Increasing incidence of thyroid cancer in the United States, 1973-2002. *JAMA* 2006;295(18):2164-7.
- 19) Kaushal S, Sharma MC, Mathur SR, Rastogi S, Bal CS, Chumber S. Anaplastic transformation of metastatic papillary thyroid carcinoma at shoulder mimicking soft tissue sarcoma. *Indian J Pathol Microbiol* 2011;54(4):796-9.
- 20) Aschebrook-Kilfoy B, Ward MH, Sabra MM, Devesa SS. Thyroid cancer incidence patterns in the United States by histologic type, 1992-2006. *Thyroid* 2011;21(2):125-34.
- 21) Are C, Shaha AR. Anaplastic thyroid carcinoma: biology, pathogenesis, prognostic factors, and treatment approaches. *Ann Surg Oncol* 2006;13(4):453-64.
- 22) Kim TY, Kim KW, Jung TS, Kim JM, Kim SW, Chung KW, et al. Prognostic factors for Korean patients with anaplastic thyroid carcinoma. *Head Neck* 2007;29(8):765-72.
- 23) Choi JY, Hwang BH, Jung KC, Min HS, Koo do H, Youn YK, et al. Clinical significance of microscopic anaplastic focus in papillary thyroid carcinoma. *Surgery* 2013;154(1):106-10.
- 24) Smallridge RC, Ain KB, Asa SL, Bible KC, Brierley JD, Burman KD, et al. American Thyroid Association guidelines for management of patients with anaplastic thyroid cancer. *Thyroid* 2012;22(11):1104-39.