



Arthroscopic Treatment of Septic Arthritis of the Hip in a Child: A Case Report

Young-Bong Ko, MD, Hyoung-Seok Jung, MD, Ji-Hoon Baek, MD, Han-Jun Lee, MD, Yong-Chan Ha, MD

Department of Orthopaedic Surgery, College of Medicine, Chung-Ang University, Seoul, Korea

Recommended treatment options for acute septic arthritis in children include repeated aspiration, open arthrotomy, and arthroscopic drainage. However, reports of arthroscopic treatment of septic arthritis of the hip in a child are rare. We experienced a case of arthroscopic management of acute septic arthritis of the right hip joint in a three-year-old child using a 30°, 2.7 mm arthroscope for the ankle joint through manual traction without use of a traction table. The patient had complete range of motion in the right hip joint two weeks after surgery and recurrent infection was not observed at the final follow-up two years postoperatively.

Key Words: Septic arthritis, Arthroscopic management, Child

Introduction

Septic arthritis of the hip is more frequent in the pediatric population than the adult population. Early diagnosis and prompt intervention to preserve normal structure and recover full joint function is mandatory in children with acute septic arthritis of the hip since the result can be an unfavorable outcome and life-long disability^{1,2}. The surgical options include repeated aspirations, open arthrotomy, and arthroscopic drainage^{3,4}. Recently, several reports described successful outcomes

in children following arthroscopic management of septic hips⁵⁻⁷. The immature anatomical features and smaller hip joints of young children make arthroscopic procedure technically challenging⁸, and require specialized instruments, such as smaller arthroscopes and a fracture table for traction. However, little information is available concerning arthroscopic surgical techniques for children. We report the case of the arthroscopic management of acute septic arthritis of the hip joint in 3-year-old child using a 30°, 2.7 mm arthroscope for the ankle joint on the general table. Her parents were informed that data concerning her case would be submitted for publication.

Case Report

A 3-year-old female child was complaint of fever, limping gait, and right groin pain in the emergency room. As a past medical history, she had an upper respiratory infection, which had completely resolved two weeks ago. There were no abnormal symptoms in patient until the day before her presentation to the emergency room.

In the emergency room, the body temperature was checked 38°C with normal pulse rate and blood

Submitted: February 14, 2013 **1st revision:** March 29, 2013

2nd revision: April 30, 2013 **3rd revision:** May 14, 2013

Final acceptance: May 14, 2013

Address reprint request to

Ji-Hoon Baek, MD

Department of Orthopaedic Surgery, College of Medicine, Chung-Ang University, 224-1 Heukseok-dong, Dongjak-gu, Seoul 156-755, Korea

TEL: +82-2-6299-1591 **FAX:** +82-2-822-1710

E-mail: jihoon011@naver.com

This is an Open Access article distributed under the terms of the Creative Commons Attribution Non-Commercial License (<http://creativecommons.org/licenses/by-nc/3.0>) which permits unrestricted non-commercial use, distribution, and reproduction in any medium, provided the original work is properly cited.

pressure. On physical examination, right hip joint motion was limited by pain and warmth of the anterior aspect of the right groin was detected. However, there was no tenderness or redness on the right hip joint. A simple radiograph of the pelvis did not reveal destructive joint lesions, except for a mild soft tissue swelling of the hip joint. An magnetic resonance imaging (MRI) scan could not perform due to patient's noncooperation. Hematological examination revealed a leukocyte count (WBC) of 15,440/ml (normal range, 3,000-9,000/ml), a C-reactive protein (CRP) of 42 ng/ml (normal range, 0-5 ng/ml) and a erythrocyte sedimentation rate (ESR) of 60 mm/hr (normal range, 0-20 mm/hr). Analysis of fluid aspirated from the affected joint revealed a leukocyte count of 54,000/ml with 99% neutrophils, confirming acute septic arthritis of the hip joint^{4,9)}.

joint^{4,9)}.

The patient was placed in a supine position on a general table. Under general anesthesia, two arthroscopic portals (anterolateral and ancillary portals) of the hip were used (Fig. 1A). We initially approached the peripheral compartment via the anterolateral portal as a viewing portal using a 30°, 2.7-mm arthroscope for the ankle joint, which was made 0.5 cm distal and 1 cm anterior to the tip of the greater trochanter. The ancillary portal as a walking portal was placed 2.5 cm distal portion to the anterolateral portal (Fig. 1B). After setting up the two portals, the arthroscope, various instruments, and the motorized shaver were switched between portals. Synovectomy at the femoral neck junction was performed and the central compartment was approached with manual traction. After pelvis was fixed by first

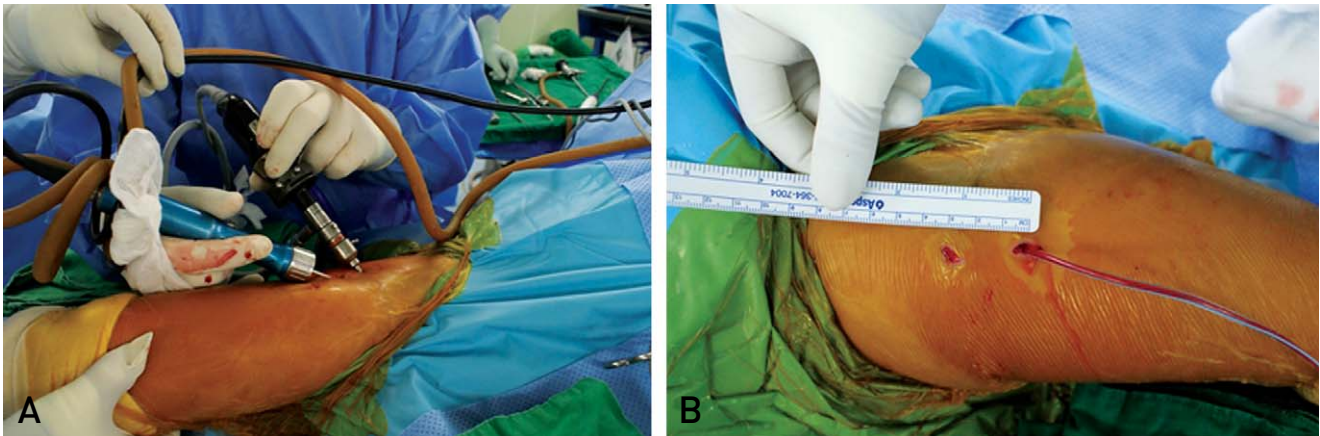


Fig. 1. (A) Arthroscopic appearance using two portals. (B) Location of the ancillary portal placed 2.5 cm distal to the anterolateral portal.

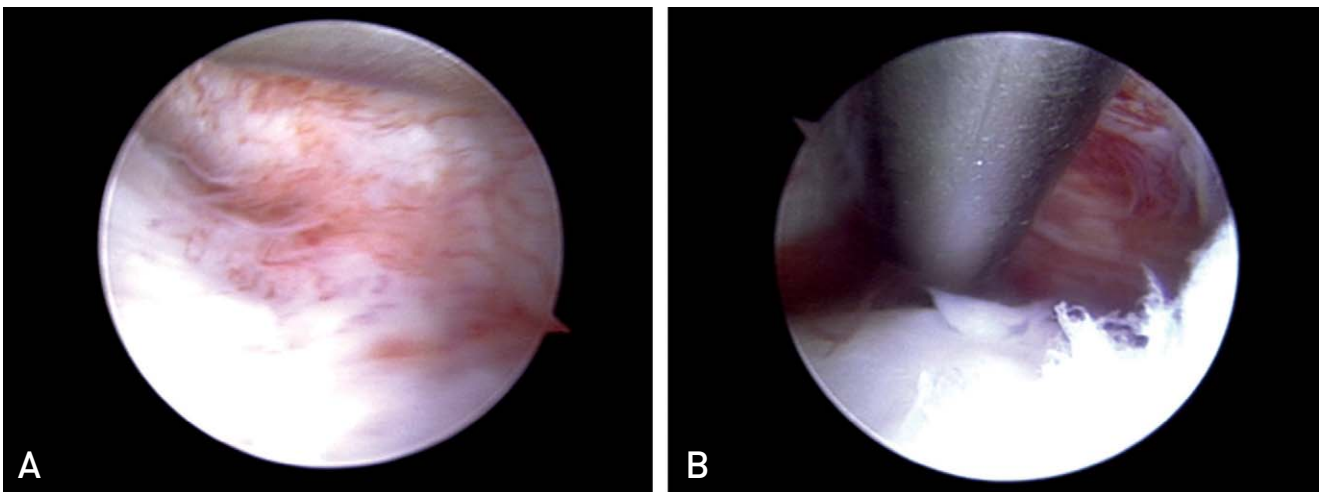


Fig. 2. (A) Arthroscopic view shows a synovitis lesion of around femoral neck junction. (B) The hip joint was debrided by the motorized shaver.

assistant, the joint space was distracted about 10 mm by second assistant's manual traction and was maintained during surgery in the central compartment. The hip joint was lavaged by the arthroscope with 10 L of normal saline solution and debrided by the motorized shaver (Fig. 2). Before the portals were closed, a suction drain tube was placed in the peripheral compartment to avoid hampering the drain tube between the femoral head and the acetabulum.

After the arthroscopic drainage, intravenous first-generation cephalosporin (cephazolin) was administered empirically. The causative microorganism was not identified in the hip joint culture and intravenous antibiotic was maintained 3 weeks. Tolerable motion of hip joint and weight bearing on the foot was allowed immediately after surgery. The suction drain was removed at 2 days post-operatively. Elevated WBC, CRP and ESR count were normalized postoperative 12 days. The range of motion of right hip joint was recovered at 2 weeks after surgery. There was no recurrent signs and radiological changes at the final follow-up at 2 years postoperatively.

Discussion

Hip arthroscopic treatment is considered as an attractive alternative to open arthrotomy in septic arthritis in the pediatric population¹⁰⁾. The surgical technique of hip arthroscopy in children is similar to that performed in adults, but multifarious anatomical and pathoanatomical characteristics, such as a smaller joint space, larger neck-shaft angle, femoral anteversion and the presence of the physis, make hip arthroscopy in children technically challenging⁸⁾. There have been several reports of successful outcomes in pediatric patients following arthroscopic management of septic hips^{5,6)}, however little information is available concerning surgical intervention in children and there was no appropriate arthroscopic equipments. This case report shows usefulness of arthroscopic treatment of early stage septic hip arthritis in child and ankle arthroscope could be possible appropriate instrument in these age groups.

Advanced instrumentation is required to overcome the arthroscopic limitations posed by a confined hip joint in pediatric patients. However, previous reports described arthroscopic management of septic hip using a constant size scope and same surgical technique, regardless of

pediatric age^{5,6)}. This case report indicates the success of arthroscopic treatment using a 2.7 mm arthroscope for the ankle joint without the specialized instruments on the general table for a 3-year-old child.

In the present case, only two portals (anterolateral and ancillary portal) and an arthroscope for the ankle joint were used on the general table. Using the ancillary portal as working portal, synovectomy in the peripheral compartment, such as around the femoral neck junction, was performed and the central compartment was approached with manual traction. Especially, care should be taken that you need to allow sufficient joint space to prevent physis damage when you access to the central compartment. Without using the anterior and posterolateral portals, we were able to sufficiently treat the septic arthritis; this approach could minimize nerve and vessel injury in a child patient. However, in performing an arthroscopy in the smaller hip joint of a child, the surgeon should be aware of the age-related diversity of joint anatomy. Furthermore, a substantial learning curve period should be anticipated for this patient population.

Conclusion

We successfully treated a case of acute septic arthritis in the hip joint of a 3-year-old child using a 2.7 mm arthroscope for the ankle joint through manual traction without a traction table. This procedure might be more helpful in minimizing scarring and damage of hip anatomy, and facilitating earlier rehabilitation.

REFERENCES

1. Sucato DJ, Schwend RM, Gillespie R. *Septic arthritis of the hip in children. J Am Acad Orthop Surg.* 1997;5:249-60.
2. Shaw BA, Kasser JR. *Acute septic arthritis in infancy and childhood. Clin Orthop Relat Res.* 1990;(257):212-25.
3. Goldenberg DL. *Septic arthritis. Lancet.* 1998;351:197-202.
4. Mathews CJ, Kingsley G, Field M, et al. *Management of septic arthritis: a systematic review. Ann Rheum Dis.* 2007;66:440-5.
5. DeAngelis NA, Busconi BD. *Hip arthroscopy in the pediatric population. Clin Orthop Relat Res.* 2003;(406):60-3.
6. Kim SJ, Choi NH, Ko SH, Linton JA, Park HW. *Arthroscopic treatment of septic arthritis of the hip. Clin Orthop Relat Res.* 2003;(407):211-4.
7. El-Sayed AM. *Treatment of early septic arthritis of the hip*

in children: comparison of results of open arthrotomy versus arthroscopic drainage. *J Child Orthop.* 2008;2: 229-37.

8. Byrd JW. *Operative hip arthroscopy. 2nd ed.* Berlin: Springer; 2011.36-51, 110-7, 204-20.

9. Luhmann SJ, Jones A, Schootman M, Gordon JE, Schoenecker PL, Luhmann JD. *Differentiation between*

septic arthritis and transient synovitis of the hip in children with clinical prediction algorithms. J Bone Joint Surg Am. 2004;86-A:956-62.

10. Jayakumar P, Ramachandran M, Youm T, Achan P. *Arthroscopy of the hip for paediatric and adolescent disorders: current concepts. J Bone Joint Surg Br.* 2012; 94:290-6.

국문초록

소아 화농성 고관절염의 관절경적 치료: 증례보고

고영봉 · 정형석 · 백지훈 · 이한준 · 하용찬
중앙대학교 의과대학 정형외과학교실

소아에서 급성 화농성 고관절염의 치료는 반복적인 관절천자, 개방성 관절 절개술, 관절경적 배액술 등이 소개되고 있다. 그러나, 소아에서 발생한 화농성 고관절염의 관절경을 이용한 치료에 대한 보고는 드물다. 저자들은 3세 소아에서 고관절 급성 화농성 관절염에 대하여 견인장치 없이 도수견인 통해 30°, 2.7-mm 족근관절용 관절경을 이용하여 치료하였으며, 수술 후 2주에 완전한 고관절 운동범위를 회복하였고, 수술 후 2년 추시 상 재발 소견은 관찰되지 않았다.

색인단어: 화농성 관절염, 관절경적 치료, 소아