

캡슐 내시경의 임상이용

Clinical Application of Capsule Endoscope

574 126 - 1

Hoon Jai Chun, M.D.

Department of Gastroenterology

Korea University College of Medicine, Anam Hospital

E-mail : kumcge@chollian.net

Abstract

Wireless capsule endoscopy is currently the outstanding technical innovation in diagnostic gastrointestinal endoscopy. Especially for small bowel diseases this new technique offers several potential advantages over traditional diagnostic tools. The Given Diagnostic Imaging System (Given Imaging Ltd, Norcross, GA) consists of 3 components : the M2A capsule, an external receiving antenna with an attached portable hard drive, and a personal computer workstation for review and interpretation of images. The M2A capsule is a single - use device measuring 11 × 26 mm and weighing 3.7 g. It is made of a biocompatible plastic and contains a complimentary metal oxide silicon chip camera, lens, light source, battery, and radio telemetry transmitter. Images are transmitted at 2 per second to an antenna array worn on the abdomen and stored on a Walkman - sized data recorder. The Given system was approved by the Food and Drug Administration in August 2001. The method has chiefly been used in patients with obscure gastrointestinal bleeding, and in some cases has allowed additional diagnoses to be made in comparison with push enteroscopy, with a positive influence on patient management. Contraindications to performance of capsule endoscopy include known or suspected GI obstruction, strictures or fistula, and presence of a cardiac pacemaker, defibrillator, or other implanted electromedical device. The M2A capsule is probably just the first in a long line of wireless endoscopic devices. There are already prototypes of self - propelled devices. Soon to come will real - time imaging, devices to image the proximal GI tract and colon, and devices that can take biopsies or provide therapy.

Keywords : Capsule endoscope; Small bowel disease

가

가

가

(Cap-
sule endoscope)

(Fantastic

voyage)

(Wireless end-

oscope) 2000

Swain


가

가

11 mm,

26 mm, 3.7 g

가



1.

Scapa

가

가

가

(1~3).

가

, 1994 1

1993

1994 9

Swain

Iddan

1981

Iddan

가

Swain

1996

(electro-optical imaging de-

vice)

1997


Iddan

1998

Iddan

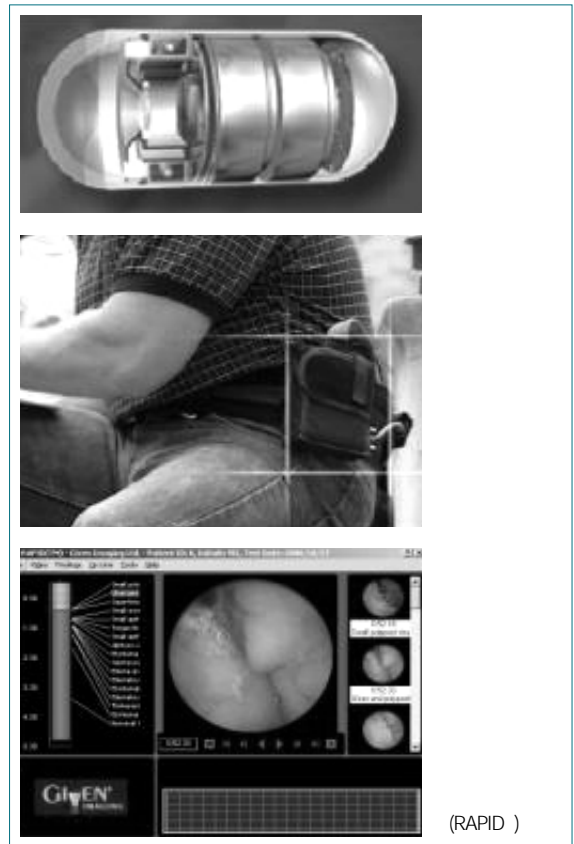
Swain

Elscint



2.

1999 1 . 2000
5 Swain Given
ture . 2001 Na-
가 FDA
CE
(4~10).



3.

M2A (Given Imaging Ltd, Norcross,
GA)
, , 가
(1). 11 mm, 26 mm
가 (optical dome)(1)
(Light Emitting Diode ; LED)(4)
(3) Comple-
mentary Metal - Oxide Silicon(CMOS) (5)
. CMOS

CCD(Charged Coupled Device)

가 .

(6) . Application
Specific Integrated Circuit(ASIC) transmitter가
(8) .
가 140 , 8
30 1 mm 0.1 mm
. 6~8
가 1 2

1 2

 $(2, 3).$

8
8 ~ 9 4 ~ 5

12

가

가

가

8
가

가

가

가 가

4

4

가

8

가

3

가

가

가

1

가

2

가

가

가 , 가

1 2 5 .

가 .

, 1.

30 2 . 가

가 Z -

가 .

2.

가 가

12 .

가 ,

가 .

가 .

가 . Rapid (the software used to review the M2A images)

가 .

가 가

가 (14~17). 3.

가 가

3

Brunner

가

2

가 . Vater

Kerckring 가

가

가

가

가 160 cm

Treitz 40 cm

4.

가 . 가 (push

가 . enteroscopy)

가 2.1~2.5 m

가

가

Sonde Rope - way

가 ,

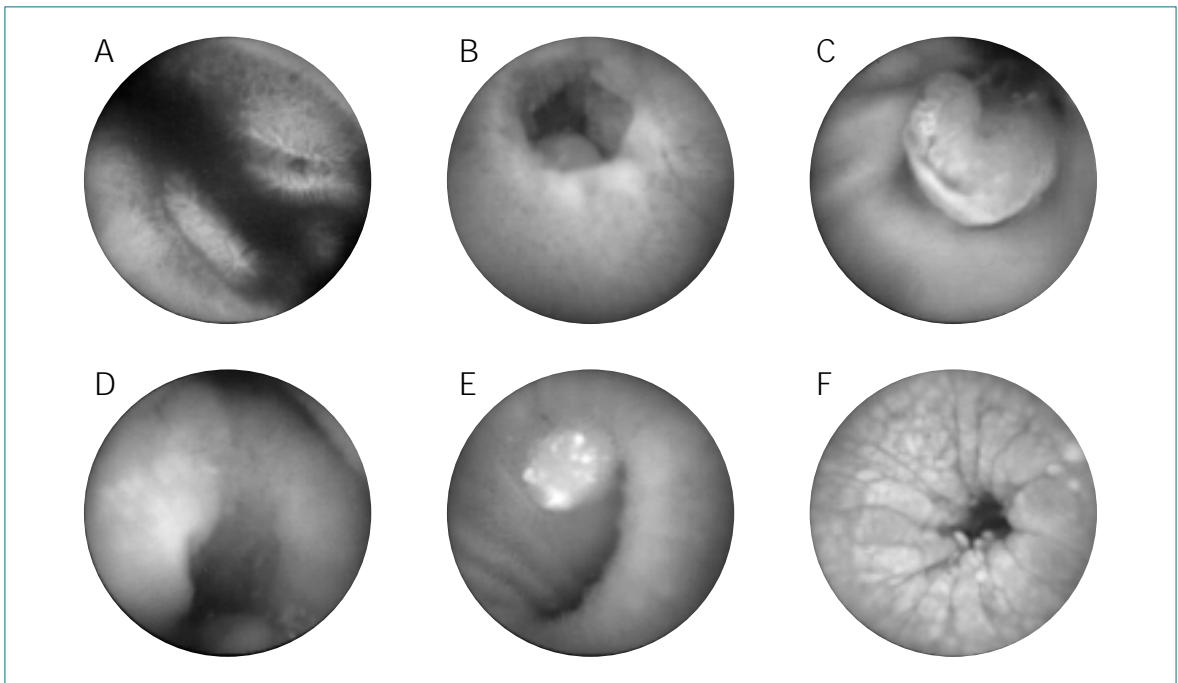
5.

가

가

64%, 92% 가

가 20 가



- A) NSAID induced small bowel ulcer with bleeding. The image shows fresh bloods with ulcers.
 B) A case of small bowel Crohn 's disease. The image shows a chronic ulcer with stricture.
 C) The image shows a irregular surfaced jejunal polyp.
 D) Jejunal GIST with mucosal ulcer and bleeding. The image shows semicircular gray - whitish mucosal elevation with central depression and hyperemia.
 E) The image shows yellowish elevated small bowel xanthoma.
 F) Cronchite - Canada syndrome. The image shows denuded mucosal pattern with sparse villi.

4.

가 421 67% 가 가
 가
 (4).
 (18~28).

가

M2A patency system

(29~35).

Zenker ,

가 가 가 .

14

가 가

6

(36, 37).

가 , ,

가 .

11 mm

가 가 .

, 2

가

가

가

1%

가

1. Fleischer DE. Capsule endoscopy : the voyage is fantastic - will it change what we do? Gastrointest Endosc 2002 ; 56 : 452 - 6

2. Fritscher - Ravens A, Swain CP. The wireless capsule : new light in the darkness. *Dig Dis* 2002 ; 20 : 127 - 33
3. Iddan G, Meron G, Glukhovsky A, Swain P. Wireless capsule endoscopy. *Nature* 2000 ; 405 : 417
4. Appleyard M, Mosse C, Mills T, Swain P. Electrostimulation to move endoscopes in the small bowel. *Endoscopy* 2000 ; 32 : E59
5. Appleyard MN, Gong F, Mills T, Mosse CA, Swain CP. Endoscopy without air insufflation. *Gastrointest Endosc* 2000 ; 51 : A260
6. Lewis BS. The history of enteroscopy. *Gastrointest Endosc Clin North Am* 1999 ; 9 : 1 - 11
7. Meron GD. The development of the swallowable video capsule (M2A). *Gastrointest Endosc* 2000 ; 52 : 817 - 9
8. Mosse CA, Swain CP. Technical advanced and experimental devices for enteroscopy. *Gastrointest Endosc Clin North Am* 1999 ; 9 : 145 - 61
9. Scapa E, Meron G, Glukhovsky A, Gat D, Jacob H, Shreiber R. Wireless capsule colonoscopy. *Gastrointest Endosc* 2001 ; 53 : A111
10. Seidman EG. Wireless capsule video - endoscopy : an odyssey beyond the end of the scope. *J Pediatr Gastroenterol Nutr* 2002 ; 34 : 333 - 4
11. Gong F, Swain P, Mills T. Wireless endoscopy. *Gastrointest Endosco* 2000 ; 51 : 725 - 29
12. Swain CP, Gong F, Mills TN. Wireless transmission of a color television moving image from the stomach using a miniature CCD camera, light source and microwave transmitter. *Gut* 1996 ; 39 : A26
13. Swain P. Wireless capsule endoscopy. *Gut* 2003 ; 52 : IV48 - IV50
14. Appleyard Glukhovsky A, Jacob H. Transit times for the capsule endoscope. *Gastrointest Endosc* 2001 ; 53 : A122
15. Fischer D, Shreiber R, Meron G, Frisch M, Jacob H, Engel A, et al. Localization of the wireless capsule endoscopy in its passage through the GI tract. *Gastrointest Endosc* 2001 ; 53 : A126
16. Seitz U, Bohnacker S, Soehendra N. A simple method to determine the location of the capsule and thus whether prokinetic drugs are needed during video capsule endoscopy. *Endoscopy* 2002 ; 34 : 1027
17. Stiffler HL. Capsule endoscopy : a case study of an 11 - year - old girl. *Gastroenterol Nurs* 2003 ; 26 : 38 - 40
18. Appleyard M, Blukhovsky A, Swain P. Wireless capsule endoscopy for recurrent small - bowel bleeding. *N Engl J Med* 2001 ; 344 : 232 - 3
19. Appleyard M, Fireman Z, Glukhovsky A, Jacob H, Shreiber R, Zaretsk A, et al. A randomized trial comparing wireless capsule endoscopy with push enteroscopy for the detection of small - bowel lesions. *Gastroenterology* 2000 ; 119 : 1431 - 8
20. Costamagna G, Shah SK, Riccioni ME, Foschia F, Mutignani M, Marano P, et al. A prospective trial comparing small bowel radiographs and video capsule endoscopy for suspected small bowel disease. *Gastroenterology* 2002 ; 123 : 999 - 1005
21. Ell C, Remke S, May A, Helou L, Henrich R, Mayer G. The first prospective controlled trial comparing wireless capsule endoscopy with push enteroscopy in chronic gastrointestinal bleeding. *Endoscopy* 2002 ; 34 : 685 - 9
22. Eliakim R, Fischer D, Suissa A, Yassin K, Katz D, Migdal M, et al. Wireless capsule video endoscopy is a superior diagnostic tool in comparison to barium follow - through and computerized tomography in patients with suspected Crohn's disease. *Eur J Gastroenterol Hepatol* 2003 ; 15 : 363 - 7
23. Lewis B, Goldforb N. The advent of capsule endoscopy - a not - so - futuristic approach to obscure gastrointestinal bleeding. *Aliment Pharmacol Ther* 2003 ; 1 : 1085 - 96
24. Lewis BS, Swain P. Capsule endoscopy in the evaluation of patients with suspected small intestinal bleeding : Results of a pilot study. *Gastrointest Endosc* 2002 ; 56 : 349 - 53
25. Scapa E, Jacob H, Lewkowicz S, Migdal M, Gat D, Fireman Z,

- et al. Initial experience of wireless - capsule endoscopy for evaluating occult gastrointestinal bleeding and suspected small bowel pathology. *Am J Gastroenterol.* 2002 ; 97 : 2776 - 9
26. Van Gossum A. Capsule endoscopy in patients with obscure GI bleeding. *Gastrointest Endosc* 2003 ; 57 : 629
27. Waye JD. Small - bowel endoscopy. *Endoscopy* 2003 ; 35 : 15 - 21
28. Zuckerman GR, Prakash C, Askin MP, Lewis BS. AGA technical review on the evaluation and management of occult and obscure gastrointestinal bleeding. *Gastroenterology* 2000 ; 118 : 201 - 21
29. Faigel DO, Fennerty MB. Cutting the cord for capsule endoscopy. *Gastroenterology* 2002 ; 123 : 1385 - 8
30. Fireman Z, Mahajna E, Broide E, Shapiro M, Fich L, Scapa E, et al. Diagnosing small bowel Crohn's disease with wireless capsule endoscopy. *Gut* 2003 ; 52 : 390 - 2
31. Ginsberg GG, Barkun AN, Bosco JJ, Isenberg GA, Nguyen CC, Taitelbaum G, et al. Wireless capsule endoscopy : August 2002. *Gastrointest Endosc* 2002 ; 56 : 621 - 4
32. Gonzalez - Suarez B, Guarner C, Escudero JR, Viver E, Palmer J, Balanzo J. Wireless capsule video endoscopy : a new diagnostic method for aortoduodenal fissure. *Endoscopy* 2002 ; 34 : 938
33. Mascarenhas - Saraiva M, Lopes L, Mascarenhas - Saraiva A. Watermelon stomach seen by wireless - capsule endoscopy. *Endoscopy* 2003 ; 35 : 100
34. Mylonaki M, MacLean D, Fritscher - Ravens A, Swain P. Wireless capsule endoscopic detection of Meckel's diverticulum after nondiagnostic surgery *Endoscopy* 2002 ; 34 : 1018 - 20
35. Nageshwar Reddy D, Sriram PV, Rao GV, Bhaskar Reddy D. Capsule endoscopy appearances of small - bowel tuberculosis. *Endoscopy* 2003 ; 35 : 99
36. Sultan S, Dobozi BM, Palmer P, Treem WR, Agrawal NM. Assisted wireless capsule endoscopy in a six - year - old with abdominal pain and obscure GI bleeding. 2003 DDW. M1725
37. Lewkowicz S, Shreiber R, Jacob H, Gat D, Kraizer Y, Seligson B. Results of the 1st study of the safety, transit time and dynamics of the M2A patency capsule in healthy volunteers. 2003 DDW. 491