

Original Article



Extrafascial hysterectomy after concurrent chemoradiotherapy in locally advanced cervical adenocarcinoma

Jie Yang, Keng Shen, Jinhui Wang, Jiaxin Yang, Dongyan Cao

Department of Obstetrics and Gynecology, Peking Union Medical College Hospital, Peking Union Medical College, Chinese Academy of Medical Science, Beijing, China

OPEN ACCESS

Received: Sep 26, 2015

Revised: Feb 2, 2016

Accepted: Mar 29, 2016

Correspondence to

Keng Shen

Department of Obstetrics and Gynecology,
Peking Union Medical College Hospital, Peking
Union Medical College, Chinese Academy of
Medical Science, No. 1. Shuaifuyuan,
Wangfujing, Dong Cheng District, Beijing
100730, China.
E-mail: shenkeng@vip.sina.com

Copyright © 2016. Asian Society of
Gynecologic Oncology, Korean Society of
Gynecologic Oncology
This is an Open Access article distributed under
the terms of the Creative Commons Attribution
Non-Commercial License ([http://
creativecommons.org/licenses/by-nc/4.0/](http://creativecommons.org/licenses/by-nc/4.0/))
which permits unrestricted non-commercial
use, distribution, and reproduction in any
medium, provided the original work is properly
cited.

ORCID

Jie Yang

<http://orcid.org/0000-0001-7661-2861>

Keng Shen

<http://orcid.org/0000-0003-3276-645X>

Jinhui Wang

<http://orcid.org/0000-0002-4328-984X>

ABSTRACT

Objective: To evaluate whether adjuvant simple hysterectomy after concurrent chemoradiotherapy (CCRT) improves progression-free survival (PFS) compared with current standard care in locally advanced cervical adenocarcinoma (LACAC).

Methods: We reviewed a cohort of 55 patients with LACAC (International Federation of Gynecology and Obstetrics [FIGO] stage IB2, IIA2, IIB, III without distant metastasis) diagnosed and treated with radical CCRT at Peking Union Medical College Hospital between January 2004 and October 2014. We compared 34 patients who underwent adjuvant extrafascial hysterectomy with 21 patients with standard care after CCRT. The primary outcome was PFS. Overall survivals (OS) between the two groups were also compared. Surgery feasibility, operative complications, and pathologic features after radiation therapy were also analyzed.

Results: PFS was significantly improved in surgery group (log-rank $p=0.0097$; hazard ratio [HR], 0.3431; 95% CI, 0.152 to 0.772), as were OS (log-rank $p=0.0419$; HR, 0.3667; 95% CI, 0.139 to 0.964). Analysis of stage IIB demonstrates a similar result. There were no severe complications related to postradiation surgery in this series. The mean blood loss was less in laparoscopic group than those in the open group (87 mL vs. 208 mL, $p=0.036$, Mann-Whitney U-test). Approximately 47% patients (16/34) had pathologic residue tumor on hysterectomy specimens. About 94% patients (32/34) got complete remission after adjuvant surgery.

Conclusion: Adjuvant hysterectomy after CCRT improves survival outcome for patients with LACAC compared with current standard care. Extrafascial hysterectomy is sufficient in tumor reduction and laparoscopic procedure may be more promising with lower blood loss and expedite recovery.

Keywords: Adjuvant Extrafascial Hysterectomy; Chemoradiotherapy; Locally Advanced Cervical Adenocarcinoma; Survival

Jiaxin Yang

<http://orcid.org/0000-0002-9072-3581>

Dongyan Cao

<http://orcid.org/0000-0001-8808-7929>

Funding

Supported by the Scientific Project Design from Young and Middle-aged Researcher of Peking Union Medical College Hospital (pumch-2013-028); Department of Obstetrics and Gynecology, department of Pathology, Peking Union Medical College Hospital, Chinese Academy of Medical Science.

Conflict of Interest

No potential conflict of interest relevant to this article was reported.

INTRODUCTION

Cervical cancer is the third most commonly diagnosed cancer and the fourth leading cause of cancer death in females worldwide, accounting for 11% of the total female cancer deaths [1]. Approximately 60% patients of cervical cancer are diagnosed with bulky or advanced diseases that are no longer candidates for primary radical surgery [2]. In the last decade, radiotherapy consisting of external beam radiation and intracavitary brachytherapy, in combination with concurrent platin-based chemotherapy has produced substantial improvement in overall survival (OS) and control of distant recurrence. Definitive concurrent chemoradiotherapy (CCRT) is the standard of care for patients with International Federation of Gynecology and Obstetrics (FIGO) stage IB2, IIA2, IIB, IIIA, IIIB, and IVA disease. Many squamous cell carcinoma (SCC) can even be cured by CCRT [3]. Despite these improvements in SCC practice, emerging evidences suggest adenocarcinoma (AC) may be more radio-resistant [3] and nearly 50% of cases still have residual disease (RD) after CCRT [4]. RD after primary CCRT is directly associated to local recurrence. Many researchers have showed a worse prognosis in AC compared with SCC with a 20% difference in OS, and this becomes more apparent as the stage increases [5].

Traditionally, cervical AC is treated similar to SCC. However, there is increasing evidence that AC behaves differently, with different epidemiology, patterns of spread and recurrence, prognostic factors, and response to radiation therapy (RT). In addition, by virtue of screening strategies and human papilloma virus vaccine, the proportion of cervical SCC has decreased. On the contrary, AC has increased to 20% to 25% [5]. Since CCRT for advanced cervical AC is unsatisfactory, a more aggressive therapy is in demand [6]. To evaluate RD and improve local control, adjuvant hysterectomy after radical standard CCRT was investigated since 2004 in Peking Union Medical College Hospital (PUMCH). In consideration of the difficulties in radical excision and retroperitoneal lymphadenectomy after radiation, and to minimize surgery-related complications and morbidity, extrafascial hysterectomy and bilateral salpingo-oophorectomy was performed in patients with advanced AC after CCRT. We conducted this study to determine whether patients received adjuvant hysterectomy have better prognosis than those only treated with a standard CCRT. We also analyzed the features of surgery after CCRT.

MATERIALS AND METHODS

We conducted a retrospective study using PUMCH database from 2004 to 2014. This study method was approved by the PUMCH Review Board. Informed consent to chemo, RT and surgery was obtained from all patients in accordance to institutional requirements.

1. Population

Patients with previously untreated locally advanced cervical adenocarcinoma (LACAC) in FIGO stage IB2, IIA2, IIB, III were eligible for the study and were randomly assigned to two wards at initial diagnosis. One ward followed to traditional therapeutic procedure in LACAC and the other ward was recommended adjuvant hysterectomy after CCRT. All the patients received pre-treatment evaluation including vaginal examination, serum cancer antigen 125 (CA-125) test, thorough image examination of magnetic resonance imaging or computed tomography, and cervical tumor biopsy. Lymph node in imaging study with shorter diameter

over 10 mm, defined as lymphadenopathy, was considered as metastasis. Two experienced gynecologic oncologists determined the FIGO stage of each case. Histologic diagnosis and differentiation degree were confirmed by at least two pathologists. Patient information was collected, including age at diagnosis, tumor size, clinical stage, radiation (approach, doses), chemotherapy (approach, regimen, and courses), surgery (duration, perioperative blood loss, and complications), pathologic findings (RD, margin, lymph-vascular space invasion, parametrial infiltration), clinical prognosis, and follow-up.

2. Treatment

All the patients received standard RT including external pelvic irradiation and brachytherapy in PUMCH. One course of neoadjuvant chemotherapy (NAC) was added if waiting time for CCRT was longer than 1 month. The radiation doses were dependent on tumor volume with external beam radiation of 40 to 58 Gy and brachytherapy of 30 to 48 Gy. Radiotherapy was completed within 8 weeks. Concurrent chemotherapy including weekly cisplatin (40 mg/m^2), or weekly paclitaxel (75 mg/m^2) for patients with impaired renal function (glomerular filtration rate $<60 \text{ mL/min}$) that was not eligible for cisplatin chemotherapy. Clinical response of radiation was evaluated by imaging and pelvic examination one month after CCRT and cervical biopsy was performed if residue tumor was suspected. In the study group, all the patients received extrafascial hysterectomy and bilateral salpingo-oophorectomy at 10 to 12 weeks after CCRT completion. Vaginal margins, parametrium, lymphovascular space, and cervical stroma were microscopically verified. Any positive findings led to platin-based consolidation chemotherapy of 3 to 6 courses. Chemotherapy regimen included paclitaxel plus carboplatin (TC; T, 175 mg/m^2 ; C, area under the curve=5) or paclitaxel plus cisplatin (TP; T, 175 mg/m^2 ; P, 70 mg/m^2) in 21-day schedule. Patients in standard care group also received no less than 3 courses of platin-based consolidation chemotherapy if any sign of residue disease after CCRT. Post-treatment surveillance was every 3 to 6 months for the first 2 years, and annually since the 3rd year (Fig. 1).

3. Outcome

The two groups were initially compared to see if any difference in age, grade, stage, tumor size, lymph node metastasis on imaging, NAC before CCRT or response to radiotherapy. Patients were followed until death, lost to follow-up, or the end of the observation period (October 30, 2014). The primary objective was clinical progression-free survival (PFS), defined as the time in months from study enrollment to disease progression or death for non-censored observations or to date of last contact for censored observations. The secondary efficacy measure was OS, defined as time in months from study enrollment to death for non-censored observations or to date of last contact for censored observations. Patients were stratified based on stage at diagnosis, subgroup analysis of stage IIB and patients without NAC was analyzed separately to minimize the confounding. Surgery feasibility, approach, and the operative outcomes, including blood loss, complication rates were also analyzed.

4. Statistical analysis

SPSS ver. 20.0 (IBM Co., Armonk, NY, USA) and Prism 5.0c software (GraphPad, La Jolla, CA, USA) were used for statistical analysis. PFS and OS were estimated with the Kaplan-Meier method of log-rank test. Median PFS and OS were calculated with the reverse Kaplan-Meier method. A multivariate analysis was performed with Cox proportional hazards model to determine risk factors after adjustment for known prognostic variables. Frequency distributions were compared with chi-square and Fisher's exact test, mean and median

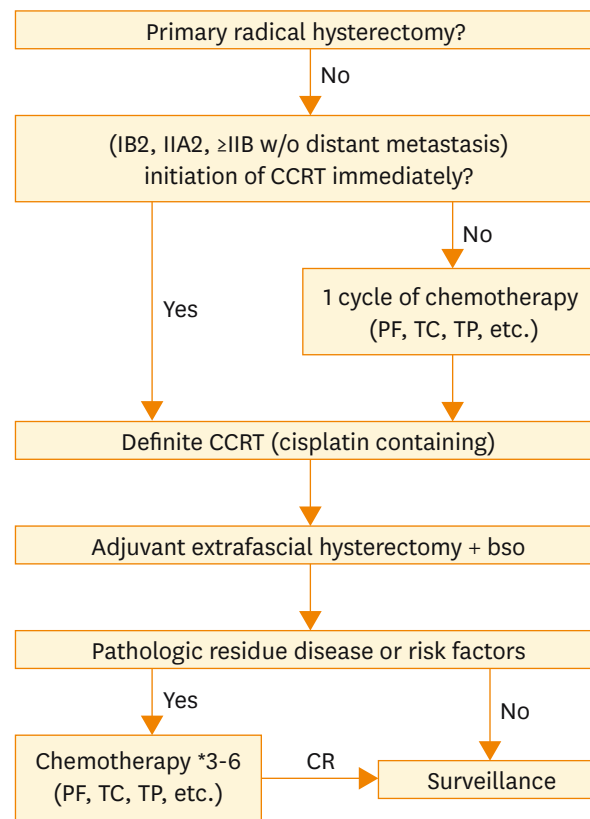


Fig. 1. Treatment flow diagram of adjuvant surgical therapy. BSO, bilateral salpingo-oophorectomy; CCRT, concurrent chemoradiotherapy; CR, complete remission; PF, cisplatin plus 5-fluorouracil; TC, paclitaxel plus carboplatin; TP, paclitaxel plus cisplatin.

values in the groups were compared with the Mann-Whitney U-test. A $p < 0.05$ was considered statistically significant.

RESULTS

1. Observation time

From January 2004 to October 2014, we reviewed 55 patients with LACAC who had completed the radical radiotherapy (34 with post-RT hysterectomy). Fifty-two patients (94.5%) were regularly followed-up. The median follow-up duration was 21 months (28 months in study group and 16 months in standard care group), and the maximum follow-up duration was 94 months.

2. Clinical characteristics

Baseline clinical characteristics were compared between two groups (Table 1). Age distribution, gravida and para, tumor size, CA-125 level, FIGO stage, grade, lymphadenopathy, chemotherapy before CCRT and clinical response rate after CCRT between the two groups had no statistical difference ($p > 0.05$). Although statistical results showed no difference in clinical stage ($p = 0.16$), there were more cases of FIGO stage III in standard care group (19%) as compared to study group (8.8%).

Table 1. Baseline patient clinical characteristics for all patients

Characteristic	CCRT+hysterectomy (n=34)	Only CCRT (n=21)	p-value*
Age (yr)	46.5 (39.75–54.25)	49 (40.5–59.5)	0.25
Size (cm)			0.17
≥4	18 (52.9)	15 (71.4)	
<4	16 (47.1)	6 (28.6)	
Grade			0.56
1	13 (38.2)	6 (28.6)	
2	13 (38.2)	7 (33.3)	
3	4 (11.8)	5 (23.8)	
Undefined	4 (11.8)	3 (14.3)	
Stage			0.16
IB2	3 (8.8)	1 (4.8)	
IIA	4 (11.8)	1 (4.8)	
IIB	24 (70.6)	15 (71.4)	
III	3 (8.8)	4 (19)	
Pregnancy	3 (2–4)	2 (1–3)	0.83
Delivery	1 (1–1)	1 (1–2)	0.96
CA-125 elevation (%)	14 (41.2)	12 (57.1)	0.25
Lymphadenopathy (%)	10 (29.4)	7 (33.3)	0.76
Chemo before CCRT (%)	23 (67.7)	13 (61.9)	0.66
CR after CCRT	18 (52.9)	10 (47.6)	0.93

Values are presented as median (interquartile range) or number (%).

CA-125, cancer antigen 125; CCRT, concurrent chemoradiotherapy; CR, complete remission.

*Fisher exact test for qualitative variables and Mann-Whitney U-test for quantitative variables.

3. Outcomes

There was statistically significant improvement for study group over standard care group in PFS (median PFS, 48 months vs. 10 months; PFS at 3 year, 50.3% vs. 31.7%; $p=0.010$; hazard ratio [HR], 0.343; 95% CI, 0.152 to 0.772). The median OS of study group was also statistically significantly superior to standard care group (median OS, 58 months vs. 36 months; $p=0.042$; HR, 0.367; 95% CI, 0.139 to 0.964). In FIGO stage IIB, study group had a statistically better prognosis in both PFS ($p=0.041$; HR, 0.335; 95% CI, 0.117 to 0.953) and OS ($p=0.003$; HR, 0.118; 95% CI, 0.029 to 0.484). The estimated median PFS was 48 months versus 23 months and PFS at 3 years was 58.5% versus 34.6%, respectively (Table 2, Fig. 2). There were 11 patients in study group and eight patients in standard care group who had not received NAC. Survival analysis showed a favorable outcome in PFS ($p=0.494$; HR, 0.637; 95%

Table 2. Prognosis outcome and stratification analysis

Variable	CCRT+hysterectomy	CCRT	HR (95% CI)	p-value*
Outcome (median)	34	21		
PFS (mo)	48	10	0.343 (0.152–0.772)	0.010
PFS at 3 yr (%)	50.3	31.7		
OS (mo)	58	36	0.367 (0.139–0.964)	0.042
OS at 3 yr (%)	81.0	48.2		
Stage IIB	24	15		
PFS (mo)	48	23	0.335 (0.117–0.953)	0.041
OS (mo)	Undefined	29	0.118 (0.029–0.484)	0.003
Without NAC	11	8		
PFS (mo)	48	23	0.637 (0.175–2.322)	0.494
OS (mo)	Undefined	36	0.032 (0.053–1.869)	0.203

CCRT, concurrent chemoradiotherapy; HR, hazard ratio; NAC, neoadjuvant chemotherapy; OS, overall survival; PFS, progression-free survival.

*Log rank test.

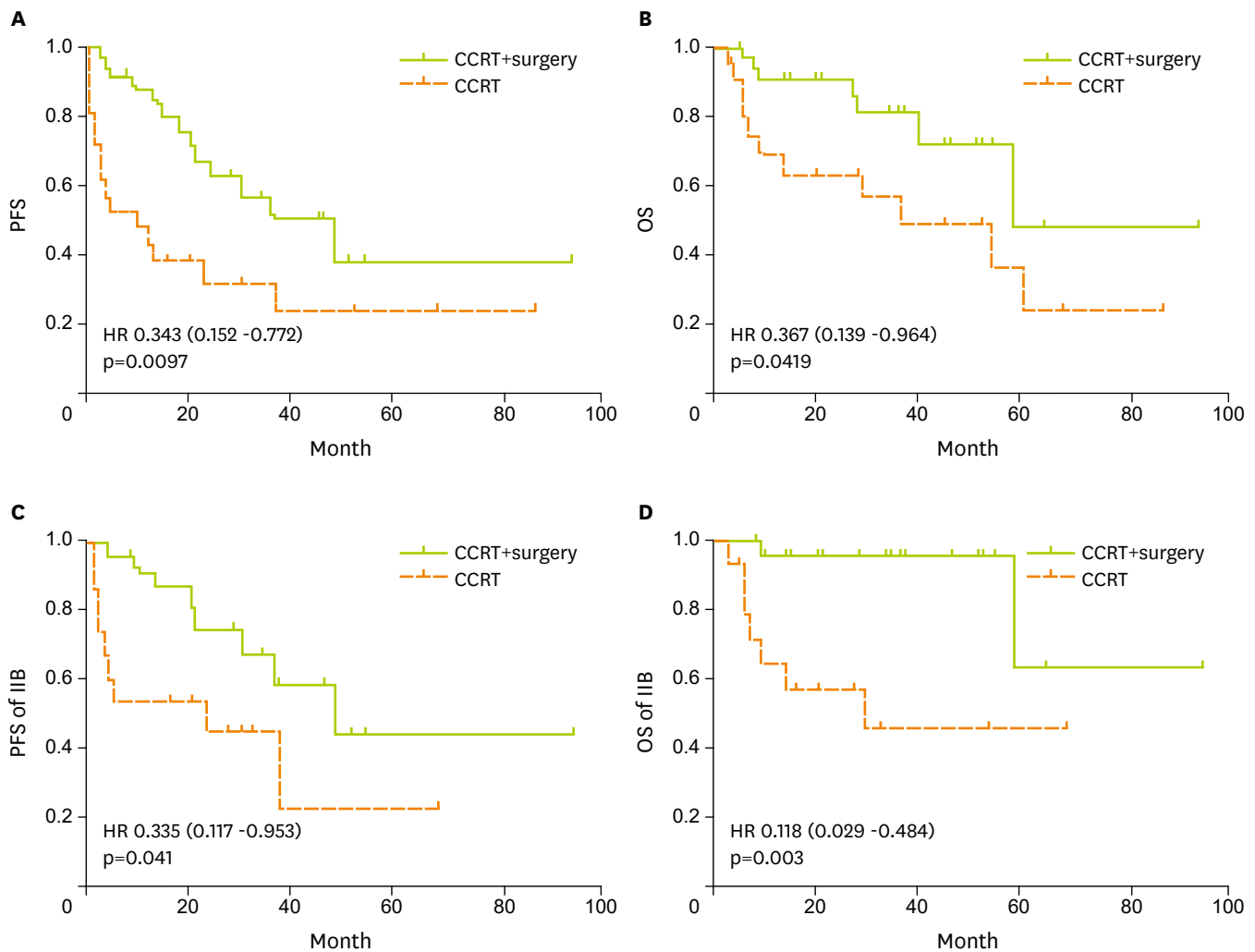


Fig. 2. Kaplan-Meier estimates of (A, C) progression-free survival (PFS) and (B, D) overall survival (OS) for two groups and stage IIB subgroup. CCRT, concurrent chemoradiotherapy; HR, hazard ratio.

CI, 0.175 to 2.322) and OS ($p=0.203$; HR, 0.032; 95% CI, 0.053 to 1.869) without statistical significance (Table 2).

4. Surgery group analyzes

In the study group, 34 women underwent hysterectomy and salpingo-oophorectomy after primary CCRT. The mean duration from end of CCRT to surgery was 2.6 months (1 to 4 months). Since 2014, laparoscope was attempted to use in postradiation hysterectomy and four patients underwent laparoscopic surgery successfully. None of the laparoscopic surgeries changed to laparotomy. There were no casualties related to surgery. Complications related to surgical procedures were bladder lesion, which occurred in three patients (8.8%). Bladder repairs were performed intraoperatively and all the three patients achieved complete recovery. The mean blood loss was less in laparoscopic group than that in laparotomy group (87 mL vs. 208 mL, $p=0.036$, Mann-Whitney U-test). One patient received blood transfusion during surgery. Approximately 53% patients (18/34) had histologic complete remission (CR) after CCRT. These 41.1% patients (14/34) had microscopic RD, 5.8% patients (2/34) had gross RD

Table 3. Potential risk factors of residue disease on the hysterectomy specimen

Characteristic	RD		Univariate		Multivariate	
	-	+	HR (95% CI)	p-value*	HR (95% CI)	p-value†
Size (cm)				0.086		0.065
≥4	7	11	1		1	
<4	11	5	0.51 (0.276–1.155)		0.232 (0.049–1.095)	
CA-125				0.315		0.312
Elevated	9	5	1		1	
Normal	9	11	1.54 (0.687–3.451)		2.468 (0.512–12.1)	
Grade				1.00		0.947
3	9	8	1		1	
1–2	9	8	1.00 (0.490–2.04)		1.056 (0.214–5.22)	
Stage				1.00		0.836
≥IIb	14	13	1		1	
<IIb	4	3	0.089 (0.119–5.61)		1.226 (0.178–8.43)	
Concurrent				0.725		0.497
≥3 Chemo	12	9	1		1	
<3 Chemo	6	7	1.26 (0.621–2.54)		1.791 (0.333–9.64)	
Adjuvant chemo				0.717		0.453
Yes	13	10	1		1	
No	5	6	1.25 (0.615–2.56)		1.946 (0.342–11.07)	

CA-125, cancer antigen 125; HR, hazard ratio; RD, residue disease.

*Chi-squared test. †Logistic regression.

with residual tumor extent beyond the vaginal or parametrial margin of uterine specimen. CR rate after adjuvant surgery was 94.1% (32/34). Risk factors for RD were analyzed, including clinical stage, tumor grade, size, courses of concurrent chemotherapy, and pre-radiation chemotherapy. Tumor size (p=0.086; HR, 0.511; 95% CI, 0.276 to 1.155) was most relevant to RD but without statistical significance (Table 3).

5. Surveillance

After CCRT, 18 patients in study group and 10 patients in standard care group achieved CR. Patients with recorded regular follow-up showed recurrence rate of 22.2% (4/18) in study group and 37.5% (3/8) in standard care group, respectively (p=0.42, chi-square). In hysterectomy group, three patients suffered distant metastasis and one patient with vaginal residue recurrence. In CCRT alone group, one patient had distant metastasis and two patients cervical recurrence. The local recurrent rate was 5.5% versus 25.0% (p=0.152, chi-square).

DISCUSSION

In this retrospective cohort, adjuvant hysterectomy after CCRT confers a more favorable prognosis (PFS, PFS at 3 years, and OS) over CCRT alone in LACAC with similar baseline tumor status. To our knowledge, this study is the first report of isolating AC subtype to analyses and showing significant improvement in survival outcomes for LACAC with combination approaches compared with current CCRT. To minimize the confounding by different stage distribution, stage IIB were stratified to be analyzed alone and a similar benefit from adjuvant hysterectomy was demonstrated.

A few previous studies have investigated the value of adjuvant hysterectomy after chemo-RT of locally advanced cervical cancer. Results are controversial. Sun et al. [7] showed

an improvement of local disease control in patients with a partial pathologic response and enhanced survival. The study of Motton et al. [8] failed to demonstrate significant improvement of survival by completion surgery and early morbidity was higher after hysterectomy. Moreover, most studies have suggested an improvement in local control but failed to demonstrate an unequivocal benefit in survival [9-11]. However, major pathology type in these publications were SCC, of which chemoradiotherapy is thought to be efficient and beneficial in improving local disease control [12]. Unlike SCC, it has been demonstrated in several studies that AC are more radio-resistant, which is considered to be an important reason for the poor prognosis associated with AC [13]. Some studies suggest a higher recurrence rates after RT in ACs compared to SCC [14]. Therefore it is more reasonable to separate AC from general cervical cancer in evaluating the efficacy of completion surgery after CCRT separately. Despite the debate involving the clinical significance of completion hysterectomy in locally advanced cervical cancer, it is recognized as an effective approach in reduction of residue disease after CCRT.

RD is recognized as a significant prognostic factor [15] due to its relation to incomplete response to CCRT and future local relapse. Favero et al. [4] reported approximately 30% of the patients with complete clinical and radiologic response submitted to adjuvant hysterectomy had RD on histologic analysis of the specimen, and in 78% of these cases, histologic finding was AC, 50% of AC had pathologic residue disease. This was very similar to our results (47.0%), and the differences of recurrent pattern between the two groups also suggested that completion surgery is a rational method in control of regional and local recurrence. Variable factors may be associated with RD after radical CCRT have been reported in literature [16], however much remains controversial. Although initial tumor size was most relevant to RD, none of those potential risk factors analyzed in this AC series was statistically significant.

Nevertheless, except for seldom patients who were extremely insensitive to CCRT and had gross residue tumor, most patients achieved CR by extrafascial hysterectomy with clear surgical margin in vagina and parametrium. Thus, a less radical hysterectomy might be sufficient. On completion of RT, tissue fibrosis and vascular impairment increase difficulties and complications of surgery [15]. Avoiding radical hysterectomy greatly reduces procedure-related morbidity and postsurgery impairment [17]. In this cohort, we report no severe complication caused by postradiation surgery. Besides, we found that laparoscopic procedure is promising in postradiation hysterectomy with lower blood loss and expedites recovery. The value of laparoscopic surgery in gynecological cancer has been confirmed by several prospective trials [18]. In our opinion, in either laparotomy or laparoscopy, extrafascial hysterectomy is appropriate in local control of bulky or advanced AC after definitive CCRT without grossly residue disease.

Since the frequency of ovarian metastasis is higher in AC than in SCC (5.3% vs. 0.7%) [19], we provide bilateral salpingo-oophorectomy simultaneously. However, due to lack of randomized trial, the prognostic value from oophorectomy needs further investigation.

It is controversial to provide NAC before CCRT in the management of locally advanced cervix cancer. Some published articles which had proved the efficacy of NAC before CCRT [12,20]. LACC patients in our center who received NAC were dependent on the waiting time for radiation, which was variable due to many social-economic reasons. In addition, the number of cases in this series was too small, that our data could not elucidate the efficacy of NAC in LACC.

Our study has certain limitations. First, the cohort size is relatively small. Theoretically, randomized control trials could be less prone to bias; however, the only randomized trial in this scenario (GYNECO 02) was closed because of insufficient recruitment of participants who were in favor of completion surgery and refused to participate in the randomization [11]. Second, patients in this study were not randomly allocated to different arm at beginning. Although patients in this study were statistically similar for several known clinical factors between two groups, factors such as tumor stage, NAC before CCRT and some other prognostic or predictive factors may have been unevenly distributed. This is a shortage hardly evitable in retrospective studies. Third, the locally advanced stage includes a wide range of participants in FIGO IA2, IIA2, IIB, and III. Optimal patient selection needs further investigation. Since extrafascial hysterectomy is only capable at local control, we suggest this multimodality treatment should be specifically limited to those without distant metastasis. However, AC patients are associated with higher rate of lymph node metastasis [21]. In that case, previous study noted laparoscopic nodal staging before beginning of CCRT, although it would result in the execution of 2 surgical procedures and consequently, elevate morbidity [4].

In conclusion, our study demonstrates that adjuvant extrafascial hysterectomy and bilateral salpingo-oophorectomy after CCRT improves prognosis for patients with LACAC, compared with current standard of care. It is unknown whether adjuvant chemotherapy and laparoscopic nodal staging before CCRT will have impact on survival outcomes. Further studies are required to define optimal candidates and optimal scheme of this multimodality therapy.

REFERENCES

1. Jemal A, Bray F, Center MM, Ferlay J, Ward E, Forman D. Global cancer statistics. *CA Cancer J Clin* 2011;61:69-90.
[PUBMED](#) | [CROSSREF](#)
2. Quinn MA, Benedet JL, Odicino F, Maisonneuve P, Beller U, Creasman WT, et al. Carcinoma of the cervix uteri. FIGO 26th Annual Report on the Results of Treatment in Gynecological Cancer. *Int J Gynaecol Obstet* 2006;95 Suppl 1:S43-103.
[PUBMED](#) | [CROSSREF](#)
3. Wiebe E, Denny L, Thomas G. Cancer of the cervix uteri. *Int J Gynaecol Obstet* 2012;119 Suppl 2:S100-9.
[PUBMED](#) | [CROSSREF](#)
4. Favero G, Pierobon J, Genta ML, Araújo MP, Miglino G, Del Carmen Pilar Diz M, et al. Laparoscopic extrafascial hysterectomy (completion surgery) after primary chemoradiation in patients with locally advanced cervical cancer: technical aspects and operative outcomes. *Int J Gynecol Cancer* 2014;24:608-14.
[PUBMED](#) | [CROSSREF](#)
5. Fujiwara H, Yokota H, Monk B, Treilleux I, Devouassoux-Shisheboran M, Davis A, et al. Gynecologic Cancer InterGroup (GCIG) consensus review for cervical adenocarcinoma. *Int J Gynecol Cancer* 2014;24 Suppl 3:S96-101.
[PUBMED](#) | [CROSSREF](#)
6. Fujiwara K, Monk B, Devouassoux-Shisheboran M. Adenocarcinoma of the uterine cervix: why is it different? *Curr Oncol Rep* 2014;16:416.
[PUBMED](#) | [CROSSREF](#)
7. Sun L, Sheng X, Jiang J, Li X, Liu N, Liu Y, et al. Surgical morbidity and oncologic results after concurrent chemoradiation therapy for advanced cervical cancer. *Int J Gynaecol Obstet* 2014;125:111-5.
[PUBMED](#) | [CROSSREF](#)
8. Motton S, Houvenaeghel G, Delannes M, Querleu D, Soulé-Tholy M, Hoff J, et al. Results of surgery after concurrent chemoradiotherapy in advanced cervical cancer: comparison of extended hysterectomy and extrafascial hysterectomy. *Int J Gynecol Cancer* 2010;20:268-75.
[PUBMED](#) | [CROSSREF](#)

9. Ota T, Takeshima N, Tabata T, Hasumi K, Takizawa K. Adjuvant hysterectomy for treatment of residual disease in patients with cervical cancer treated with radiation therapy. *Br J Cancer* 2008;99:1216-20.
[PUBMED](#) | [CROSSREF](#)
10. Touboul C, Uzan C, Mauguen A, Gouy S, Rey A, Pautier P, et al. Prognostic factors and morbidities after completion surgery in patients undergoing initial chemoradiation therapy for locally advanced cervical cancer. *Oncologist* 2010;15:405-15.
[PUBMED](#) | [CROSSREF](#)
11. Morice P, Rouanet P, Rey A, Romestaing P, Houvenaeghel G, Boulanger JC, et al. Results of the GYNECO 02 study, an FNCLCC phase III trial comparing hysterectomy with no hysterectomy in patients with a (clinical and radiological) complete response after chemoradiation therapy for stage IB2 or II cervical cancer. *Oncologist* 2012;17:64-71.
[PUBMED](#) | [CROSSREF](#)
12. Singh RB, Chander S, Mohanti BK, Pathy S, Kumar S, Bhatla N, et al. Neoadjuvant chemotherapy with weekly paclitaxel and carboplatin followed by chemoradiation in locally advanced cervical carcinoma: a pilot study. *Gynecol Oncol* 2013;129:124-8.
[PUBMED](#) | [CROSSREF](#)
13. Landoni F, Maneo A, Colombo A, Placa F, Milani R, Perego P, et al. Randomised study of radical surgery versus radiotherapy for stage Ib-IIa cervical cancer. *Lancet* 1997;350:535-40.
[PUBMED](#) | [CROSSREF](#)
14. Rotman M, Sedlis A, Piedmonte MR, Bundy B, Lentz SS, Muddersbach LI, et al. A phase III randomized trial of postoperative pelvic irradiation in Stage IB cervical carcinoma with poor prognostic features: follow-up of a gynecologic oncology group study. *Int J Radiat Oncol Biol Phys* 2006;65:169-76.
[PUBMED](#) | [CROSSREF](#)
15. Ferrandina G, Legge F, Fagotti A, Fanfani F, Distefano M, Morganti A, et al. Preoperative concomitant chemoradiotherapy in locally advanced cervical cancer: safety, outcome, and prognostic measures. *Gynecol Oncol* 2007;107 Suppl 1:S127-32.
[PUBMED](#) | [CROSSREF](#)
16. Lee KB, Lee JM, Park CY, Lee KB, Cho HY, Ha SY. What is the difference between squamous cell carcinoma and adenocarcinoma of the cervix? A matched case-control study. *Int J Gynecol Cancer* 2006;16:1569-73.
[PUBMED](#) | [CROSSREF](#)
17. Ma Z, Liu R, Wang X, Huang M, Gao Q, Lu Y, et al. Spontaneous germline potential of human hepatic cell line in vitro. *Mol Hum Reprod* 2013;19:216-26.
[PUBMED](#) | [CROSSREF](#)
18. Mettler L, Meinhold-Heerlein I. The value of laparoscopic surgery to stage gynecological cancers: present and future. *Minerva Ginecol* 2009;61:319-37.
[PUBMED](#)
19. Shimada M, Kigawa J, Nishimura R, Yamaguchi S, Kuzuya K, Nakanishi T, et al. Ovarian metastasis in carcinoma of the uterine cervix. *Gynecol Oncol* 2006;101:234-7.
[PUBMED](#) | [CROSSREF](#)
20. Osman M. The role of neoadjuvant chemotherapy in the management of locally advanced cervix cancer: a systematic review. *Oncol Rev* 2014;8:250.
[PUBMED](#) | [CROSSREF](#)
21. Irie T, Kigawa J, Minagawa Y, Itamochi H, Sato S, Akeshima R, et al. Prognosis and clinicopathological characteristics of Ib-IIb adenocarcinoma of the uterine cervix in patients who have had radical hysterectomy. *Eur J Surg Oncol* 2000;26:464-7.
[PUBMED](#) | [CROSSREF](#)