

. . . *

가

< >

:

: 1992 1 2000 12 가 1 가 가 93

, 70 Singh's index 3 34 (Group I), Group I
가 20 (Group II), 70 Singh's index 4
39 (Group III)

: Group I(n=34) Group III(n=39) merle d'Aubigne hip rating scale 가
(Group I: 89%, Group III:87%) , Group II(n=20) 16

Group I 1 , Group II 4 , 10 ,
2 19 , Group III 1 , 2 8

: 70 , 70

가
가

:

:

6 665

가

TEL : 032-510-5500

FAX : 032-505-7795

E-mail : drcst@lycos.co.kr

34 , Group II Group I

20 , Group III 70

Singh index 4

39

ASA

가

가

(bone quality)

class II 71 (76%) (Table 1).

Singh index

(Group I) grade III 71 21 ,

(Group II and III) grade IV 7† 33

가 (Table 2).

Table 1. ASA classification of 3 group

Class \ Group	1	2	3
Group I	0	26	8
Group II	0	14	6
Group III	3	31	5

Table 2. Singh classification of 3 group

Index Group	I	II	III	IV	V	VI	Total
Group I	2	11	21	0	0	0	34
Group II	1	7	12	0	0	0	20
Group III	0	0	0	33	6	0	39

가78 (84%),

가9 (10%), 가6 (6%) 가
가 .

Evans⁴⁾

46%,

26%, 6%, 4%,

2%, 2%

1992 1 2000 12 가

가 30%

1

가 16%

(79%),

가 가 93

가 16 (17%), 77 (83%)

가 74 .

12 5 2

1

3	Group	Group I
---	-------	---------

70 Singh index 3

가

stem

long distal fitting femoral stem

(Fig.1A~C). Group II III

5
가
Group

(Fig.2A~C, 3A~C).

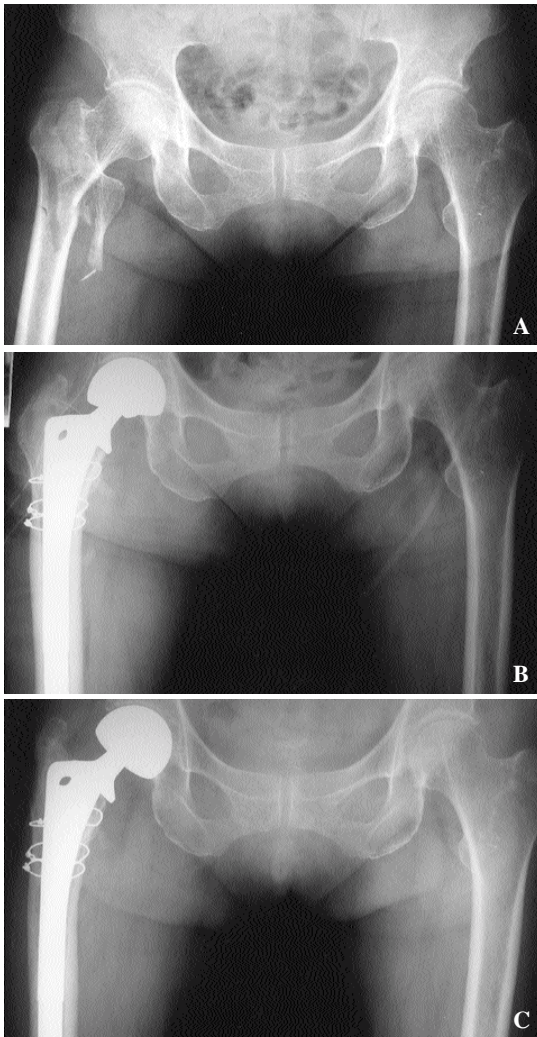


Fig. 1 : Serial radiograph of 78 year old woman treated by a noncemented bipolar hemiarthroplasty. **A.** Evans unstable intertrochanteric fracture. Preoperative radiograph. **B.** Immediate postoperative radiograph. **C.** Postoperative 2 years radiograph showed satisfactory result.

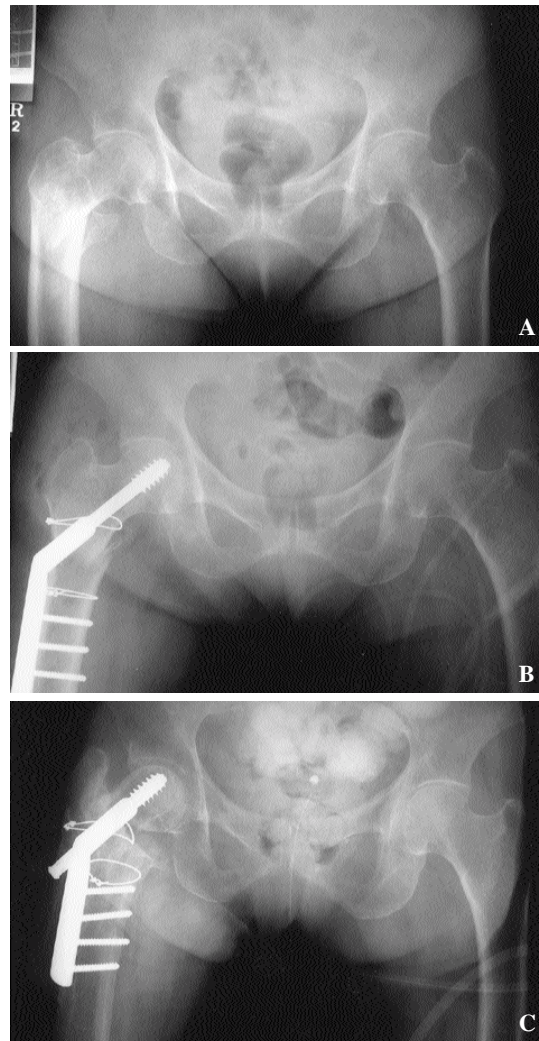


Fig. 2 : Serial radiograph of 74 year old woman treated by a compression hip screw. **A.** Evans unstable intertrochanteric fracture. Preoperative radiograph. **B.** Immediate postoperative radiograph. **C.** Postoperative 1 year radiograph showed nonunion.

가
7 ,
19 .
2 , 3
4 .
X-
 , , ,

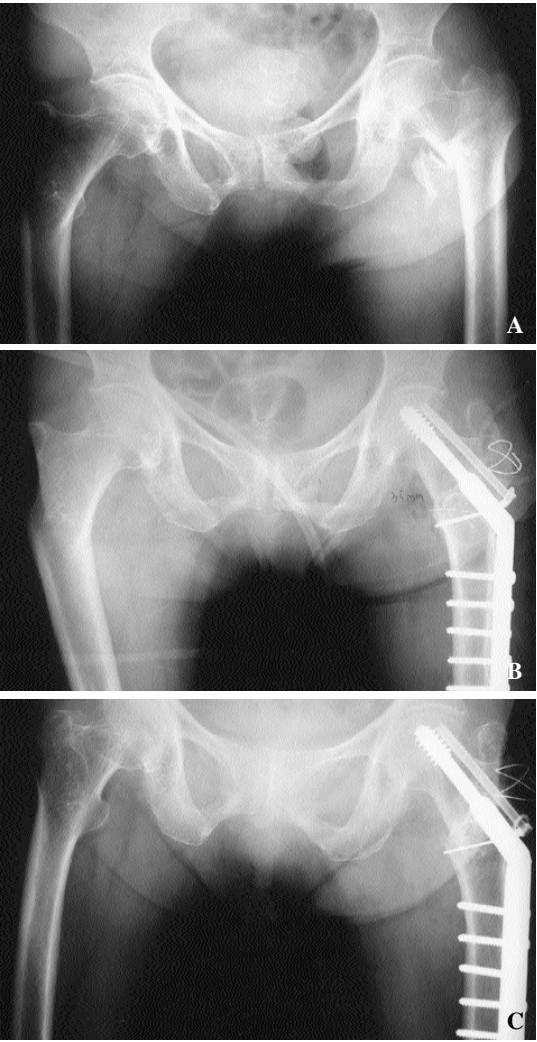


Fig. 3 : Serial radiograph of 69 year old woman treated with a compression hip screw. **A.** Evans unstable intertrochanteric fracture. Preoperative radiograph. **B.** Immediated postoperative radiograph. **C.** Postoperative 4 years after operation. The radiograph showed union of the fracture site. We obtained satisfactory result.

hip rating scale¹⁴⁾ Merle d'Aubigne (pain), (mobility), (walking ability) 3 6 18 excellent, 17 very good, 15, 16 good, 13, 14

fair, 9, 10, 11, 12 poor, 9 bad 7
Group I 3.1
(2-4), Group II III 13.5 (11-15)
, 12.2 (9-14)
Merle d'Aubigne hip-rating scale¹⁴⁾ 3, 6, 12
Excellent, Very
good, Good, Fair, Poor, Bad , Group I
, 34 3 Excellent 17%,
46%, 25%, 12% Poor Bad
. 6 20%, 50%, 17%, 12%
12 13%, 41%, 29%, 17%

Group II 20
3 Excellent 30%, 20%, 20%, 30%
Poor Bad . 6
10%, 10%, 30%, 30%, 20% Bad
12 Excellent, Very
good, Good Fair 20%, 60%, 20%
. Group III
39 3 Excellent 17%,
48%, 21%, 7% 7% Bad
. 6 7%, 59%, 21%, 10%, 3%
Bad . 12 10%,
48%, 21%, 3%, 10% bad
(Table 3). Group I
1 1.5cm

1
. Group II
4 , 10 , 2
, 3 19 가
1 ,
2 , 1 , 1 ,
1 . Group III
1 , 2 , 5

Table 3. Functional result by Merle d'Aubigne

Class \ Group	Group I(n=34)			Group II(n=20)			Group III(n=39)		
	3M	6M	12M	3M	6M	12M	3M	6M	12M
Excellent	6	6	5	6	2	0	7	3	4
Very good	16	17	14	4	2	0	18	23	21
Good	8	6	9	4	6	0	8	8	9
Fair	4	5	6	6	6	4	3	4	1
Poor	0	0	0	0	4	12	3	1	4
Bad	0	0	0	0	0	4	0	0	0

Table 4. Postoperative complications

	Group I	Group II	Group III
Coxa vara			1
Limb shortening	1		
Loosening of screws		2	
Femoral head perforation		2	
Delayed union			2
Nonunion		5	
Limitation of motion		3	3
Infection of wound	1	1	1
Pneumonia		2	2
Gastrointestinal problem		1	4
Bed sore		1	
Urinary tract infection		2	3

8

2 , 3 , 1 가

4 , 3 , 2

(Table 4).

(Group I) 1 ,

(Group II and III) 32

(Group II and III)

가 가

가

가

가

Hey-Groves⁹⁾Moore¹⁵⁾Thompson¹⁹⁾

가 1974

Bateman¹⁾Giliberty^{5, 6)}

1950

1922

Moore¹⁵⁾ (Singh index)

Singh index .

Stern Goldstein¹⁸⁾ 가 , ,

. Green⁷⁾ , ,

stem . Hinchey,^{JJ.10)} 2 3
, D 'Arcy

Deva¹³⁾ 가
가

. Haentigens⁸⁾

Merle d 'Aubigne¹⁴⁾ .

가 75%
, , , 가 ,

, , , , ,

, ,

, , ,

가
가 .

가 가
16%,

20% , 2

, , (2%) , ,

, . ,

,

, 2 .

,

1

. Sick¹⁶⁾
, , , 가 .
, 65 ,

Pauwel 3

Singh¹⁷⁾ 1970 가
Evans

93

Group I(n=34) Group III(n=39) merle d ' ,
Aubigne hip rating scale 14) 7+

(Group I: 89%, Group III: 87%)

, Group II(n=20) 16

¹⁾ Singh index 3

²⁾

³⁾

7+

REFERENCES

- 1) **Bateman JE** : Single-assembly total hip prosthesis, preliminary report. Orthop Digest, 2 : 15-22, 1974.
- 2) **Boyd HB and Griffin LL** : Classification and treatment of trochanteric fracture. Aarch Surg, 58:853-866, 1949.
- 3) **D 'arcy J and Deval M** : Treatment of fractures of the femoral neck by replacement with the Thompson prosthesis. J Bone Joint Surg, 58-B:279-286, 1976.
- 4) **Evans EM** : The treatment of trochanteric fractures of the femur. J Bone Joint Surg, 31-B: 190-203, 1949.
- 5) **Giliberty RP** : A new concept of a bipolar endoprosthesis. Orthop Review, 3:40-45, 1974.
- 6) **Giliberty RP** : Hemiarthroplasty of the hip using a low-friction bipolar endoprosthesis. Clin Orthop, 175:86-92, 1983.
- 7) **Green S, Moore T and Proano F** : Bipolar prosthetic replacement for the management of unstable intertrochanteric hip fractures in the elderly. Clin Orthop, 224:169-177, 1987.
- 8) **Haentjens P, Casteleyn PP, Boeck H De, Handelberg F and Opdecam P** : Treat-ment of unstable intertrochanteric and subtrochanteric fractures in elderly patients. J Bone Joint Surg, 74-B:203-205, 1994.
- 9) **Hey-Groves EW** : Treatment of fractured neck of the femur with special regard to the results. J Bone Joint Surg, 12:1-14, 1930.
- 10) **Hinchey JJ and Day PL** : Primary prosthetic replacement in fresh femoral neck frac-tures. J Bone Joint Surg, 46-A : 223-240, 1964.
- 11) **Jensen JS, Holm S and Tondelvold E** : Unstable trochanteric fracture. Acta Orthop Scand, 51: 949-962, 1980.
- 12) **Kang CN, Kim JO, Kim DW, Koh YD, Ko SH, Lee KW** : Comparision of hemiarth-roplasty and compression hip screw on elderly unstable intertrochanteric fractures. J Korean Society Fracture 10(4): 738-745, 1997.
- 13) **Kyle RF, Gustilo RB and Premer RF** : Analysis of six hundred and twenty-two inte-rtrochanteric hip fractures. J Bone Joint Surg, 56-A:899-907, 1974.
- 14) **Merle D 'Aubigne R** : Cotation, chiffree de la fonction. de la hanche. Rev chir orthop, 63 : 135-148, 1977.
- 15) **Moore MJ** : Treatment of trochanteric fractures with special reference to complication. Am J Surg, 84:449-457, 1952.
- 16) **Sick TD** : Campbells operative orthopaedics, Alknedmonson, C.V Mosby Co., St Lou- is. Toronto, London, 6th Edition : 615, 1980.
- 17) **Singh M, Nagraph AR and Maini PS** : Changes in trabecular pattern of the upper end of the femur as and index of osteoporosis. J Bone Joint Surg, 52-A:457-467, 1970.
- 18) **Stern NB and Goldstein TB** : The use of the Leinbach prosthesis in intertrochanteric fractures of the hip. Clin Orthop, 128:324-331, 1977.
- 19) **Thompson FR** : Two and a half years experience with a vitallium intramedullary hip prosthesis. J Bone Joint Surg, 36-A:489-502, 1954.
- 20) **Tronzo RC** : Special considerations in management. Ortho Clin North Am, 5:571-583, 1974.
- 21) **Yoo MC, Kim KT, Cho YJ, Sun SD, Park GC** : Treatment of femur neck and intertr ochanteric Fractures in elderly with primary hemiarthroplasty. J Korean Society Fract ure, 7(2): 412-421, 1994.

Abstract

Primary Bipolar Hemiarthroplasty for Treatment of Unstable Intertrochanteric Fracture of the femur in Elderly patients

Jong Min Sohn, M.D., Ju Hae Jahng, M.D., Nan Kyung Ha, M.D.,
Seong Tae Cho, M.D., Kwang Young Choi, M.D.

*Department of Orthopedic Surgery, The Catholic University of Korea, College of Medicine.
Our Lady of Mercy Hospital, Incheon, Korea*

Purpose : The purpose of this study was to evaluate the effectiveness and advantage of bipolar hemiarthroplasty in treatment of unstable femoral intertrochanteric fracture in elderly patients.

Materials and Methods : We reviewed 93 patients and followed up more than one year. Group I(n=34, Singh index <3 with more than 70 year old) were treated by bipolar hemiarthroplasty. Group II(n=20) with same condition were treated by compression hip screw. Group III(n=39, Singh index >4 with more than 70 year old) were treated by compression hip screw.

Results : Group I and III patients showed satisfactory result over than good by merle D 'Aubigne hip rating scale. Among Group II(n=20), 16 cases showed under ' poor ' according to functional scale. Complication was 1 cases in group I, 19 cases in group II and 8 cases in group III.

Conclusion : We suggest bipolar hemiarthroplasty as first choice of treatment for osteoporotic elderly patients with unstable intertrochanteric fracture, especially who have combined medical problems or poor general condition.

Key Words : Bipolar hemiarthroplasty, Unstable femoral intertrochanteric fracture, Elderly patient

Address reprint requests to _____

Seong Tae Cho

The Catholic University of Korea, College of Medicine.

Our Lady of Mercy Hospital, Incheon, Korea

TEL : 032-510-5500

FAX : 032-505-7795

E-mail : drcst@lycos.co.kr