



13, 4, 2000 10

The Journal of the Korean Society of Fractures  
Vol.13, No.4, October, 2000

- 2 -

. . . \*

&lt; &gt;

2

: ,

1,4,7)

1

11

가

2,3,10)

11

( )

1 17

가

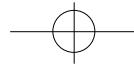
1

:

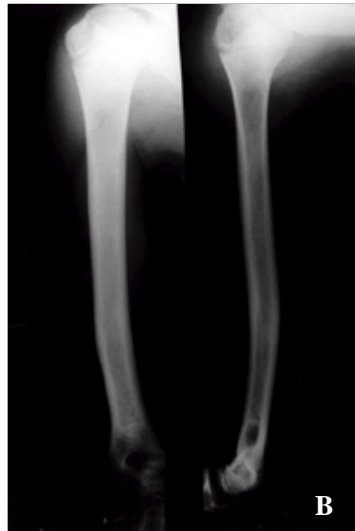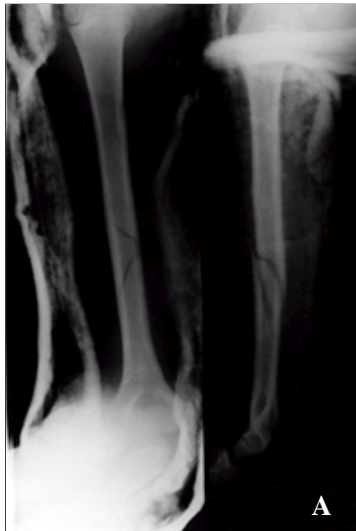69-7,

Tel : (054) 245-5162  
Fax : (054) 245-5311  
E-mail : orthokwon @hanmail.net.

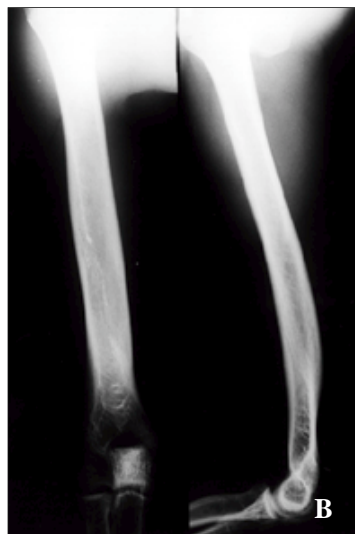
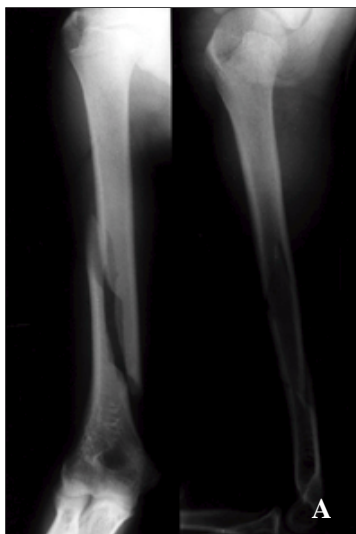


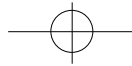
가 2  
17  
가  
U  
가  
1/3  
U  
(Fig. 1).  
(Fig. 2).



**Fig 1A-B.** (A) Initial radiograph shows displaced spiral fracture of mid-shaft of the humerus. (B) The latest follow-up radiograph at 29 months shows fracture healing.



**Fig 2A-B.** (A) Initial radiograph shows displaced spiral fracture of distal shaft of the humerus. (B) The latest follow-up radiograph at 23 months shows fracture healing.



1930 Wilmoth가

Ogawa Yoshida<sup>5)</sup>

가

Chao <sup>2)</sup>, DiCicco <sup>3)</sup>, Ogawa

DiCicco <sup>3)</sup> (cocking phase)

Yosida<sup>5)</sup>, <sup>4)</sup>

가 (acceleration phase)

(propulsive phase)

Ogawa Yoshida<sup>5)</sup>

6)

, Branch <sup>1)</sup>, Polu

17

, Chao <sup>2)</sup>, DiCicco <sup>3)</sup>, Wesely Barenfeld<sup>9)</sup>

가

가

가

, Branch <sup>1)</sup> 30

49),

5)

U

가

7).

U

가

가

2

가

## REFERENCES

가

11

가

가

Tullo

가

King<sup>8)</sup>

가

Wesely Barenfeld<sup>9)</sup>

. 1971 Chao <sup>2)</sup>

7 foot-pound

가

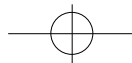
DiCicco <sup>3)</sup>

1) **Branch T, Partin C, Chamberland P, Emeterio E and Sabetelle M** : Spontaneous fractures of the humerus during pitching. A series of 12 cases. *Am J Sports Med*, 20:468-470, 1992.

2) **Chao SL, Miller M and Teng SW** : A mechanism of spiral fracture of the humerus: A report of 129 cases following the throwing of hand grenades. *J Trauma*, 11:602-605, 1971.

3) **DiCicco JD, Mehlman CT and Urse JS** : Fracture of the shaft of the humerus secondary to muscular violence. *J Orthop Trauma*, 7:90-93, 1993.

4) **Jung JJ, Roh KJ and Lee WG** : Fracture of the humerus from throwing hand grenades. report of 4 cases. *J of Korean Orthop Surgery*, 16:668-671, 1981.



- 5) **Ogawa K and Yoshida A** : Throwing fracture of the humeral shaft. An analysis of 90 patients. *Am J Sports Med*, 26:242-246, 1998.
- 6) **Polu KR**, Schenck RC Jr, Wirth MA and Greeson J, Cone RO 3rd, Rockwood CA Jr: Stress fracture of the humerus in a collegiate baseball pitcher. A case report. *Am J Sports Med*, 27:813-816, 1999.
- 7) **Reed WJ and Mueller RW** : Spiral fracture of the humerus in a ball thrower. *Am J Emerg Med*, 16:306-308, 1998.
- 8) **Tullos HS and King JW** : Throwing fractures in sports. *Orthop Clin North Am*, 4:709-720, 1983.
- 9) **Weseley MS and Barenfeld PA** : Ball thrower 's fracture of the humerus. Six case reports. *Clin Orthop*, 64:153-156, 1969.

### Abstract

## Throwing Fractures of the Humerus - 2 Cases Report -

**Jin-Woo Kwon, M.D., Seung-Ho Shin, M.D., Won-Ho Cho, M.D.,  
Woo-Se Lee, M.D., Ki-Ho Sung, M.D.\***

*Department of Orthopedic Surgery, Sunlin Hospital, Pohang, Korea.*

Spiral fractures of the middle or distal shaft of the humerus that occur during attempts to throw a variety of objects are not common. Many authors have reported that the cause of fracture was the results of uncoordinated muscle violence.

We experienced two cases of throwing fractures of humerus, one is baseball player(catcher) preceded by arm pain during throwing motion, the other is recreational hand grenade player without prodromal arm pain.

**Key Words** : Throwing Fracture, Humerus

#### Address reprint requests to

Jin-Woo Kwon

#69-7 Daeshin-Dong, Pook-Ku, Pohang, Kyungpook, Sunlin Hospital

Tel : (054) 245-5162

Fax : (054) 245-5311

E-mail : orthokwon @hanmail.net.