



13, 4, 2000 10

The Journal of the Korean Society of Fractures
Vol.13, No.4, October, 2000

-

-

. . .

< >

:

.

: 1993 4 1998 11

16, 16

40.4

(1)

(2)

, ,

가

:

20.6 (13 -30) .

20.8 ,

18.3 .

7 , 6 , 3 .

1 20.4 , 2 19.8

1 2 , 2 2 .

1 5 , 2 3 .

1 3 , 3 , 2

2 4 , 3 , 1 .

:

: ,

:

264

Tel : (062) 650-506

Fax : (062) 650-5066

E-mail : chang221@chollian.net

*

43



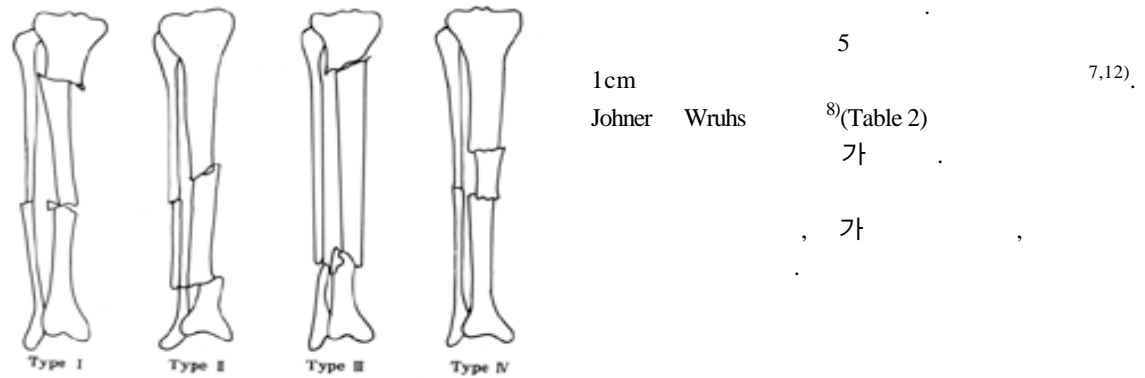


Fig 1. Schematic figures of each type of segmental fractures.

20.6 (13 -30) .

1 , Type , 2 . 20.8 , 18.3 .4

1 8 48.4 가6 , 가 , , 가

2 2 . 2 8 4 가

40.5 4 . 8 3

5 , 3

가 4 가2

5 가 2.5cm 가1 (Table 1).

가 7 , 6 , 3 .

Table 2. Functional assessment(by Johner R and Wruhs D)

	Excellent(Left=Right)	Good	Fair	Poor
Nonunion, osteitis, amputation	None	None	None	Yes
Neurovascular disturbances	None	Minimal	Moderate	Severe
Deformity				
Varus/Valgus	None	2°-5°	6°-10°	10°
Anteversion/ Recurvation	0°-5°	6°-10°	11°-20°	20°
Rotation	0°-5°	6°-10°	11°-20°	20°
Shortening	0-5mm	6-10mm	11-20mm	20mm
Mobility				
Knee	Normal	80%	75%	75%
Ankle	Normal	75%	50%	50%
Subtalar Joint	75%	50%	50%	
Pain	None	Occasional	Moderate	Severe
Gait	Normal	Normal	Insignificant Limp	Significant Limp
Strenuous activities	Possible	Limited	Severly Limited	Impossible

**Table 3.** Comparison of the result between Group I and Group II

	Group I	(N=8)	Group II	(N=8)
Gender	M:6	F:2	M:8	F:0
Age		47.3		40.5
Open Fx		2		4
Duration of F/U(m)		42.3		37.8
Malalignment		5		3
Additional procedure		2		2
Union of time(avr [*] ,wks [†])		20.4		19.8
Functional result				
Excellent		3		4
Good		3		3
Fair		2		1
Poor		0		0

*: avr: average

† wks: weeks

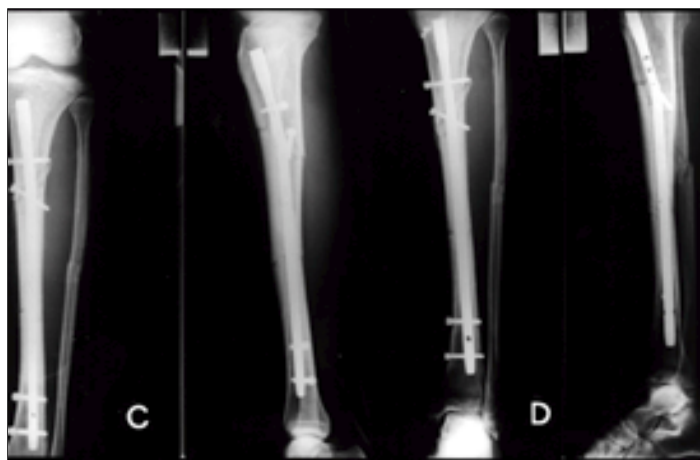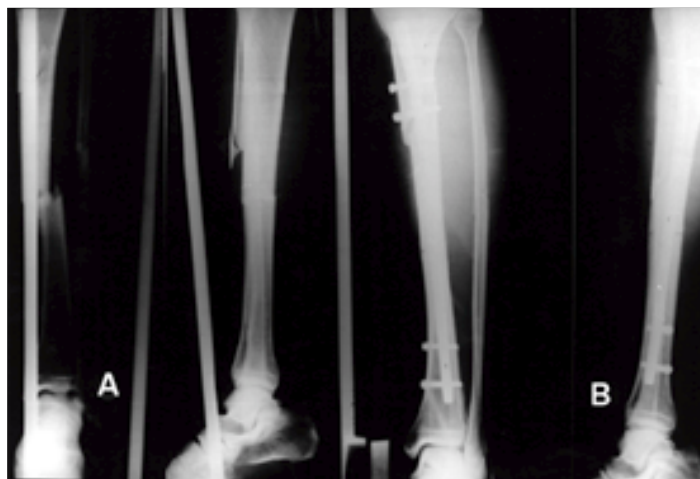


Fig 2A,B. A 61-year-old man with Melis type I was treated with interlocking intramedullary nailing.

2C. Radiograph shows additional procedure with bone graft and screw fixation.

2D. Radiograph shows bony union 14 weeks after operation.



2

1 20.4 , 2 19.8 가

1 2 , 2 2 . 14 . Johner

1 5 , 2 3 . Wruhs

1 3 , 3 , 2 2 (Fig.2-A,B,C,D).

4 , 3 , 1 (Table 3).

2

31 Melis 4

a

12

26

(Fig. 3-

1 A,B,C,D).

61 Melis 1

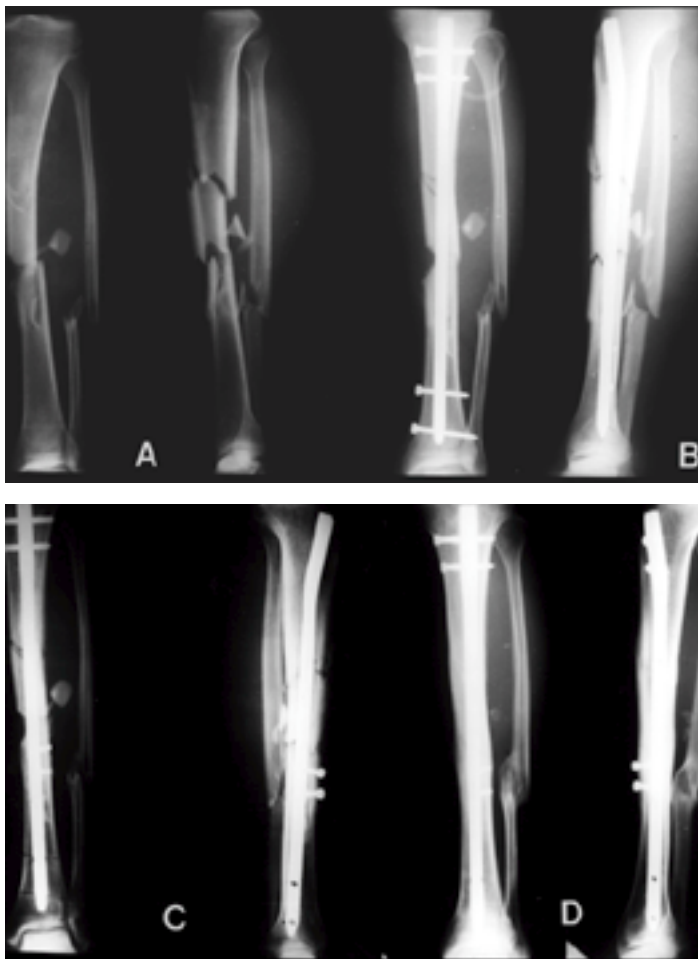
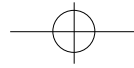


Fig 3A,B. A 31-year-old man with Melis type was open type a fracture.

3B. Radiograph shows additional procedure with bone graft and screw fixation in 12 weeks.

3C. Radiograph shows bony union. 26 weeks after operation.



3
65
Melis 1

4

8

12

. 1

26

(Fig. 4-A,B,C,D).

가

가

가
1,11)

1,11)

16)

. Lang 11)

1/3

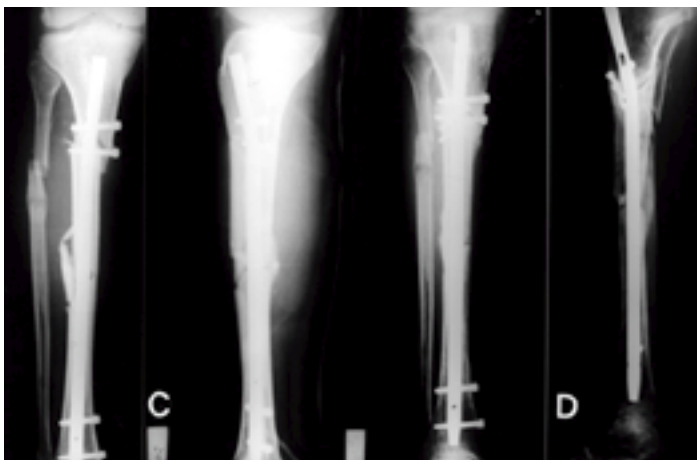
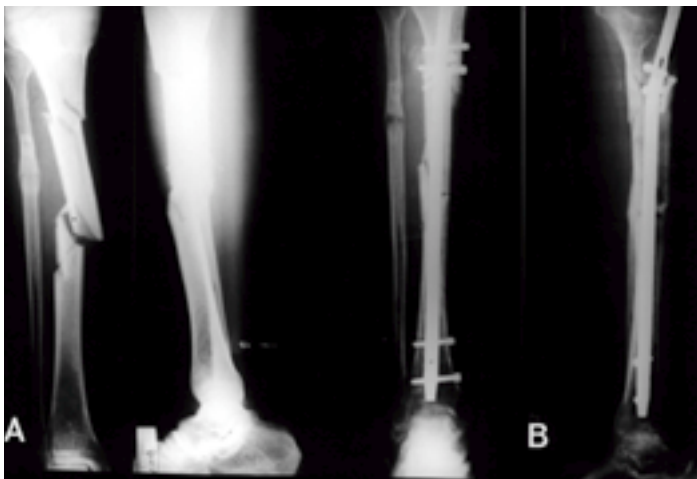

Fig 4A,B. A 65-year-old man with Melis type was treated with interlocking intramedullary nailing
4B. Radiograph shows additional procedure with bone graft and screw fixation in 12 weeks after operation.
4C. Radiograph shows bony union in 26 weeks after operation.



918 • / 13 4

가 59% 가
84% 가
가 16 8 가 1
2
가
가
가
Freedman 1
Johnson⁴⁾
가 가
가
가 가
가 가 8
5 8
3
가
가

Lang ¹¹⁾ Benirschke ¹⁾

4

. 1

REFERENCES

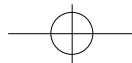
가

가

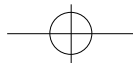
가

1) **Benirschke SK, Henley MB and Ott JW** : Proximal one-third tibial fracture solutions. *Orthop Trans*, 18 : 1055-1056, 1995.

2) **Bone LB and Johnson KD** : Treatment of tibial fractures by reaming and intramedullary nailing. *J*



- Bone Joint Surg*, 68-A : 877-887, 1986.
- 3) **Collins DN, Pearce CE and McAndrew MP** : Successful use of reaming and intramedullary nailing of the tibia. *J Orthop Trauma*, 4 : 315-322, 1990.
 - 4) **Freedman E and Johnson E** : Radiographic analysis of tibial fracture malalignment following intramedullary nailing. *Clin Orthop*, 315 : 25-33, 1995.
 - 5) **Greitbauer M, Heinz T, Gaebler C, Stoik W and Vecsei V** : Unreamed nailing of tibial fractures with the solid tibial nail. *Clin Orthop*, 350 : 105-114, 1998.
 - 6) **Gustilo RB** : Current concept in the management of open fracture. *Instr course Lect*, 36 : 359-366, 1987.
 - 7) **Helfet DL, Jupiter JB and Gasser S** : Indirect reduction and tension-band plating of tibial non-union with deformity. *J Bone Joint Surg*, 74-A : 1286-1297, 1992.
 - 8) **Johner R and Wruhs D** : Classification of tibia shaft fractures and correlation with results after rigid internal fixation. *Clin Orthop*, 178 : 7-25, 1983.
 - 9) **Johnson KD** : Indication, instrumentation, and experience with locked tibial nails. *Orthopedics*, 8 : 1377-1383, 1985.
 - 10) **Klemm KW and B rner M** : Interlocking nailing of complex fractures of the femur and tibia. *Clin Orthop*, 212 : 89-100, 1986.
 - 11) **Lang GJ, Cohen BE, Bosse MJ and Kellam JF** : Proximal third tibial shaft fractures. Should they be nailed? *Clin Orthop*, 315 : 64-74, 1995.
 - 12) **Melis GC, Sotgiu F, Lepori M and Guido P** : Intramedullary nailing in segmental tibial fractures. *J Bone Joint Surg*, 63-A : 1310-1318, 1981.
 - 13) **Nelson GE, Kelly PJ, Peterson LFA and Janes JM** : Blood supply of the human tibia. *J Bone Joint Surg*, 42-A : 625-635, 1960.
 - 14) **Olerud S and Karlstrom G** : The spectrum of intramedullary nailing of tibial fractures. *Clin Orthop*, 212 : 101-112, 1986.
 - 15) **Sarmiento A, Gersten LM, Sobol PA, Shankwiler JA and Vangsness CT** : Tibial shaft fractures treated with functional braces, experience with 780 fractures. *J Bone Joint Surg*, 71-B : 602-609, 1989.
 - 16) **Sarmiento A, Sharpe FE, Ebramzadeh E, Normand P and Shankwiler J** : Factors influencing the outcome of closed tibial fractures treated with functional bracing. *Clin Orthop*, 315 : 8-24, 1995.
 - 17) **Whittle AP, Russel TA, Taylor JC and Lavelle DG** : Treatment of open fractures of the tibial shaft with the use of interlocking nailing without reaming. *J Bone Joint Surg*, 74-A : 1162-1171, 1992.



Abstract

Interlocking Nailing in Segmental Tibial Fractures -The Problems of the Fractures involving Proximal Portion-

Ki Soo Kim,M.D., June Young Song,M.D.,
Kwang Soo Shon,M.D., and Joon Han Kim,M.D.

Department of Orthopedic Surgery, Kwangju Christian Hospital, Kwangju, Korea

Purpose : To analyze the clinical features and treatment results of the tibial segmental fractures with the interlocking nailing. To compare the results between the segmental fractures with (Group) or without (Group) involving proximal portion of the tibia.

Materials and Methods : We analyzed 16 patients, 16 cases of the tibial segmental fractures treated with the interlocking nailing between April 1993 and November 1998.

Results : We obtained solid bone union for all cases and relatively good clinical results. The average bone union time was 20.6 weeks. The functional results were excellent in 7 cases, good in 6 cases and fair in 3 cases. There were 8 cases of malunion. The comparison between Group and Group revealed no remarkable differences for bone union time, functional results and complications. But the tendency of the malunion was more higher in Group .

Conclusion : For segmental tibial fractures, interlocking nailing showed good clinical results. We propose that open reduction and internal fixation should be done before interlocking nailing of the fractures involving proximal portion of the tibia.

Key Words : Tibial segmental fractures, Interlocking Nailing

Address reprint requests to _____

June-Young Song

Department of Orthopaedic Surgery, Kwangju Christian Hospital

264, Yanglim-dong, Nam-ku, Kwangju, Korea

Tel : +82.62-650-5064

Fax : +82.62-650-5066

E-mail : chang221@chollian.net