



13, 4, 2000 10

The Journal of the Korean Society of Fractures  
Vol.13, No.4, October, 2000

. . . .

&lt; &gt;

:

가

Schatzker

V

7

, VI

15

, VI

가 5

49

가 17

(cannulated screw)

3

1

가

4

:

15.6

4

5

12

3

2

가

18

4.1

120

(

116 )

2

1

가

:

가

:

2가 50


Tel : (053) 420 - 5630

Fax : (053) 422 - 6605

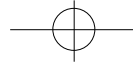




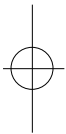
가  
가  
1-2  
2.  
1997 5 1999 2  
22 (21 ) 23  
68 ( 49 ) 가 17  
1 5  
가 16  
6  
Schatzker , V 7 , VI  
15 , VI 가 5  
8 1 1 , 2 2  
3 5 3  
1 9  
Schatzker 6 가  
10 , 3  
가 , Knee Score  
가, 가,  
(cannulated screw) 3 1  
가 10 , 9  
(Dyna-EXTOR, Korea, Fig 1)  
4-6  
15.6 ( 11 , 20  
) 17.7  
( 12 , 22 )  
Schatzker 5 14 , 6 15.2 ,  
19.5 , 4  
3 가  
Knee society clinical rating system<sup>3)</sup>  
가 Knee score 85 5 ,  
가 12 , 3 , 2 ,  
77.2% ,



**Fig 1.** Dyna-EXTOR ; Hybrid external fixator with ring & monolateral fixator

**Table 1.** Rasmussen 's anatomic grading

	Points	Excellent	Good	Fair	Poor
A. Depression					
Not present	6				
< 5 mm	4	6	4	2	0
6 to 10 mm	2				
> 10 mm	0				
B. Condylar widening					
Not present	6				
< 5 mm	4				
6 to 10 mm	2	6	4	2	0
> 10 mm	0				
C. Angulation (valgus/varus)					
Not present	6				
< 10 degrees	4	6	4	2	0
10 to 20 degrees	2				
> 20 degrees	0				
Sum (minimum)		18	12	6	0



Schatzker 6

4.1 , 120 ( 116 ) .

가 Rasmussen<sup>9)</sup> (Table.1)

8 , 가 10 , 2 , 9

2 , 2 가

3mm

, 5mm 1 ,

가 1

8

4 3 20

Schatzker 6 2 27

, 3

, 1 3b

100

가

가 1 3 16

2

26

Schatzker 6

1

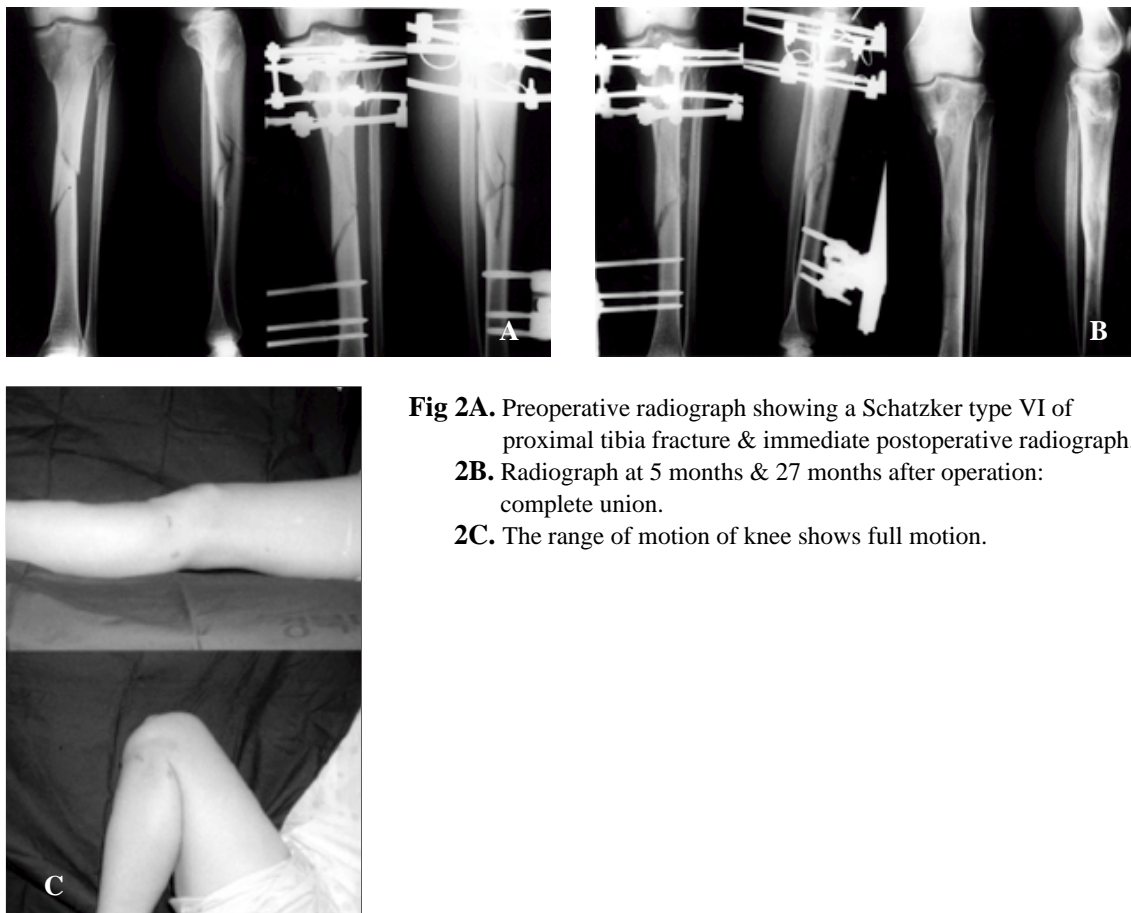
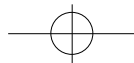
36

knee score

Rasmussen

(Fig 2A,B,C)





3 1  
가

1

6

12

1

5

120

. knee score

85

Rasmussen

6mm

14

(Fig 3A,B,C).

Schatzker 5, 6

가

가

가 ,

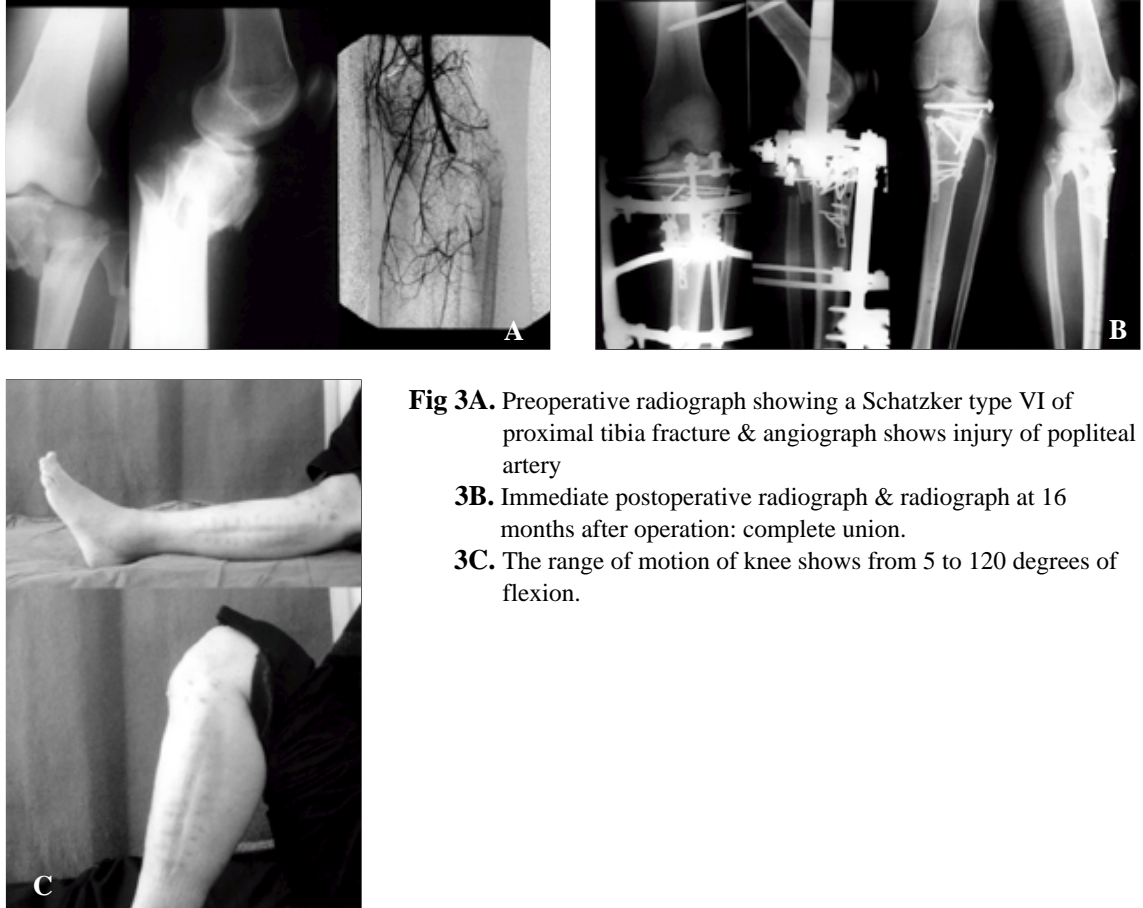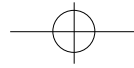
1,2)

가

, 가

, -

11,12,14,15,16)



**Fig 3A.** Preoperative radiograph showing a Schatzker type VI of proximal tibia fracture & angiograph shows injury of popliteal artery  
**3B.** Immediate postoperative radiograph & radiograph at 16 months after operation: complete union.  
**3C.** The range of motion of knee shows from 5 to 120 degrees of flexion.

Stamer <sup>10)</sup>

3b 1

4)

(subchondral bone)

6)

. Pugh <sup>7,8)</sup>  
 (stiffness)

가 <sup>5)</sup>  
 가<sup>13)</sup>

가

(plateau)

Schatzker 6

가

9



Morandi Pearse<sup>5)</sup>  
(ligamentotaxis)

가

가

2

## REFERENCES

- 1) **Brown GA and Sprague BL** : Cast brace treatment of plateau and bicondylar fractures of the proximal tibia. *Clin.Orthop*, 119:184-193, 1976.
- 2) **Decoster TA, Nepola JV and El-Khoury GY** : Cast brace treatment of proximal tibia fractures. ten year follow-up study. *Clin.Orthop*, 231:196-204, 1988.
- 3) **Insall JN, Dorr LD, Scott RD Scott WN** : Rationale of the knee society clinical rating system. *Clin.Orthop*, 248:13-14, 1989.
- 4) **Mallik AR, Covall DJ and Whitelaw GP** : Internal versus external fixation of bicondylar tibial plateau fractures. *Orthop Rev*, 21:1433-1436, 1992.
- 5) **Morandi MM and Pearse MF** : Management of complex tibial plateau fractures with the ilizarov external fixator. *Techniques in Orthopedics*. 11(2):125-131, 1996.
- 6) **Park TW, Cho SD, Kim JJ, Cho YS, Kim BS, Kim GB and Kim KY** : Hybrid external fixation in the treatment of periarticular fractures of tibia. *J of Kor Soc of Fracture*, 34(2):395-401, 1999.
- 7) **Pugh KJ, Wolinsky PR, Dawson JM and Stahlman GC** : The biomechanics of hybrid external fixation. *J Orthop Trauma*, 13(1):20-26, 1999.
- 8) **Pugh KJ, Wolinsky PR, Pienkowski D, Banit D and Dawson JM** : Comparative biomechanics of hybrid external fixation. *J Orthop Trauma*, 13(6):418-425, 1999.
- 9) **Rasmussen PS** : Tibial condylar fractures, impairment of knee joint stability as an indicator for surgical treatment. *J Bone Joint Surg*, 55A:1331-1350, 1973.
- 10) **Stamer DT, Schenk R, Staggers B, Aurori K, Aurori B and Behrens FF** : Bicondylar tibial plateau fractures treated with a hybrid ring external fixator. A preliminary study, *J Orthop Trauma*, 8(6):455-461, 1994.
- 11) **Schatzer J and McBroom R** : The tibial plateau fractures: The Toronto experience. 1968-1975. *Clin Orthop*, 138:94-104, 1979.
- 12) **Suh JT, Lim KS and Yoo CI** : The tibial condylar fractures with dissociation of metaphysis and diaphysis treated by surgical methods. *J Korean Orthop Assoc*, 31(5):1176-1182, 1996.
- 13) **Raikin S and Froimson MI** : Combined limited internal fixation with circular frame external fixation of intra-articular tibial fractures. *Orthopedics*, 22:1019-1025, 1999.
- 14) **Tscherne H and Lobenhoffer P** : Tibial plateau fractures : management and expected results. *Clin Orthop*, 202:87-100, 1993.
- 15) **Yang EC, Weiner L, Strauss E, Sedlin E, Kelley M and Raphael J** : Metaphyseal dissociation fractures of the proximal tibia: an analysis of treatment and complications. *Am J Orthop*, 9:695-704, 1995.
- 16) **Young MJ and Barrack RL** : Complications of internal fixation of tibial plateau fractures. *Orthop Rev*, 149-154, 1994.



## Abstract

## Bicondylar Tibial Plateau Fractures Treated with Hybrid-Ring External Fixator

Chang-Wug Oh, Hee-Soo Kyung, Joo-Chul Ihn,  
Byung-Chul Park, Young-Chul Choi

*Department of Orthopedic Surgery, College of Medicine,  
Kyungpook National University Hospital, Taegu, Korea*

**Purpose** : This study was designed to evaluate the indirect reduction or limited internal fixation with hybrid external fixation for bicondylar fractures of proximal tibia.

**Materials & Methods** : Twenty-two cases (mean age; 49) proximal tibial fractures have been treated, including 7, type V and 15, type VI. After reconstruction of articular surface, the hybrid fixation was applied at the condyle and shaft with or without limited internal fixation by cannulated screw or one-third plate. We permitted early ROM exercise of knee and partial weight-bearing about 4 weeks after operation.

**Results** : Time to union averaged 15.6 weeks(range ; 11-20 weeks). There were 4 cases of nonunion including three cases of early bone graft for severe comminution and one infection. Functional scoring revealed 5 excellent, 12 good, 3 fair and 2 poor results. 18 out of 22 cases had good or excellent result in anatomical grading. The mean range of knee motion was 116 degrees(from 4.1 to 120 degrees). In complications, there were two cases of malunion, one deep infection, and one pin-site infection, but soft tissue compromise such as skin necrosis was not happened.

**Conclusion** : The indirect reduction or limited internal fixation with hybrid external fixation for bicondylar fractures of proximal tibia have advantages of anatomic, stable fixation, early mobilization and less soft tissue dissection, so good results of knee function can be accomplished.

**Key Words** : Proximal tibia, Bicondylar fractures, Hybrid external fixation