

12, 2, 1999 4

The Journal of the Korean Society of Fractures  
Vol.12, No.2, April, 1999

= Abstract =

## Ipsilateral Femoral Shaft and Neck fracture

Dong-Chul Lee, M.D., Yun-Seok Lee, M.D., Duk-Seop Shin, M.D.

*Department of Orthopedic Surgery, College of Medicine,  
Yeungnam University, Taegu, Korea*

The occurrence of ipsilateral hip and femoral shaft fracture is uncommon and this problematic combination occur in 2.5% to 6% of femoral fracture. This combination of fractures result from high energy trauma and occurs in young multiply injured patient. As most orthopedist's attention is directed to the shaft fracture of femur, the neck fracture can be commonly missed initially. Ipsilateral femoral shaft and neck fracture has the characteristics that has multiple associated injuries and many complications, such as avascular necrosis and nonunion of the femur neck, coxa vara. We analysed the outcome of treatment to know the results of treatment and its complication in 10 patients who were treated at Orthopedic Department, Yeungnam University Hospital from May 1991 to May 1996.

The results were as follows:

1. Sixty percent of femoral neck fracture was basicervical type; Ninety percent of femoral shaft fracture occurred in the middle one third and most of the fractures were comminuted. There was one open fracture of femoral shaft.
2. All of the causes of the fractures occurred in motor vehicle accident. Mean age was 40.3 years(range: 15-59 years). There were 24 associated injuries in ten patients: especially, the

:

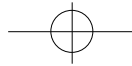
(705-030)

Tel : (053) 620 - 3640 Fax : (053) 628 - 4020

\*

41





injuries around knee were most common(6 tibial condylar fractures, 3 patellar fractures, 1 ligament injuries).

3. The bone union was obtained at average 2.8 months after operation(2 months-5 months) in femur neck fractures, at average 5.8 months after operation(4 months-12 months) in femur shaft fractures and weight bearing was permitted at average 2.3 months after operation(1.5 months-5 months).
4. There were 3 cases of nonunion of femoral shaft fracture, but they were treated by autogenous iliac bone graft. Early bone graft may be necessary in comminuted femoral shaft fracture.

**Key Words** : Femoral shaft and neck fracture, Ipsilateral.

10

, ,

가

가 가 .

,

.

,

1 가 ( 32 : 19 -56 )

10 , 가 9

, 가 1 . 10 50

,

가 . Wolinsky Johnson<sup>23)</sup>

19-30%

4-22%

가

1.

10

7 (70%)가

(dash board injury) 가 , 2 (20%)가

, 1 (10%)가

24 9

(38%) 가 6 ,

3 ,

1 .

(Reconstructive IM nail)

4 ,

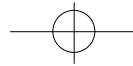
3 , 2 ,

5

, 1 2.4

1991 5 (Table 1).

1996 5



**Table 1.** Associated injury of ipsilateral femoral shaft and neck fracture.

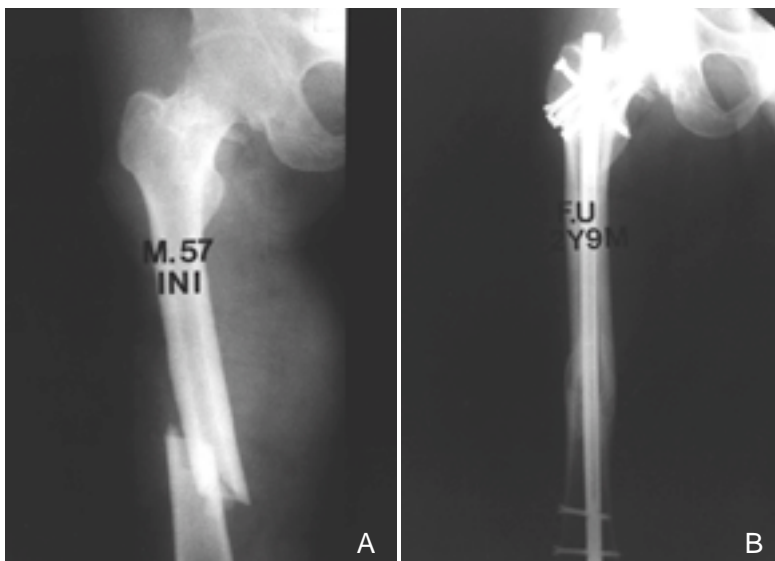
Injury	No. of cases
Craniofacial	2
Abdominal	2
Musculoskeletal	1
Tibial condylar fracture	6
Patellar fracture	3
Foot fracture	1
Contralateral femoral fracture	3
Forearm fracture	3
Wrist fracture	1
Spine fracture	2
Total	24

2.

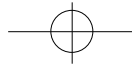
(40%),  
Garden<sup>10)</sup> II 6 (60%), III 4 (40%)  
가  
Pauwels<sup>17)</sup> I 1 (10%), II 6 (60%), III  
3 (30%) (Table 2).  
1/3 가 9 (90%) 가  
, 1/3 가 1 (10%) , Winquist-  
Hansen<sup>22)</sup> I 2 (20%), II 2 (20%), III  
4 (40%), IV 2 (20%)  
, 1 가  
(Table 3).

**Table 2.** Type of femoral neck fracture.

Site	Anatomic	No.(%)	Garden	No.(%)	Pauwels	No.(%)
Neck	Basicervical	6(60)		0		1(10)
	Transcervical	4(40)		6(60)		6(60)
	Subcapital	0		4(40)		3(30)
				0		
	Total	10		10		10



**Fig 1-A.** Initial X-ray of 57 years old male patient showed the comminuted fracture of the femoral shaft (Winquist Hansen type ) and ipsilateral fracture of the femoral neck (Garden type ).  
**B.** The union of fracture of the femoral shaft and neck was shown at postop 2 years and 9 months.



248 • / 12 2

**Table 3.** Type of femoral shaft fracture.

Site	Anatomic	No.(%)	Winqvist-Hansen	No.(%)
Shaft	Proximal	0		2(20)
	Middle	9(90)		2(20)
	Distal	1(10)		4(40)
				2(20)
Total		10		10

**Table 4.** LOM of knee in the patients of injured knee.

Case	Flexion contracture	Further flexion	Injury site
1	10 °	100 °	Tibial condyle fx, & patellar fx.
2	5 °	110 °	Tibial condyle fx.
3	5 °	90 °	Tibial condyle fx, & patellar fx.
4	10 °	80 °	Tibial condyle fx, & patellar fx.
5	0 °	120 °	Tibial condyle fx.
Ave	6 °	100 °	

LOM : Limitation of motion

fx : fracture

3.

10 2

가

14 20

, 8

24

Garden

가

3

(Reconstructive IM nail)

1

가

(cannulated screw)

Hansen 1 , 2

Garden

2

(Fig 1). Winqvist-

(Table 4).

(20 °30 °)가

(60%)

가

3

Garden

(fracture table)

2

, 1

3

Winqvist-Hansen

4

1 (

), 3

, 2

1 (

)

. 2

3

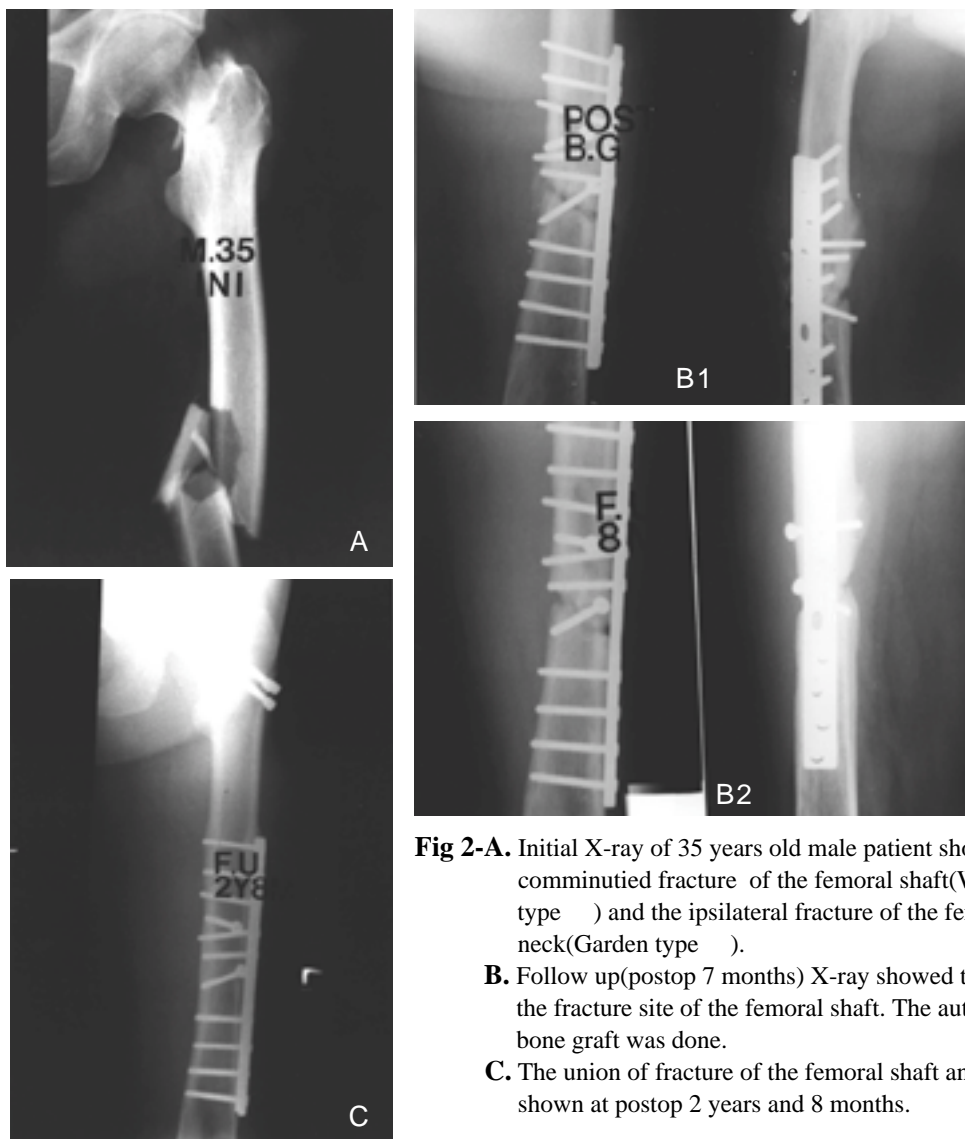
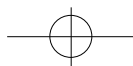
,

1

7

가

(Fig 2).



**Fig 2-A.** Initial X-ray of 35 years old male patient showed the comminuted fracture of the femoral shaft(Winquist Hansen type ) and the ipsilateral fracture of the femoral neck(Garden type ).  
**B.** Follow up(postop 7 months) X-ray showed the nonunion of the fracture site of the femoral shaft. The autogenous iliac bone graft was done.  
**C.** The union of fracture of the femoral shaft and neck was shown at postop 2 years and 8 months.

Delany Street<sup>8)</sup>, Ashby Anderson<sup>4)</sup>

2.5-6%

23)

4-6,14)

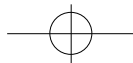
가

1-3,23)

1968 Schazker Barrington<sup>19)</sup>  
Pauwels III

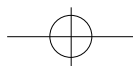
X





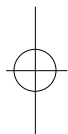
250 • / 12 2

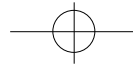
, Friedman  
 , Helal Skevis<sup>13)</sup> Wyman<sup>9)</sup> 14%  
 가 90 57%가 10 8 24  
 , Garden 가  
 , 가  
 19) 2 2  
 , 3 가 ,  
 70% 가  
 , Schatzker Barrington<sup>19)</sup>  
 가 , Johnson<sup>15)</sup> , Bennett <sup>5)</sup>  
 , 16%-59% 가  
 5,7,25) Pauwel Mackenzie<sup>16)</sup> Swiotokowski<sup>20)</sup>  
 1 1 , 2 6 , 3 3 30% 가  
 , Garden 6 (60%) 가  
 가  
 1/3  
 52%-80%가 5,7,24,25) 가 3  
 47%-67% 5,24,25) 가  
 1/3 9 90% 2  
 , 8 (80%) , 1 가  
 20% 40% 가  
 5,6,7,9,25) 가  
 . Casey Chapman<sup>7)</sup> ,  
 가 6 가 ,  
 1 , 2 , 1 , 5  
 가 가 가  
 11) 24 12,18) Geissler 4 22%  
 100% 5,7,20,21),



## REFERENCES

- 가
- 25), 가
- 20,21).
- 1) , : , 28-2 : 705-712, 1993.
- 3 2) , , , : (4 ). , 25-6 : 1674-1680, 1990.
- 3) , , , , : , 29-4 : 1238-1244, 1994.
- 4) **Ashby ME and Anderson JC** : Treatment of the hip and ipsilateral femur with the Zickel device. *Clin Orthop*, 127 : 156-160, 1977.
- 5) **Bennett FS, Zinar DM and Kilgus DJ** : Ipsilateral hip and femoral shaft fractures. *Clin Orthop*, 296 : 168-177, 1993.
- 6) **Bernstein SM** : Fractures of the femoral shaft and associated ipsilateral fractures of the hip. *Orthop Clin N Am*, 5 : 799-818, 1974.
- 7) **Casey MJ and Chapman MW** : Ipsilateral concomitant fractures of the hip and femoral shaft. *J Bone Joint Surg*, 61-A : 503-509, 1979.
- 8) **Delany MW and Street DM** : Fracture of femoral shaft with fracture of neck of same femur : Treatment with medullary nail for shaft and Knowles pins for neck. *J Int Coll Surg*, 19 : 303-312, 1953.
- 9) **Friedman RJ and Wyman ET** : Ipsilateral hip and femoral shaft fractures. *Clin Orthop*, 208 : 188-194, 1986.
- 10) **Garden RS** : The structure and function of the proximal end of the femur. *J Bone Joint Surg*, 43-B : 576-589, 1961.
- 11) **Geissler WB, Savoie FH, Culpepper RD and Hughes JL** : Operative management of ipsilateral fractures of hip and femur. *J Orthop Trauma*, 2 : 297-302, 1988.
- 12) **Goris RJA, Gimbere JSF and Van Nieke JL** : Early osteosynthesis and prophylactic mechanical ventilation in the multiple trauma victim. *J Trauma*,
- 1991 5 1996 5 ( 32 ) 10 . 1. 24 6 , 3 , 1 가 , 1 2.4 . 2. (6 ) 6 1/3 (9 ) , 1 . 3. 2.8 (2 -5 ), 5.8 (4 -12 ) 2.3 (1.5 -5 ) . 4. 3 , 가 . 5. .





- 22 : 895-903, 1982.
- 13) **Helal B and Skevis X** : Unrecognized dislocation of the hip in fracture of the femoral shaft. *J Bone Joint Surg*, 49-B : 293-300, 1967.
  - 14) **Hughes SS, Voit G and Kates SL** : The role of computerized tomography in the diagnosis of an occult femoral neck fracture associated with an ipsilateral femoral shaft fracture : Case report. *J Trauma*, 31 : 296-298, 1991.
  - 15) **Johnson KD** : Femoral shaft fractures. In: Browner BD, Jupiter JB, Levine AM, Trafton PG ed. *Skeletal Trauma*. Vol 2. Philadelphia, WB Saunders : 1560-1564, 1992.
  - 16) **Mackenzie DB** : Simultaneous ipsilateral fracture of the femoral neck and shaft : Report of 8 cases. *South Afr Med J*, 24 : 459-467, 1971.
  - 17) **Pauwels F** : Der schenkenholsbruck, ein mechanisches problem. Grundlagen des heilungsvorganges. Prognose und kausale therapie. *Stuttgart, beilageheft zur zeitschrift fur orthopaedische chirurgie, ferdinand enke*, 1935.
  - 18) **Riska EB, Von Bonsdorff H and Hakkinen S** : Primary operative fixation of long bone fractures in patients with multiple injuries. *J Trauma*, 17 : 111-121, 1977.
  - 19) **Schatzker J and Barrington TW** : Fractures of the femoral neck associated with fractures of the same femoral shaft. *Can J Surg*, 11 : 297-305, 1968.
  - 20) **Swiontkowski MF** : Ipsilateral femoral shaft and hip fractures. *Orthop Clin N Am*, 18 : 73-84, 1987.
  - 21) **Swiontkowski MF, Hansen ST and Kellam J** : Ipsilateral fractures of the femoral neck and shaft. *J Bone Joint Surg*, 66-A : 260-268, 1984.
  - 22) **Winiquist RA, Hansen STJ** : Comminuted fractures of the femoral shaft treated by intramedullary nailing. *Orthop Clin N Am*, 11 : 633-647, 1980.
  - 23) **Wolinsky PR and Johnson KD** : Ipsilateral femoral neck and shaft fractures. *Clin Orthop*, 318 : 81-90, 1995.
  - 24) **Wu CC, Shih CH** : Ipsilateral femoral neck and shaft fractures. *Acta Orthop Scand*, 62 : 346-351, 1991.
  - 25) **Zetts JP and Zettas P** : Ipsilateral fractures of the femoral neck and shaft. *Clin Orthop*, 160 : 63-73, 1981.

