

## Remote Cerebellar Hemorrhage due to Cerebrospinal Fluid Leakage or Meningitis after Spinal Surgery - Case Report -

Sang Hun Ko, M.D., Jae-Ryong Cha, M.D., Hang Ki Kang, M.D., Sung Do Cho, M.D.,  
Kwang Hwan Jung, M.D., Chae Chil Lee, M.D., Yun Suck Yeom, M.D., Sang Woo Kim, M.D.

J Korean Soc Spine Surg 2016 Mar;23(1):31-35.

Originally published online March 31, 2016;

<http://dx.doi.org/10.4184/jkss.2016.23.1.31>

**Korean Society of Spine Surgery**

Department of Orthopedic Surgery, Gangnam Severance Spine Hospital, Yonsei University College of Medicine,  
211 Eunju-ro, Gangnam-gu, Seoul, 06273, Korea Tel: 82-2-2019-3413 Fax: 82-2-573-5393

©Copyright 2016 Korean Society of Spine Surgery

pISSN 2093-4378 eISSN 2093-4386

The online version of this article, along with updated information and services, is  
located on the World Wide Web at:

<http://www.krspine.org/DOIx.php?id=10.4184/jkss.2016.23.1.31>

---

This is an Open Access article distributed under the terms of the Creative Commons Attribution Non-Commercial License (<http://creativecommons.org/licenses/by-nc/4.0>) which permits unrestricted non-commercial use, distribution, and reproduction in any medium, provided the original work is properly cited.

# Remote Cerebellar Hemorrhage due to Cerebrospinal Fluid Leakage or Meningitis after Spinal Surgery - Case Report -

Sang Hun Ko, M.D., Jae-Ryong Cha, M.D., Hang Ki Kang, M.D., Sung Do Cho, M.D., Kwang Hwan Jung, M.D., Chae Chil Lee, M.D., Yun Suck Yeom, M.D., Sang Woo Kim, M.D.  
*Department of Orthopedic Surgery, Ulsan University Hospital, College of Medicine, Ulsan University*

**Study Design:** A case report.

**Objectives:** To report a rare case of remote cerebellar hemorrhage (RCH) as a complication of spinal surgery.

**Summary of Literature Review:** Remote cerebellar hemorrhage is rare but lethal as a complication of spinal surgery. Interestingly, dural tears and cerebrospinal fluid (CSF) leakage are reported in all published cases of RCH.

**Materials and Methods:** A 67-year-old man had posterior lumbar decompression and posterolateral fusion for spinal stenosis at L4/5/S1. Intraoperatively, the dura was torn and there was a loss of CSF. The dural tear was sutured immediately in a water-tight manner. After surgery, the patient complained of headache and dizziness. On postoperative day 44, brain magnetic resonance imaging (MRI) showed meningeal enhancement suggesting meningitis. On postoperative day 54, brain computed tomography (CT) showed cerebellar edema and hemorrhage, and external ventricular derivation was performed.

**Results:** The patient died.

**Conclusions:** Special attention should be paid to prevent dural damage during spinal surgery or minimize CSF leakage in the case of dural damage and tears during spinal surgery, and CT and MRI should be promptly performed for symptomatic patients.

**Key Words:** Complication, Spinal surgery, Remote cerebellar hemorrhage, Cerebrospinal fluid, Dural tear, Meningitis

The majority of surgical complications after spinal surgery are associated with implant related infection, wound infection, neurological complications, epidural hematoma but meningitis, extradural abscess or dural tears are rare. The frequency of dural tears during spinal surgery is reported to be 3.5~ 17.4%.<sup>1)</sup> Remote cerebellar hemorrhage (RCH) after spinal surgery is a rare complication, with a prevalence of 0.08%,<sup>2)</sup> yet is fatal. Interestingly, dural tears and CSF leakage are reported in all published cases of RCH.<sup>3)</sup> Although CSF leakage plays an important role in the development of RCH, its pathophysiology has not yet been clearly established.<sup>4)</sup> Herein, we report a 67 year old male patient who expired due to RCH or meningitis caused by dural tears during lumbosacral surgery and secondary CSF leakage with literature review.

## Case report

A 67 year old man presented with low back pain and gradu-

ally aggravated paresthesia of left leg caused by spinal stenosis (the fourth and fifth lumbar, the fifth lumbar and the first sacrum). He reported that the symptoms started 1 year ago and he had underwent discectomy (the fifth lumbar and the first sacrum) 10 year ago and vertebroplasty (the second lumbar) 2 years ago. His medical history was unremarkable and he denied hypertension, diabetes mellitus, trauma and coagulation disorders. We performed decompression and posterolateral fusion (the fourth

**Received:** March 13, 2015

**Revised:** July 09, 2015

**Accepted:** September 08, 2015

**Published Online:** March 31, 2016

**Corresponding author:** Jae-Ryong Cha, M.D.

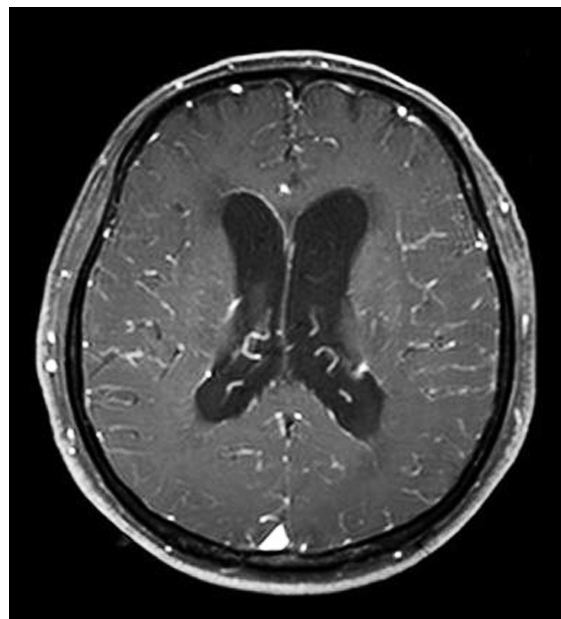
Department of Orthopedic Surgery, Ulsan University Hospital, College of Medicine, Ulsan University, 877, Bangeojinsunhwando-ro, Dong-gu, Ulsan 682-714, Korea

**TEL:** +82-52-250-7129, **FAX:** +82-52-235-2823

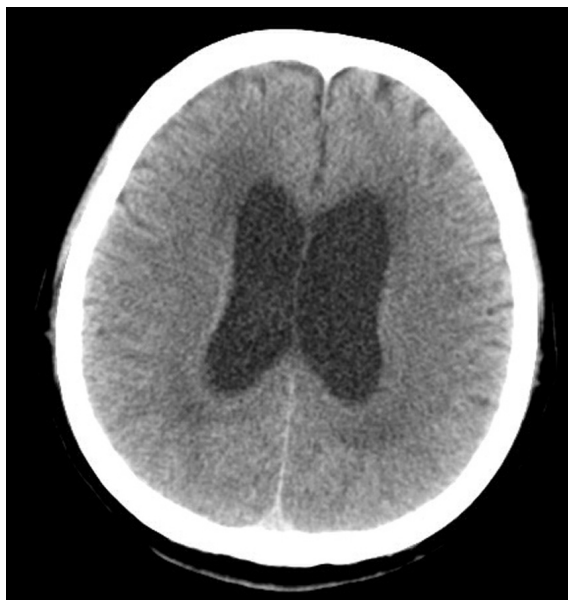
**E-mail:** jrcha@uuh.ulsan.kr

lumbar ~ the first sacrum). Due to previous surgery, there was dural adhesion and unintentional dural tear and CSF leakage occurred during surgery. Dural tear was sutured immediately in water-tight fashion and a drain was inserted to the subfascial space. Otherwise, surgery was uneventful and the patient was well recovered from anesthesia. After the surgery, serosanguineous fluid including cerebrospinal fluid came out through the drain. The drainage volume was gradually reduced and the drain was removed on the 8<sup>th</sup> day after the surgery. However, serosanguineous ooze including CSF was persistent from the drain removal site until the 22<sup>nd</sup> day. Five to ten gauzes (10 cm × 7.5 cm) were soaked everyday and the patient complained of a headache and dizziness. The exudates gradually reduced and the ooze stopped from the drain removal site on the 25<sup>th</sup> day. The wound was healing well and headache and dizziness also improved. He was discharged from the hospital on the 30<sup>th</sup> day. Yet, headache and dizziness came back after the discharge and he came to the emergency department presenting with fever, headache, altered level of consciousness and slurred speech on the 44<sup>th</sup> day after the surgery. Glasgow comma scale score on the arrival was 8. A brain CT was immediately performed and revealed ventriculomegaly (Fig. 1). A brain MRI showed meningeal enhancement suggesting meningitis (Fig. 2). A lumbar MRI showed fluid collection in the lumbosacral region, the operation site (Fig. 3). Blood test results showed elevated white blood cell (WBC) (17990

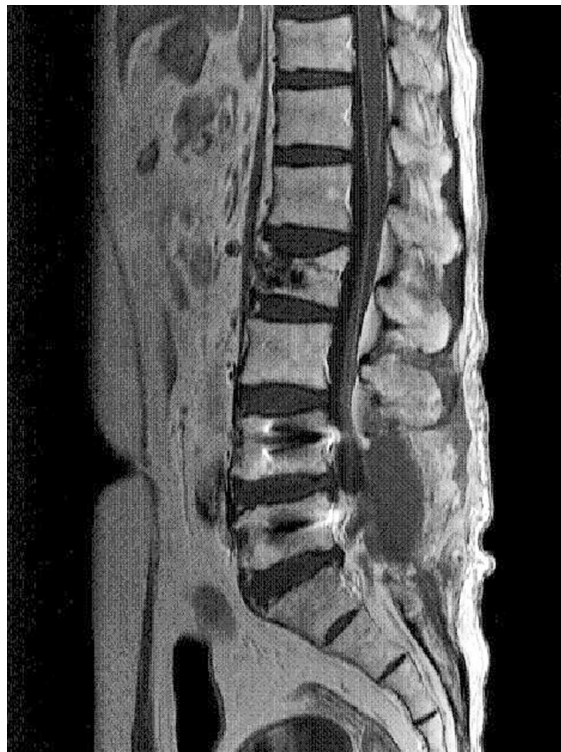/ul), elevated C-reactive protein (3.348 mg/dl). CSF test results showed elevated WBC (880 /ul), neutrophil and protein (213.2



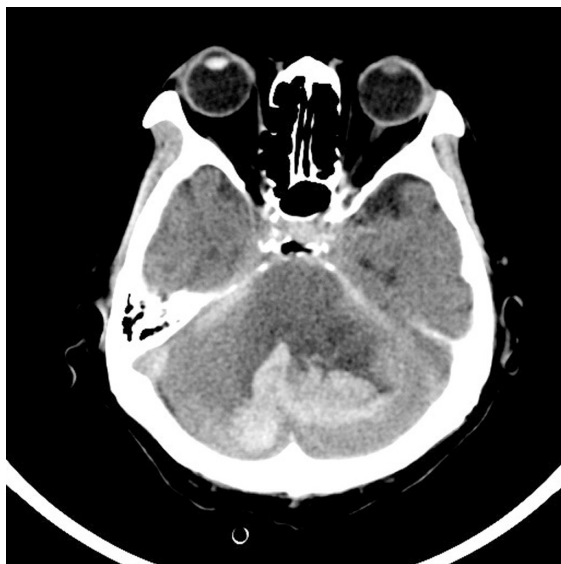**Fig. 2.** Magnetic resonance imaging (MRI) findings for the brain (axial Gd-enhanced T1): Prominent enhancement of meninges and moderate ventriculomegaly.



**Fig. 1.** Computed tomography (CT) findings for the brain: Moderate ventriculomegaly.



**Fig. 3.** MRI findings for the lumbar spine (sagittal Gd-enhanced T1): Fluid collection at the laminectomy site and around the fixators.



**Fig. 4.** CT findings for the brain: Acute cerebellar hemorrhage with diffuse parenchymal swelling in both cerebellar hemispheres.

mg/dl), reduced CSF glucose/ blood glucose ratio (29/144). Based on the imaging study results and laboratory results, meningitis was suspected and the patient was admitted to the intensive care unit (ICU) then antibiotic therapy was commenced. CSF culture was requested but there was no growth. On the following day of the admission, incision & drainage was performed to drain the fluid in the lumbosacral region and a drain was inserted. Fluid culture was requested with the drainage but there was no growth. After the treatment, the level of consciousness and symptoms seemed to improve but dyspnea was developed and he became comatose on the 54<sup>th</sup> day after the surgery (the 11<sup>th</sup> day of re-admission). Brain CT showed cerebellar edema and hemorrhage (Fig. 4). External ventricular derivation was performed as an emergency operation for decompression and he was cared in the ICU. However, his vital signs were unstable and he remained comatose and finally expired after 23 days after the operation.

## Discussion

Most of spontaneous intracranial hemorrhages before and after surgery are associated with use of anti-coagulant drugs, high arterial blood pressure, intracranial vascular malformation and neck vein obstruction due to excessive rotation. However, some reported that CSF leakage after dural tears may cause

intracranial hemorrhage after spinal surgeries.<sup>4)</sup> The frequency of dural tears during spinal surgery is reported to be 3.5~ 17.4%.<sup>1)</sup> RCH after spinal surgery was first reported by Chaddock<sup>5)</sup> in 1981 and, in all published cases of RCH to date, RCH was associated with neurologic symptoms caused by dural tears and leakage of CSF.<sup>6)</sup>

According to the literature, RCH can occur after any types of spinal surgeries if CSF leakage can develop during surgery or after surgery regardless age, sex and the causes of diseases.<sup>6)</sup> Although the underlying pathophysiology of RCH is not yet clear, most theories seem to be related with two facts. RCH is resulted from CSF loss during and after surgery and is venous origin.<sup>7)</sup> The assumption that RCH is venous in origin is supported by the evidence that arterial hemorrhage occurs unilaterally while RCH occurs bilaterally in the cerebellar sulci and cerebellar vermis, where the cerebellar draining veins are located. The assumption that CSF leakage during surgery or after surgery causes RCH is supported by the published case reports in which CSF leakage was associated with the development of RCH.<sup>3)</sup> The development of RCH is extremely rare in patients who underwent lumbar puncture where loss of CSF is small in volume and low in speed. For the development of RCH, rapid and large amount of CSF leakage should be preceded. Some authors maintained that rapid leakage of large amount of CSF induces sagging of cerebellum.<sup>7)</sup> The cerebellar sag can cause arterial infarction or venous occlusion and lead to reperfusion hemorrhage or venous hemorrhage secondary to elevated venous pressure.<sup>7)</sup> Although most authors agree upon the view that rapid leakage of a large amount of CSF should be preceded, this is controversial because RCH has been reported after lumbar puncture in two cases<sup>8)</sup> and the volumes of CSF loss were not measured in most cases.

This complication can be immediately detected by brain CT or brain MRI. According to Brockmann,<sup>9)</sup> RCH is bilaterally seen in the upper portion of the cerebellar vermis and folia of cerebellar where venous origin of hemorrhage is seen. The bleeding is shown as clear curvy patterns including alternative high density area (blood) and low density area (cerebellum) on imaging studies and this typical pattern is described as 'zebra sign'. Since 'zebra sign' is considered to be typically seen after post-operative CSF leakage, CSF leakage should be considered when this pattern is shown on imaging studies.

RCH can be asymptomatic and be accidentally found by



imaging studies. RCH can cause dizziness, headache, non-specific neurologic symptoms, cerebellar abnormality and even death.<sup>3)</sup> In general, small amount of bleeding responds well to conservative treatment with close observation by serial imaging studies. Nevertheless, large amount of hemorrhage requires immediate surgical decompression due to a high risk of acute obstructive hydrocephalus and brain stem compression.<sup>2, 6)</sup> CSF diversion is required if compression of the fourth ventricle and secondary non-communicating hydrocephalus are developed.<sup>6)</sup> In case of large amount of hemorrhage, satisfactory outcomes such as full recovery or mild neurologic symptoms are reported in more than 50% of the cases and death was reported in 10~15% of the cases.<sup>10)</sup>

Similar to previous reports, unintentional dural tears and CSF leakage also occurred in our case. Despite of the immediate suture, CSF was leaked through the drain. The patient initially complained of dizziness and mild headache but the symptoms were alleviated. However, meningitis accompanied with fever, headache, altered level of consciousness was developed and antibiotic therapy was commenced. During antibiotic therapy, RCH was developed on the 54<sup>th</sup> day after the surgery (the 10<sup>th</sup> day of re-admission) and external ventricular derivation was performed for decompression but he expired.

In previous reports, RCH after spinal surgery was immediate perioperative complication. But in our case, RCH was developed on the 54<sup>th</sup> day after the surgery with history of meningitis. Cerebellar hemorrhage was reported as a complication of meningitis but was not reported as a complication of meningitis after spinal surgery. So, the cause of RCH was unclear whether CSF leakage or meningitis in our case.

The outcome of RCH after spinal surgery is generally satisfactory but we must bear in mind that RCH can be fatal in patients with altered level of consciousness, headache, dizziness and non-specific symptoms to cerebellar or cerebral lesions. Thus, special attention should be paid to prevent dural damage during spinal surgery or minimize CSF leakage when there are

dural damages and tears during spinal surgery, and CT and MRI should be promptly performed for symptomatic patients.

## REFERENCES

1. Tafazal SI, Sell PJ. Incidental durotomy in lumbar spine surgery: incidence and management. *Eur Spine J*. 2005;14:287-90.
2. Castle M, Barrena C, Sampron N, et al. [Remote cerebellar haemorrhage after lumbar arthrodesis: case report and literature review]. *Neurocirugia (Astur)*. 2011;22:574-8.
3. Ulivieri S, Neri L, Oliveri G. Remote cerebellar haematomas after lumbar disc surgery. Case report. *Ann Ital Chir*. 2009;80:219-20.
4. Lee HY, Kim SH, So KY. Seizure and delayed emergence from anesthesia resulting from remote cerebellar hemorrhage after lumbar spine surgery -A case report. *Korean J Anesthesiol*. 2012;63:270-3.
5. Chadduck WM. Cerebellar hemorrhage complicating cervical laminectomy. *Neurosurgery*. 1981;9:185-9.
6. Konya D, Ozgen S, Pamir MN. Cerebellar hemorrhage after spinal surgery: case report and review of the literature. *Eur Spine J*. 2006;15:95-9.
7. Friedman JA, Ecker RD, Piepgras DG, et al. Cerebellar hemorrhage after spinal surgery: report of two cases and literature review. *Neurosurgery*. 2002;50:1361-3.
8. Bernal-Garcia LM, Cabezudo-Artero JM, Ortega-Martinez M, et al. [Remote cerebellar hemorrhage after lumbar spinal fluid drainage. Report of two cases and literature review]. *Neurocirugia (Astur)*. 2008;19:440-5.
9. Brockmann MA, Nowak G, Reusche E, et al. Zebra sign: cerebellar bleeding pattern characteristic of cerebrospinal fluid loss. Case report. *J Neurosurg*. 2005;102:1159-62.
10. Gul S, Kalayci M, Acikgoz B. A rare complication of spinal surgery: cerebellar hemorrhage. *Turk Neurosurg*. 2010;20:413-7.

## 척추 수술 후 뇌척수액 소실 혹은 뇌수막염에 의한 원격성 소뇌 출혈 - 증례 보고 -

고상훈 · 차재룡 · 강항기 · 조성도 · 정광환 · 이채철 · 염윤석 · 김상우

울산대학교 의과대학 울산대학교병원 정형외과학교실

**연구 계획:** 증례 보고

**목적:** 척추 수술의 합병증으로 발생한 원격성 소뇌 출혈에 대하여 보고한다.

**선행 문헌의 요약:** 척추 수술 후 발생하는 원격성 소뇌 출혈은 드물지만 치명적인 합병증이다. 흥미롭게도 문헌에서 보고된 모든 예에서 경막 파열과 뇌척수액 누출이 보고되었다.

**대상 및 방법:** 67세 남자가 요추 4, 5번, 천추 1번 감압술 및 후외방 유합술을 시행받았다. 수술 과정 중에 경막 손상과 뇌척수액 누출이 있었다. 경막 손상은 물이 새지 않는 방법으로 봉합되었다. 수술 후에 환자는 두통과 어지러움을 호소하였다. 수술 후 44일째 뇌 자기 공명 영상 촬영상에서 뇌수막염 소견을 보였고 수술 후 54일째 뇌 전산화 단층 촬영 상에서 소뇌 양측 반구에 실질세포 부종 및 출혈 소견이 나타났고 뇌실외 배액술이 시행되어졌다.

**결과:** 환자는 사망하였다.

**결론:** 척추 수술 중에 경막 파열이 발생하지 않게 하거나 경막 파열이 생겼더라도 뇌척수액 손실이 최소화 되도록 특별한 주의가 필요하며 증상이 있는 환자에서는 전산화 단층 촬영과 자기 공명 영상 촬영이 즉각적으로 시행되어야 한다.

**색인 단어:** 합병증, 척추 수술, 원격성 소뇌 출혈, 뇌척수액, 경막 파열, 뇌수막염

**약칭 제목:** 척추 수술 후 원격성 소뇌 출혈

**접수일:** 2015년 3월 13일    **수정일:** 2015년 7월 9일    **게재확정일:** 2015년 9월 8일

**교신저자:** 차재룡

울산광역시 동구 방어진 순환도로 877 울산대학교 의과대학 울산대학교병원 정형외과학교실

**TEL:** 052-250-7129

**FAX:** 052-235-2823

**E-mail:** jrcha@uuh.ulsan.kr