

Multiple Bilateral Thoracic Perineural Cysts - A Case Report -

Myoung Soo Kim, M.D., Jae Yong Kwak, M.D., Chang Bum Lee, M.D.,
Hyung Taek Park, M.D., Sun Jin Choi, M.D., Jung Min Ha, M.D.

J Korean Soc Spine Surg 2011 Mar;18(1):24-28.

Originally published online March 31, 2011;

doi: 10.4184/jkss.2011.18.1.24

Korean Society of Spine Surgery

Department of Orthopaedic Surgery, Ewha Womans University College of Medicine

#911-1 Mok-dong, Yangcheon-gu, Seoul, 158-710, Korea Tel: 82-2-2646-6808 Fax: 82-2-2646-6804

©Copyright 2011 Korean Society of Spine Surgery

pISSN 2093-4378 eISSN 2093-4386

The online version of this article, along with updated information and services, is
located on the World Wide Web at:

<http://www.krspine.org/DOIx.php?id=10.4184/jkss.2011.18.1.24>

This is an Open Access article distributed under the terms of the Creative Commons Attribution Non-Commercial License (<http://creativecommons.org/licenses/by-nc/3.0>) which permits unrestricted non-commercial use, distribution, and reproduction in any medium, provided the original work is properly cited.

Multiple Bilateral Thoracic Perineural Cysts - A Case Report -

Myoung Soo Kim, M.D., Jae Yong Kwak, M.D., Chang Bum Lee, M.D.,
Hyung Taek Park, M.D., Sun Jin Choi, M.D., Jung Min Ha, M.D.

Department of Orthopaedic Surgery, Maryknoll Hospital, Busan, Korea

Study Design: Case report

Objectives: We report a case of relatively rare multiple bilateral perineural cysts.

Summary of Literature Review: Tarlov cysts, also known as perineural cysts are most often found in the sacral region, but there are a few cases reported in the thoracic region. In particular, there are very few cases of multiple bilateral thoracic perineural cysts.

Materials and Methods: A woman aged 65 years with perineural cysts in the bilateral T10-T11 and T11-12 neural foramina, underwent a T10-11-12 decompressive laminectomy and resection of the cyst.

Results: Satisfactory results were obtained for the patient after surgery.

Conclusions: For more detailed and definitive treatment of thoracic perineural cysts, additional cases are required.

Key Words: Thoracic spine, Multiple bilateral perineural cysts

Tarlov or perineural cysts are lesions of the nerve root most often found in the sacral region. They were first described by Tarlov¹⁾ during autopsy studies of the filum terminale. Although unclear, the etiologies of this disease are assumed to include one of the following: inflammation, arachnoid proliferation, trauma, and developmental or congenital origin.^{2,3)} They are most often found in the sacrum, close to the central canal, at or just distal to the junction of the posterior root and the dorsal root ganglion. The cavities of the cysts lie between the arachnoid and the pia mater of the root. Most of these cysts are asymptomatic and are incidental after analyzing results from imaging.³⁾

In a series of 500 consecutive magnetic resonance imaging (MRI) scans of the lumbosacral spine, Paulsen et al.^{4,5)} recorded an incidence of 4.6%, but the size of the cyst has been known to increase and then cause symptoms in approximately 1% of patients. These cysts are most frequently found in the sacrum, and very rarely, in the thoracic spine.⁶⁾ The authors recently came across a case presenting with multilevel bilateral perineural cysts in the thoracic spine, and experienced definite improvement of symptoms after treatment. This case is reported here with a review of literature.

CASE REPORT

A 65-year-old woman presented with a one-year history of back pain, claudication, hypertension, and hyperlipidemia. She also had a history of sigmoid colon cancer (T2N2M0) and had been treated with low anterior resection. She was admitted to the hospital with complaints of moderate tenderness on the L1 area, with radiation down both legs and flank pain for two weeks. She also complained of difficulty in voiding. A physical

Received: August 23, 2010

Revised: January 25, 2011

Accepted: January 28, 2011

Published Online: March 31, 2011

Corresponding author: Chang Bum Lee, MD.

Department of Orthopaedic Surgery, Maryknoll Hospital, 12, Daechong-Dong 4ga, Jung-Gu, Busan, 600-730, Korea

TEL: 82-51-461-2376, **FAX:** 82-51-463-1194

E-mail: nexgens@hanmail.net

"This is an Open Access article distributed under the terms of the Creative Commons Attribution Non-Commercial License (<http://creativecommons.org/licenses/by-nc/3.0/>) which permits unrestricted non-commercial use, distribution, and reproduction in any medium, provided the original work is properly cited."

examination revealed decreased strength in the left L5 myotome (the extensor hallucis longus). There were no further neurologic deficits on both legs.

Magnetic resonance imaging (MRI) of the thoracic spine showed a round extradural mass at the T11–12 level that compressed the spinal cord posteriorly. This lesion showed an inhomogeneously hypointense signal on the T1-weighted images and a more hypointense signal in the T2-weighted images (Fig. 1). It was thought that this lesion was an ossified ligamentum

flavum. The recent compression fracture of the L1 body and cystic dilatation of the bilateral neural foramen of T10 and T11 were found. The cystic lesion was hyperintense on the T2-weighted image, but was not enhanced after gadolinium injection (Figs. 2 and 3).

It was considered that her bladder dysfunction and radiating pain were due to thecal compression of the ossified ligamentum flavum. Moreover, the biggest cystic lesion at the T10–11 left side was most likely the cause of weakness of the left leg. In

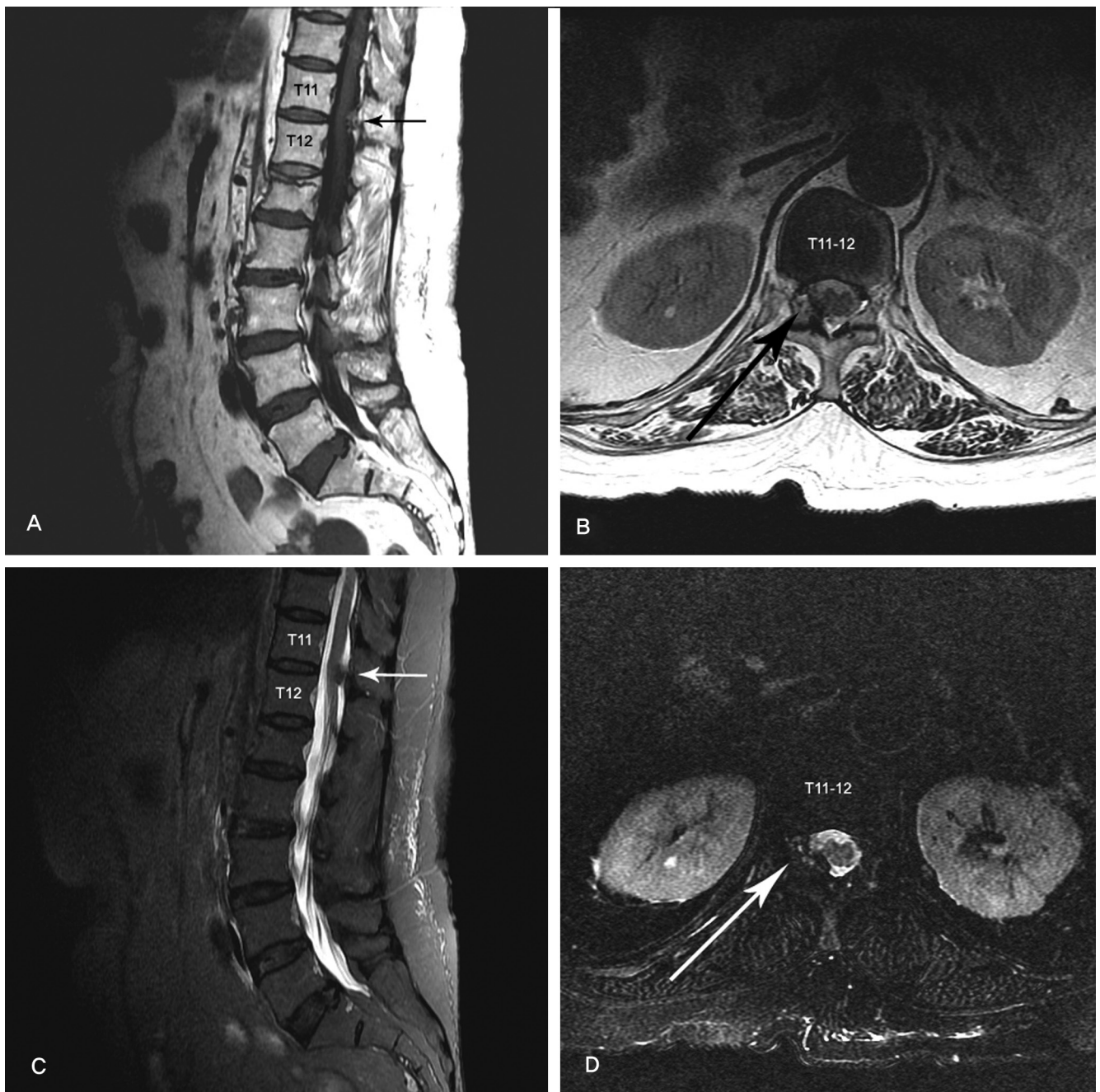


Fig. 1. Magnetic resonance image of the thoracic spine showing a round extradural mass at the T11–12 level. The lesions show an inhomogeneously hypointense signal on the T1-weighted image (**A, B**), and a more hypointense signal on the T2-weighted image (**C, D**).

addition, the L1 area tenderness and flank pain were due to the L1 compression fracture. Therefore, operative decompression, removal of the cystic lesion, and kyphoplasty was decided as the course of action.

A T10–11–12 decompressive laminectomy using a high-speed burr was performed to remove the ossified ligamentum flavum

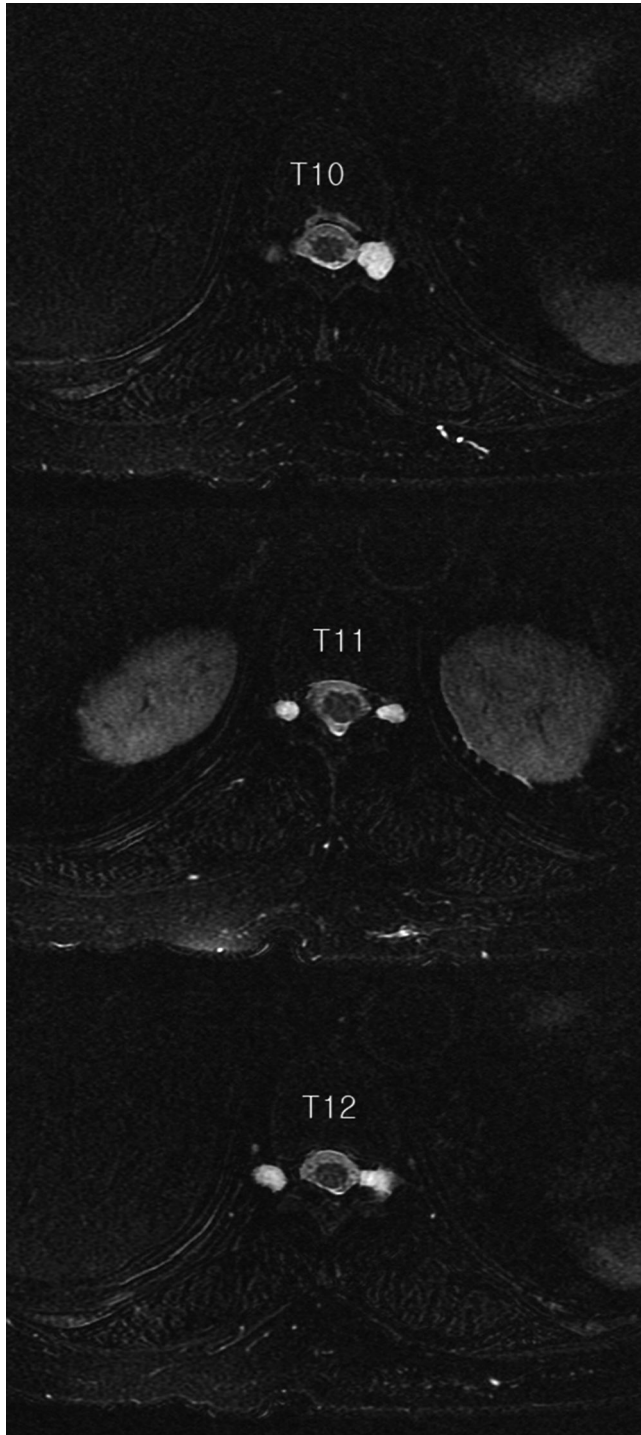


Fig. 2. Axial T2W FAT suppression image that demonstrates large cystic structures in the bilateral T11 and T12 neural foramina.

and the cystic lesion. First, the ossified ligamentum flavum at the right side of T11–12 was removed, and then a single cyst was removed at the left side of T10–11. The presence of a translucent, light-brown 0.8 x 0.8 cm cyst was identified. An incision was made on the cyst and the clear fluid was drained. Despite the absence of active CSF communication between the cyst and the arachnoid space, the defect that resulted from the resection of the cysts was covered using gelfoam and fibrin glue to prevent the possible leakage of CSF. It was observed that there was no CSF leak after the operation. In the histologic study, the cyst was composed of dense collagenous bundles with vascular connective tissue (Fig. 4). However this was not a specific finding of perineural cysts. Finally, L1 kyphoplasty was performed under a C-arm guide. In the follow-up examination,

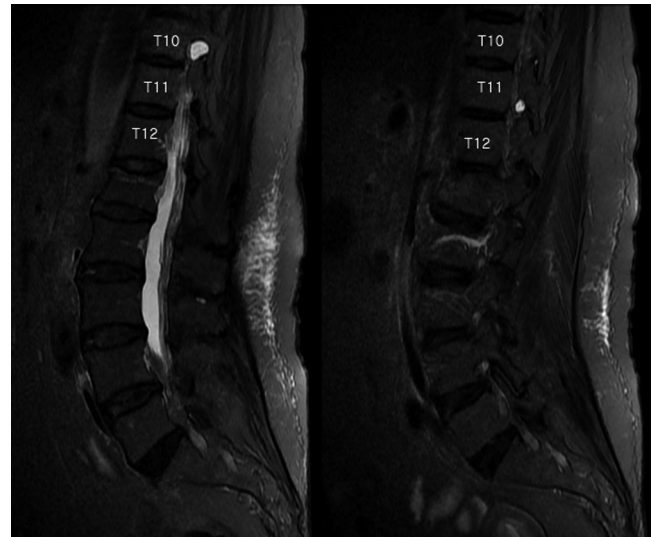


Fig. 3. Sagittal T2W FAT suppression image of the thoracic spine. Large cystic lesions in the T10-T11 and T11-T12 neural foramina.

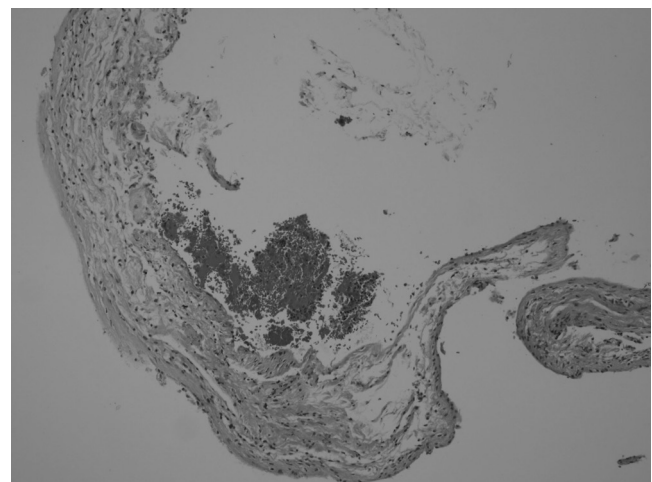


Fig. 4. Photomicrograph showing the irregular cystic wall composed of dense collagenous bundles and vascular connective tissue. (H&E x 100).

the patient continued to feel mild tenderness in the L1 area, but all active root tension signs were negative. The muscle strength of the left L5 myotome (the extensor hallucis longus) improved to 5/5 at the final check-up. The causes of difficulty in voiding, the radiating pain in both lower legs, and the decreased strength in the left L5 myotome were not definitively revealed, but the bladder dysfunction in the immediate post-operative period improved significantly, and other neurologic symptoms progressively improved.

DISCUSSION

In 1938, Tarlov first described cystic lesions in the sacral nerve root and called them "perineural cysts." He found that these cysts were located in the perineural space, between the endoneurium and the perineurium at the junction of the posterior nerve root and its ganglion.¹⁾

Histologic analysis of perineural cysts have shown that the cyst wall is composed of peripheral nerve fibers or ganglionic cells that are covered with meningeal epithelium, and that the communication of the cysts with the cerebrospinal fluid is variable.⁷⁾ The exact mechanism of action is still unclear, but direct mechanical compression seems to be the most likely etiology of the pain.

Several hypotheses have been proposed to explain the etiologies of perineural cysts in the sacral region. Of these, the representative ones include inflammation within the nerve root cysts followed by inoculation of fluid, arachnoidal proliferation along and around the exiting sacral nerve root, breakage of the venous drainage in the perineurium and the epineurium secondary to hemosiderin deposition after trauma, and developmental or congenital origin.^{2,3)}

The management of symptomatic Tarlov cysts is still being debated. When left untreated, symptomatic perineural cysts have been rarely associated with rupture and spontaneous intracranial hypotension.⁸⁾ Surgical excision and laminectomy have shown mixed results. Tanaka et al.⁹⁾ reported long-lasting relief of symptoms in 83% of patients who underwent decompression for sacral perineural cysts. Another case series reported significant, long-lasting relief of symptoms in 50% (four of eight) of patients with symptomatic perineural cysts who had undergone microsurgical cyst fenestration and cyst imbrication.

A third study examined the efficacy of microsurgical excision with duraplasty or plication of the cyst wall in 15 patients with symptomatic sacral perineural cysts; 13 of the 15 patients had significant pain relief. Post-operative pseudomeningocele and intracranial hypotension are common complications.

In the lumbosacral region, the indications of surgical treatment include cases in which the size of a cyst is > 1.5 cm and those in which the radiating pain increases due to postural changes and Valsalva maneuvers.^{3,9)} In cases in which the positive filling defect sign indicates the cyst is not being actively filled with dye and compresses the other roots in myelography, the alleviation of clinical symptoms can be expected following surgical resection of the cyst.^{3,9)} The back pain and radiating pain in the case presented herein were provoked by postural changes and Valsalva maneuvers, and, the symptoms disappeared after surgery. These results were not necessarily due to only the perineural cyst, but because of the combined ossified ligamentum flavum and L1 compression fracture in the case presented herein. Although the authors had experienced a rare case of a thoracic perineural cyst and have reviewed related articles, they could not suggest indications for operation. For more detailed and definitive treatment of thoracic perineural cysts, more experiences and case studies are needed.

Computed-tomography-guided percutaneous aspiration of sacral perineural cysts has limited value. The pain can reemerge within days to weeks, and percutaneous aspirations have also been associated with immediate headache, presumably secondary to intracranial hypotension.¹⁰⁾

In the author's opinion, the most important aspect of the surgical technique is the maintenance of the integrity of the cyst wall until it is fully dissected from surrounding structures. The patient was advised to have bed rest and to lie flat, and was given 250 mg of acetazolamide daily to lessen the chance of pseudomeningocele for three days after surgery. Because of the possibility of delayed complications, the patient was warned that she might experience significant pain for up to several months after the surgery. Fortunately, the symptoms improved significantly, and the bladder dysfunction in the immediate post-operative period normalized.

REFERENCES

1. Tarlov IM. Perineurial cysts of the spinal nerve roots. Arch Neurol Psychiatry. 1938;40:1067-74.
2. Mummaneni PV, Pitts LH, McCormack BM, Corroo JM, Weinstein PR. Microsurgical treatment of symptomatic Tarlov cysts. Neurosurgery. 2000;47:74-9.
3. Voyadzis JM, Bhargava P, Henderson FC. Tarlov cysts: A study of 10 cases with a review of literature. J Neurosurg. 2001;95:25-32.
4. Langdown AJ, Grundy JR, Birch NC. The clinical relevance of Tarlov cysts. J Spinal Disord Tech. 2005;18:29-33.
5. Paulsen RD, Call GA, Murtagh FR. Prevalence and percutaneous drainage of cysts of the sacral nerve root sheath (Tarlov cysts). AJNR Am J Neuroradiol. 1994;15:293-9.
6. Rha JD, Jang YS, Park HS, et al. Perineural cyst in upper lumbar spine: A Case Report. J Korean Soc Spine Surg. 2008;15:199-203.
7. Kato T, Takamura H, Goto S, et al. Sacral perineural cyst: Report of a case. No Shinkei Geka. 1988;16:893-7.
8. Riva-Amarante E, Simal P, San Millán JM, Masjuan J. Spontaneous intracranial hypotension due to a broken dorsal perineural cyst. Neurologia. 2006;21:209-12.
9. Tanaka M, Nakahara S, Ito Y, et al. Surgical results of sacral perineural (Tarlov) cysts. Acta Med Okayama. 2006;60:65-70.
10. Lee JY, Impekoven P, Stenzel W, et al. CT-guided percutaneous aspiration of Tarlov cyst as a useful diagnostic procedure prior to operative intervention. Acta Neurochir (Wien). 2004;146:667-70.

다발성 양측성 흉추 신경초 낭종 - 증례 보고 -

김명수 • 곽재용 • 이창범 • 박형택 • 최선진 • 하정민
부산 메리놀병원 정형외과

연구 계획: 증례 보고

목적: 비교적 드물게 흉추에 발생한 다발성 흉추 신경초 낭종 1례를 경험하였기에 보고하고자 한다.

선행문헌의 요약: 주로 신경초 낭종은 천추부에 자주 발생하며 흉추부에 발생하는 경우는 아주 드물다. 특히 다발성 양측성 흉추 신경초 낭종은 그 예가 특히 드물다.

대상 및 방법: 증례는 65세 여자로 제10-11 및 제11-12 흉추 분절 양측에 신경초 낭종이 발견되었고 제10-11-12 후궁 절제 감압술 및 낭종 제거술이 시행되었다.

결과: 환자는 수술적으로 치료하였으며 만족스러운 결과를 얻을 수 있었다.

결론: 흉추의 신경초 낭종에 있어서 더 자세하고 명확한 치료를 위해선 더 많은 경험과 증례가 필요할 것으로 사료 된다.

색인 단어: 흉추, 신경초 낭종

약칭 제목: 다발성 흉추 신경초 낭종