



증례

40 8  
(NYHA - ) 20

가  
1 3

가

130/90 mmHg,  
64/ , 17/ , 36.2 , 58 kg,  
150 cm

가 57 /  
, aVF q , Q  
(Fig. 1),

가 168 mg/dl, 가 107 mg/dl ,  
. Modified Bruce protocol  
10 METs  
81% . 1  
3 5 ST 2 mm  
(upslope) (Fig. 2), 4

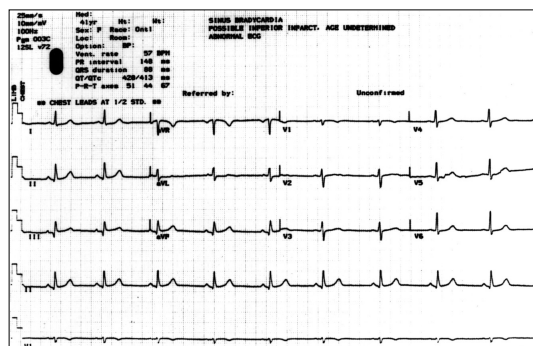


Fig. 1. Twelve lead electrocardiogram on admission.

1 ST  
-2  
<sup>201</sup>Tl - dipyridamole  
(Fig. 3),

30%  
Grade 3  
가 (Fig. 4).  
16 mmHg 가

가

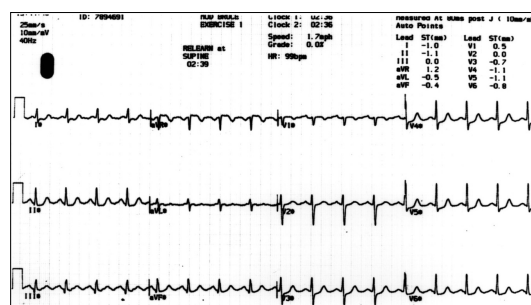


Fig. 2. Treadmill exercise test on admission.

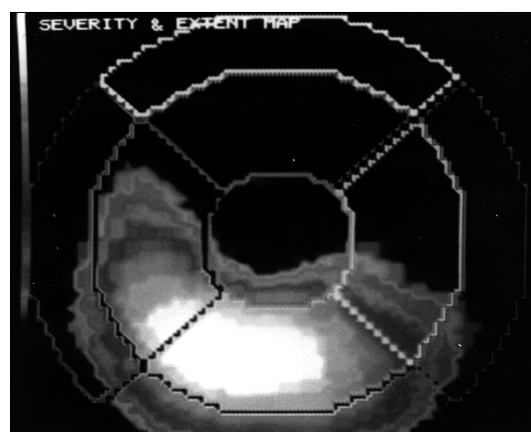
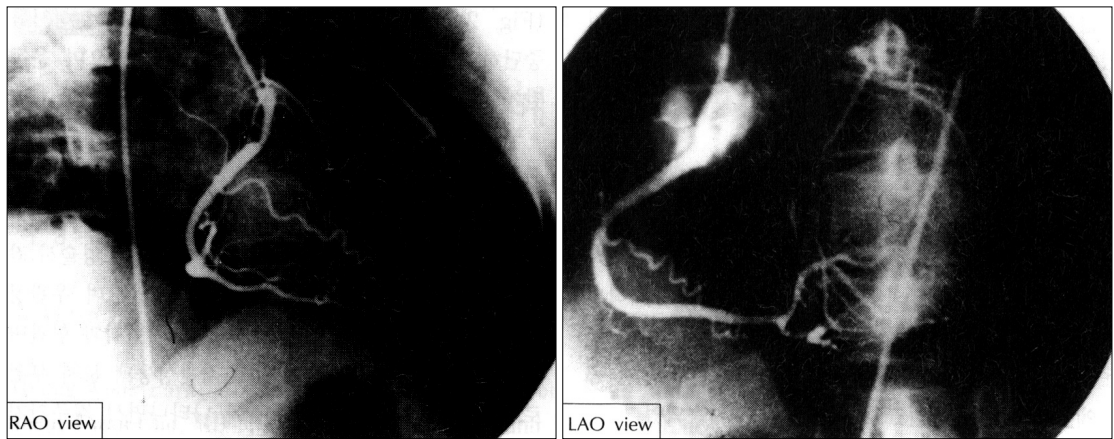


Fig. 3. Reversible perfusion defects at anterior wall, apex and lateral wall by <sup>201</sup>Tl-dipyridamole myocardial perfusion stress SPECT.



**Fig. 4.** Right anterior oblique (RAO) and left anterior oblique (LAO) views of right coronary angiogram revealed grade 3 collateral flows to the left anterior descending and circumflex coronary arteries.

1

5

12-14)

가

고 안

가

1912 Herrick 4)

가

가

가

1)5)6)

7-10)

(supravalv -

ular aortic stenosis),

(calcific coronary

sclerosis),

, Fri -

edreich

가

11)

가

16)17)

가

18-20)

가

가

Vals -

alva

중심 단어 :

- 1) Pritchard CL, Mudd JG, Barner HB. *Coronary ostial stenosis*. *Circulation* 1975;52:46-8.
- 2) Thomson R. *Isolated coronary ostial stenosis in women*. *J Am Coll Cardiol* 1986;7:997-1003.
- 3) Miller AH, Honey M, El Sayed H. *Isolated coronary ostial stenosis*. *Cathet Cardiovasc Diagn* 1986;12:30-4.
- 4) Herrick J. *Clinical features of sudden obstruction of the coronary arteries*. *JAMA* 1912;59:2015-20.
- 5) Roberts W, Ferrans V, Levy R, Fredrickson D. *Cardiovascular pathology in hyperlipoproteinemia*. *Am J Cardiol* 1973;31:557-70.
- 6) Ribeiro P, Shapiro L, Gonzales A, Thomson G, Oakley C. *Crosssectional echocardiographic assessment of the aortic root and coronary ostial stenosis in familial hypercholesterolemia*. *Br Heart J* 1983;50:432-7.
- 7) Chun P, Jones R, Robinowitz M, Davia J, Lawrence P. *Coronary arterial stenosis in Takayasu's arteritis*. *Chest* 1980;78:330-1.
- 8) Handler CE, Livesey S, Lawton PA. *Coronary ostial stenosis after radiotherapy*. *Br Heart J* 1989;61:208-11.
- 9) Silver MD, Wigle ED, Trimble AS. *Iatrogenic coronary ostial stenosis*. *Circulation* 1972;146:989-94.
- 10) Bedogni F, Castellani A, La Vecchia L. *Atresia of the left main coronary artery: Clinical recognition and surgical treatment*. *Cathet Cardiovasc Diagn* 1992;25:35-41.

- 1797