

Bifurcated Stent-Graft(Vanguard)를 이용한 복부 대동맥류의 경관적 치료

심원흠¹ · 최동훈¹ · 윤영섭¹ · 이도연² · 장병철³

Bifurcated Stent-Graft(Vanguard) for the Endovascular Treatment of Abdominal Aortic Aneurysm

Won-Heum Shim, MD¹, Donghoon Choi, MD¹, Young Sup Yoon, MD¹,
Do-Yun Lee, MD² and Byung-Chul Jang, MD³

¹Cardiology Division, ²Radiology, ³Cardiovascular Surgery, Yonsei Cardiovascular Center,
Yonsei University, Seoul, Korea

ABSTRACT

Purpose : The purpose of this study was to evaluate the safety, feasibility and effectiveness of an endoluminally-placed bifurcated stent-graft (Vanguard) for the treatment of infrarenal abdominal aortic aneurysm (AAA). **Methods** : Transluminal endovascular stent-graft placements were attempted in 29 patients (28 male, mean age 69 ± 7 years) with AAAs involving the common iliac arteries from Aug. 1997 to Jan. 1999. Endovascular therapy was performed in the cardiac catheterization laboratory with epidural anesthesia. One side of the femoral artery was opened by surgical cutdown for the bifurcated stent-graft entry and the other side was punctured percutaneously for the straight stent-graft. Computed tomography and/or intraarterial angiography were performed during an average follow-up of 10 months (2 -18 months). **Results** : Primary success rate was 75.9% (22 of 29 patients) and the overall success rate was 79.3% with successful correction of one perigraft leak. Twenty patients (69.0%) had significant coronary artery disease. There were two technical failure cases, the one was tortuous iliac vessel with spasm, the other was disconnection of the stent-graft connecting portion. Complications related to procedure occurred in 13.8% of patients (4 of 29 patients) and two of these four patients had procedure-related mortality because of acute renal failure following contrast overdose and sepsis after operation. **Conclusions** : Endovascular treatment of infrarenal AAA with bifurcated stent-graft (Vanguard[®]) is effective, feasible and relatively safe. However, further investigation for the outcome, complication and long-term follow-up are needed. (**Korean Circulation J 1999;29(2):907-912**)

KEY WORDS : Abdominal aortic aneurysm · Bifurcated Stent-graft · Endovascular treatment.

서 론

¹⁾

90%

^{2,3)}

: 1999 7 19

: 1999 9 1

: 120 - 752

: (02) 361 - 7049 · : (02) 393 - 2041

E - mail : whshimyumc.yonsei.ac.kr

40 50% 3 5% Boston Scientific(Oakland, NJ, USA) bifurcated stent - graft Vanguard 가 polyester 2가 가

가 40 60% 가

가

4)

stent - graft가 , 가 (limb)

(Fig. 1).

가

가 5-7)

가

bifurcated stent - graft

가

bifurcated stent - graft

가

bifurcated stent - graft(Vanguard)

가

연구대상 및 방법

1997 8 1999 1 29

가 28 ,

가 1 69±7 (62

83).

A F 6

A :

, B :

, C : 가

, D : 가

, E :

neck 15

mm B,

C, E 4.5 cm

가

neck 15 mm

1

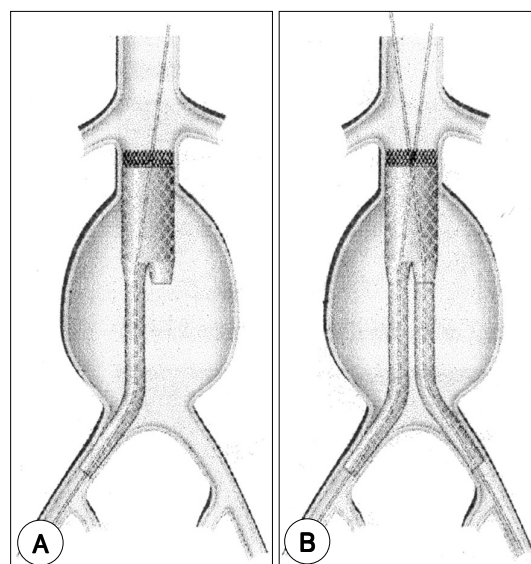


Fig. 1. Stent-Grafts used for the endoluminal treatment of infrarenal abdominal aortic aneurysms.
A : The main body is implanted with use of a delivery system inserted through a surgical cutdown.
B : The contralateral iliac limb is inserted percutaneously.

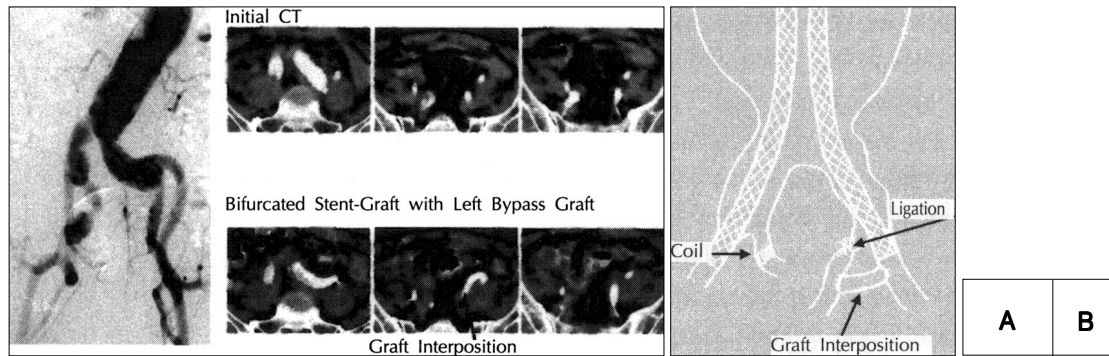


Fig. 2. Implantation of a bifurcated stent-graft in a 72-year-old patient with an infrarenal abdominal aortic aneurysm with involvement of the both internal iliac arteries.
A : Initial angiography and computed tomography obtained before the procedure show an infrarenal abdominal aortic aneurysm with involvement of the both internal iliac arteries. And follow-up computed tomography confirms the exclusion of the aortic aneurysmal sac.
B : Schematic treatment method for the infrarenal abdominal aortic aneurysm with involvement of the both internal iliac arteries.

연구 결과

18

C

8

6

, 2

29

가 20 (69.0%)

2

가

, 3

2

1

가

6.3±

0.9(4.8 8.0 cm) cm

4 cm

가

2

27

22

(Fig. 2).

1

75.9%

1

1

stent - graft

12 mm

1

가

4 (13.8%)

가

5

3

2

B

가 4

가 2 , Nitinol(nickel titanium) polyurethane
1 15 French
2 , Lawrence 1987 Gianturco
Dacron graft stent - graft
가 11 French teflon¹¹⁾
2 18 .
5
, 3 , 2 stent - graft
1 1991 Parodi Palmaz stent
Dacron
79.3% stent - graft 5⁷⁾ stent -
고 안 graft
, 12 - 14) 가
polyester stent - graft가
가, 가^{15,16)}
1994 stent - graft
dynamic computed tomography 가
17,18,19) 가
stent - graft
가
bifurcated type stent - graft가
가
154
가 가
(Percutaneous Tra -
nsluminal Angioplasty ; PTA) 가²⁰⁾
, PTA
가 PTA 가 가 87% 0.4%,
Dotter⁹⁾가 1969 23
가 85%
가 stent - graft가 6.9%
^{5,6)} 가
1980 가 가
. Balko¹⁰⁾ 1986

19

가 가

(Vanguard)

5

18.6%

7 34%

40

20%

요 약

67%

가 ^{21,22)}

3 , 2

1

연구배경 :

(Vanguard)

가 대상 및 방법 :

1997 8 1999 1 18 29

가

(Vanguard) 27

2

28 , 1

69±7

(: 15 , : 12),

(Vanguard®)

가 fluoroscopic

guide 2 18

(10) CT

가

결 과 :

가 22 (75.

9%) , (Vanguard)

5 1

가 가 79.3%

. 20 (69.0%)

. 2 (Vanguard)

, 1

stent graft , 1

가

가 , 2 가

4 (13.8%)

1

2

6.9%

결 론 :

(Vanguard)

중심 단어 :

감사문

REFERENCES

- 1) Isselbacher EM, Eagle KA, Desantis RW. *Abdominal aortic aneurysms*. In Braunwald E, editors. *HEART DISEASE: A textbook of cardiovascular medicine*. 5th ed. W.B. Saunders company;1997. p.1547-50.
- 2) Ernst CB. *Abdominal Aortic Aneurysm*. *N Eng J Med* 1993;328:1167-72.
- 3) Harris LMm, Faggidli GL, Fiedler R, Curl GR, Ricotta JJ. *Ruptured abdominal aortic aneurysms: Factors affecting mortality rates*. *J Vasc Surg* 1991;14:812-8.
- 4) Brown OW, Hollier LH, Pairolero PC, Kazmier FJ, McCready RA. *Abdominal aortic aneurysm and coronary artery disease*. *Arch Surg* 1981;116:1484-8.
- 5) Piquet P, Rolland PH, Bartoli JM, Trainer P, Moulin G, Mercier C. *Tantalum-Dacron cknit Stent for endovascular treatment of aortic aneurysms. A preliminary experimental study*. *J Vasc Surg* 1994;19:698-706.
- 6) Dake MD, Miller C, Semba CP, Mitchell RS, Walker PJ, Liddel RP. *Transluminal placement of endovascular Stent-grafts for the treatment of descending thoracic aortic aneurysms*. *N Eng J Med* 1994;331:1729-34.
- 7) Parodi JC, Palmaz JC, Barone HD. *Transfemoral intraluminal graft implantation for abdominal aortic aneurysms*. *Ann Vasc Surg* 1991;5:491-9.
- 8) Mialhe C, Amicabile C, Becquemin JP. *Endovascular treatment of infrarenal abdominal aneurysms by the Stentor system: Preliminary result of 79 cases*. *J Vas Surg* 1997;26:199-209.
- 9) Dotter CT. *Transluminally-placed coilspring endarterial tube grafts. Long-term patency in canine popliteal artery*. *Invest Radiol* 1969;4:329-32.
- 10) Balko A, Piasecki GJ, Shah DM, Carney WL, Hopkins RW, Jackson BT. *Transfemoral placement of intraluminal polyurethane prosthesis for abdominal aortic aneurysm*. *J Surg Research* 1986;40:305-9.
- 11) Lawrence DD, Charnsangavej C, Wright KC, Gianturco C, Wallace S. *Percutaneous endovascular graft: Experimental evaluation*. *Radiol* 1987;163:357-60.
- 12) Marin ML, Veith FJ, Panetta TF, et al. *Percutaneous transfemoral insertion of a Stented graft to repair a traumatic femoral arteriovenous fistula*. *J Vasc Surg* 1993;18:299-302.
- 13) Cragg AH, Dake MD. *Percutaneous graft placement*. *JVIR* 1993;4:455-63.
- 14) May J, White G, Waugh R, Yu W, Harris J. *Transluminal placement of a prosthetic graft-Stent device for treatment of subclavian artery aneurysm*. *J Vasc Surg* 1993;18:1056-9.
- 15) White GH, Yu W, May J, Stephen MS, Waugh RC. *A new nonstented balloon-expandable graft for straight or bifurcated endoluminal bypass*. *J Endovasc Surg* 1994;1:16-24.
- 16) Chutter TAM, Green RM, Ouriel K, Fiore WM, DeWeese JA. *Transfemoral endovascular aortic graft placement*. *J Vasc Surg* 1993;18:185-97.
- 17) DY Lee, BC Chang, WH Shim, SY Cho, NS Chung, HM Kwon, et al. *Transluminal endovascular Stent-graft for the treatment of aortic aneurysm*. *J Korean Radiological Society* 1995;33:361-6.
- 18) WH Shim. *Non-surgical treatment of abdominal aortic aneurysm*. *Journal of the Korean Medical Association* 1994;37:1357-62.
- 19) DH Choi, WH Shim, YS Yoon, SY Kim, KJ Park, DY Lee, et al. *Transluminal Endovascular Stent-Graft for the Treatment of Vascular Lesions*. *The Korean Circulation Journal* 1998;28:supp II-330.
- 20) Blum U, Voshage G, Lammer J, Beyersdorf F, Tollner D, Kretschmer G, et al. *Endoluminal stent-grafts for infrarenal abdominal aortic aneurysms*. *N Engl J Med* 1996;336:13-20.
- 21) Moore WS, Vescera CL. *Repair of abdominal aortic aneurysm by transfemoral endovascular graft placement*. *Ann Surg* 1994;220:331-41.
- 22) Lumsden AB, Allen RC, Chaikof EL, Resnikoff M, Moritz MW, Gerhard H, et al. *Delayed rupture of aortic aneurysms following endovascular stent grafting*. *Am J Surg* 1995;170:174-8.