

## US and CT Imaging of Undifferentiated Carcinoma of the Pancreas<sup>1</sup>

Seung Yon Baek, M.D., Chung Sik Rhee, M.D.

We report the case of a 64-year-old female patient with an undifferentiated carcinoma involving the pancreatic head in whom hepatic metastasis and encasement of the portal and superior mesenteric veins had occurred. Ultrasound demonstrated a round well-defined hypoechoic mass with increased color Doppler flow signals at the periphery, while CT revealed a heterogeneously enhanced mass with a less attenuated central portion and rim enhancement of the pancreatic head.

**Index words :** Pancreas, neoplasms

Pancreas, CT

Pancreas, US

Undifferentiated (anaplastic or pleomorphic) carcinoma of the pancreas was first reported by Sommers and Meissner in 1954 and accounts for 2 - 7% of all pancreatic carcinomas (1). The origin of the tumor is controversial, though it is generally thought to be of ductal epithelial origin. Although this uncommon tumor is distinctly different from pancreatic ductal adenocarcinoma, differentiation on the basis of radiologic imaging findings is difficult. We describe the ultrasound (US) and CT findings in a case of undifferentiated carcinoma of the pancreas.

### Case Report

A 64-year-old female patient with lower abdominal pain which had begun one day earlier was admitted to our hospital. She had undergone a hysterectomy for leiomyoma ten years previously and had lost 7 Kg of

body weight during two-month period. Physical examination demonstrated tenderness of the lower abdomen but the area was soft and flat, without a palpable mass. Laboratory tests demonstrated high level of glucose in the blood [ 682 (normal range, 80 - 120) mg/dl] and urine ( + + + + ), while for CA19-9 as a tumor marker, the reading was 1259.2 (normal range, < 36) U/ml. These results suggested the presence of diabetes mellitus and possible pancreatic or colorectal cancer.

Abdominal US demonstrated that in the pancreatic head, a round, well-defined, relatively homogeneous, hypoechoic mass measuring 4 × 3.3 cm was present (Fig. 1A). As a result, the pancreatic duct- though not the biliary ductal system- was slightly dilatated. Color Doppler US revealed an increase in color flow signals at the periphery of the mass (Fig. 1B). Non-enhanced abdominal CT depicted a slightly heterogenous solid mass (Fig. 1C), while at delayed-phase contrast-enhanced CT, a heterogeneously-enhanced solid mass with a central portion of lower attenuation and rim enhancement of the pancreatic head was depicted. Partial thrombosis was noted in the main portal and superior mesenteric venous lumen, and the mass encased the portal confluence and superior mesenteric vein (Fig. 1D). A low-attenuated and rim-enhanced mass measuring 3 × 2 cm

<sup>1</sup>Department of Radiology, College of Medicine, Ewha Womans University

Received January 24, 2002 ; Accepted June 10, 2002

Address reprint requests to : Seung Yon Baek, M.D., Department of Radiology, Ewha Womans University Mokdong Hospital, 911-1 Mokdong, Yangcheon-gu, Seoul 158-710, Korea.

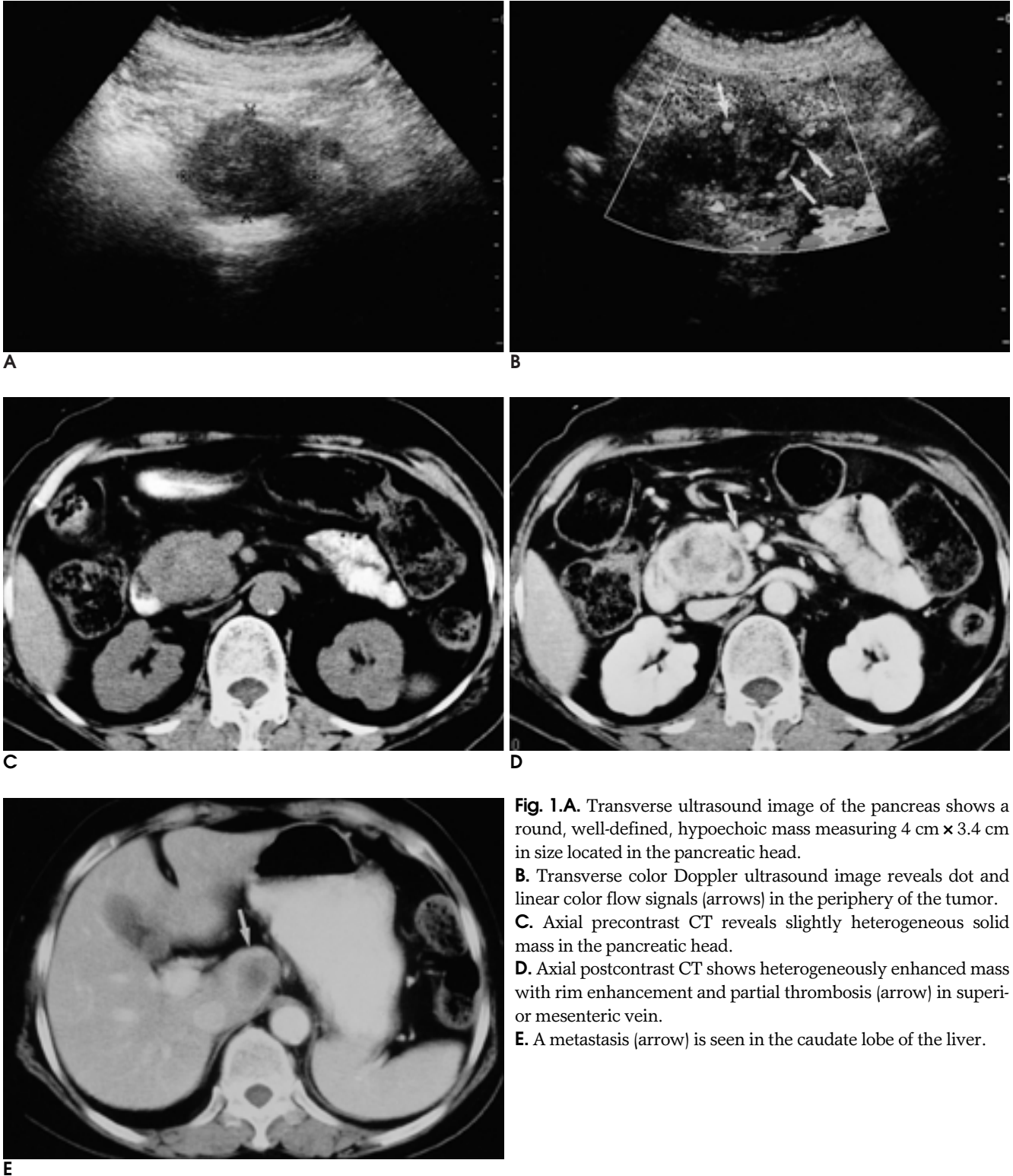
Tel. 82-2-650-5173 Fax. 82-2-2644-3362

E-mail: bbaek@mm.ewha.ac.kr

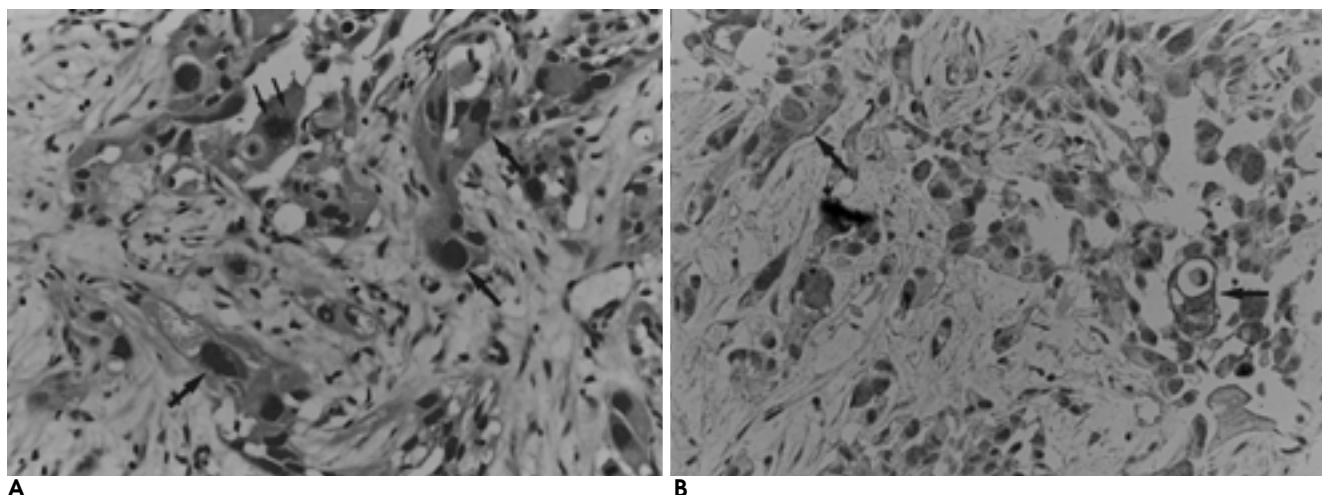
had metastasized to the caudate lobe of the liver (Fig. 1E).

On the basis of these findings, our preferred prospective diagnosis was malignant islet cell tumor, with ductal adenocarcinoma as the second choice. After biopsy of the pancreatic head mass using a 19-G biopsy gun un-

der US guidance, microscopy revealed the presence of large bizarre anaplastic cells and frequent mitosis (Fig. 2A). Immunohistochemical staining with cytokeratin showed a positive reaction, and sarcoma and malignant melanoma were thus excluded (Fig. 2B). The final diagnosis was undifferentiated (anaplastic) carcinoma of the



**Fig. 1.** **A.** Transverse ultrasound image of the pancreas shows a round, well-defined, hypoechoic mass measuring 4 cm × 3.4 cm in size located in the pancreatic head. **B.** Transverse color Doppler ultrasound image reveals dot and linear color flow signals (arrows) in the periphery of the tumor. **C.** Axial precontrast CT reveals slightly heterogeneous solid mass in the pancreatic head. **D.** Axial postcontrast CT shows heterogeneously enhanced mass with rim enhancement and partial thrombosis (arrow) in superior mesenteric vein. **E.** A metastasis (arrow) is seen in the caudate lobe of the liver.



**Fig. 2.A.** Anaplastic carcinoma with large, bizarre tumor cells (large arrows) with frequent mitosis (small arrows) on hematoxylin-eosin staining  $\times 200$ .

**B.** Immunohistochemical staining  $\times 200$  with cytokeratin shows positive reaction in some tumor cells (arrows).

pancreas.

The patient underwent chemotherapy, with a regimen of gemcitabine 1.4 g ( $1000 \text{ mg/m}^2$ ), cisplatin 145 mg ( $100 \text{ mg/m}^2$ ) and insulin therapy for the diabetes mellitus. CA 19 - 9 increased from its initial level of 1259.2 U/ml to 1860.6 U/ml one month later, and follow-up chemotherapy was prescribed.

## Discussion

Undifferentiated carcinoma is an uncommon malignancy that histologically resembles sarcoma (2). It is extremely aggressive, and the invasion of adjacent organs and the vascular system, as well as lymphadenopathy and distant metastases, are common (3). Thus the mean survival time from diagnosis has been reported as 2 - 3 months (4 - 6).

This tumor is most common in men in the sixth decade (3). In contrast to ductal adenocarcinoma, which in 65% of cases arises in the pancreatic head, undifferentiated carcinoma more frequently involves the body and tail (4, 7). In our case, however, the patient was a woman in her seventh decade, and the pancreatic head was involved.

A small number of radiologic reports have described undifferentiated carcinoma of the pancreas (2, 3, 8). Small tumors may be hypovascular and very similar to ductal adenocarcinoma; more commonly, however, undifferentiated tumors are large and moderately hypervascular, and present as an exophytic growing mass with a large central area of necrosis. They are thus often

misdiagnosed as neuroendocrine (islet cell) tumors. Undifferentiated tumors show an aggressive pattern of growth, with metastasis, the invasion of adjacent organs, vascular invasion or occlusion, and pancreaticobiliary ductal obstruction (3). In our case, the tumor showed hypervascularity at color Doppler US, metastasized to the liver, and led to thrombosis in the main portal and superior mesenteric vein.

Differential diagnoses of an undifferentiated carcinoma of the pancreas include ductal adenocarcinoma, neuroendocrine (islet cell) tumor or even extra-pancreatic tumors such as gastrointestinal stromal tumor or renal cell carcinoma (3). While ductal adenocarcinoma may manifest as a large pancreatic mass, with metastasis to the peripancreatic lymph nodes and liver, as well as ascites, a frequent manifestation of undifferentiated carcinoma is extensive distant lymph node involvement, extending inferiorly to the aortic bifurcation and superiorly to the esophageal hiatus (2). Ductal adenocarcinoma arises in the pancreatic head in 65% of cases, while undifferentiated carcinoma involves the body and tail in 78% of cases (3).

Freeny et al. reported that in 11% (11/96) of adenocarcinoma of the pancreatic head, there was isolated dilatation of the main pancreatic duct but no biliary ductal dilatation (9). They did not, however, discuss their findings. In our case, though, it appeared that even though the tumor was located in the pancreatic head, the biliary duct would not be dilated, if the tumor had not invaded or compressed the intrapancreatic portion of the common bile duct lumen.

It is very difficult to distinguish between undifferentiated carcinoma and nonfunctioning islet cell tumor. A functioning islet cell tumor produces a hormone which causes clinical symptoms, and can be diagnosed, but one that is nonfunctioning takes the form of a large enhancing mass that has metastasized by the time of initial diagnosis.

The important points for differentiation between pancreatic and extra-pancreatic tumors such as gastrointestinal stromal tumor or renal cell carcinoma are the direction of tumor growth and clinical information such as an absence of hematemesis or hematuria (3).

A tumor is almost always unresectable at the time of diagnosis, but percutaneous biopsy provides adequate confirmation of its nature (3). The cut surface of a tumor usually reveals extensive necrosis, without hemorrhage. Reports have shown that microscopically, tumors may be characterized by mixtures of dedifferentiated, pleomorphic and multinucleated giant cells, and some have anaplastic mononuclear and spindle cells with abundant eosinophilic cytoplasm (2, 3). Ichikawa et al. reported that three of nine anaplastic tumors coexisted with conventional ductal or signet ring-type adenocarcinoma (3).

In summary, while undifferentiated carcinoma of the pancreas is difficult to differentiate from ductal adenocarcinoma, it should be included in the differential diag-

nosis when color Doppler and gray-scaled US reveal a hypervascular, hypoechoic mass, and CT demonstrates a heterogeneously enhanced mass together with early liver metastasis and vascular encasement.

## References

1. Sommers S, Meissner W. Unusual carcinoma of the pancreas. *Arch Pathol* 1954;58:101-111
2. Wolfman NT, Karstaedt N, Kawamoto EH. Pleomorphic carcinoma of the pancreas: computed-tomographic, sonographic, and pathologic findings. *Radiology* 1985;154:329-332
3. Ichikawa T, Federle MP, Ohba S, et al. Atypical exocrine and endocrine pancreatic tumors (anaplastic, small cell, and giant cell types): CT and pathologic features in 14 patients. *Abdom Imaging* 2000;25:409-419
4. Tschang TP, Garza-Garza R, Kissane JM. Pleomorphic carcinoma of the pancreas. *Cancer* 1977;39:2114-2126
5. Cubilla AL, Fitzgerald PJ. *Tumor of the exocrine pancreas. In Atlas of tumor pathology. vol 19, 2nd series.* Washington DC: Armed Forces Institute of Pathology 1984;155-167
6. Uenishi T, Hirohashi K, Kubo S, et al. A pancreatic anaplastic carcinoma of spindle-cell form. *Int J Pancreatol* 1999;26:201-204
7. Reyes CV, Crain S, Wang T. Pleomorphic giant cell carcinoma of the pancreas; a review of nine cases. *J Surg Oncol* 1980;15:345-348
8. Friedman A, Edmonds PR. Rare pancreatic malignancies. *Radiol Clin North Am* 1989;7:177-190
9. Freeny PC, Marks WM, Ryan JA, Traverso LW. Pancreatic ductal adenocarcinoma: diagnosis and staging with dynamic CT. *Radiology* 1988;166:125-133

