



가 , , CT , 850 cc가 CT , 10 mm, 1.3 CT , 8 mm 3 CT 7 (Fig. 1B), 4 cm 가 (2, 4), 7 0.7 x 1 cm (Fig. 1C), (stasis) 가 가 60 가 3 130/80 mmHg, 120 / , 20 / , 37.0 Lisch , 1 von Recklinghausen 3.6% (1, 2). 1 (Fig. 1A). 가 2000 /ml , , Green (5) 가

formation) (neural mal - cal) 가 (mechani - 가 ,

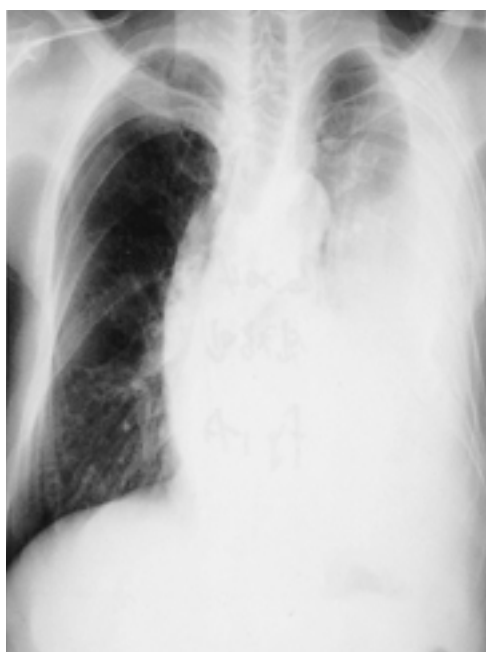
(dysplasia) Miura (2) 12 50%가 .

3 2 (2). Leier 가 가

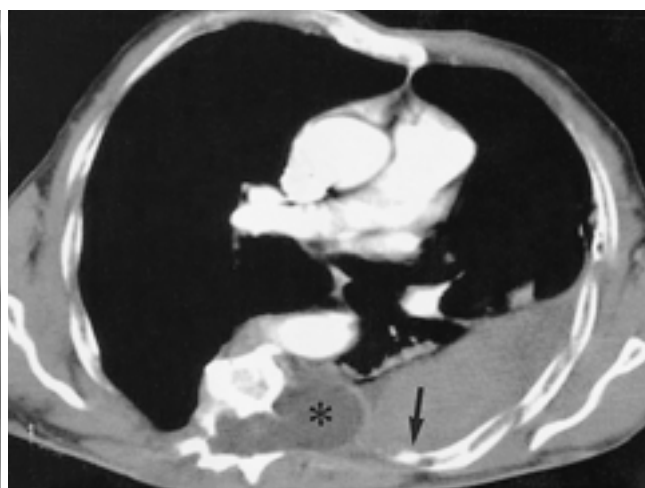
(6) 2가 가 (vasa vaso - 가 (5 - 9).

rum) 가 (stretching), CT (arterial phase)

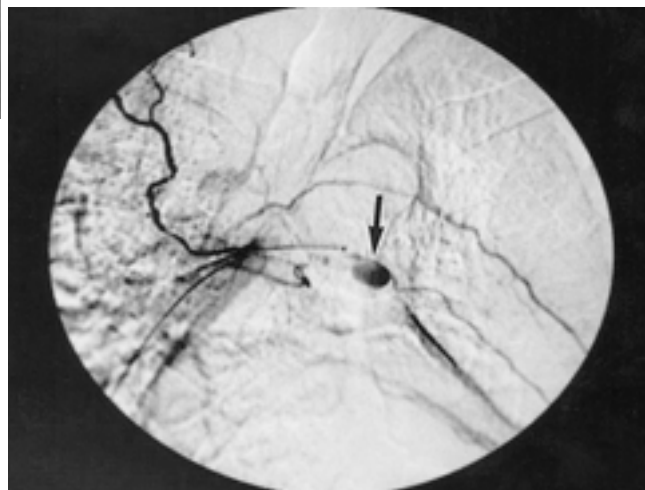
CT (extravasation)



A



B



C

Fig. 1. A 60 year-old man with neurofibromatosis type .
A. Initial chest radiograph shows large pleural effusion in left hemithorax with thoracic scoliosis.
B. Contrast-enhanced CT scan shows strongly enhancing nodule (arrow) in left 7th intercostal space which suggests intercostal artery aneurysm. Note massive hemothorax and spinal meningocele(*).
C. Angiogram shows 1cm sized intercostal artery aneurysm (arrow).

CT가

1. Cormier JM, Cormier F, Mayade F, Fichelle JM. Arterial complications of neurofibromatosis. *J Mal Vasc* 1999;24:281-286
2. Miura H, Taira O, Uchida O, Usuda J, Hirai S, Kato H. Spontaneous hemothorax associated with von Recklinghausen's disease: review of occurrence in Japan. *Thorax* 1997;52:577-578
3. Wolkenstein P, Zeller J. Clinical diagnosis of neurofibromatosis type 1. *Presse Med* 1999;28:2174-2180
4. Butchart EG, Grötte GJ, Barnsley WC. Spontaneous rupture of an intercostal artery in a patient with neurofibromatosis and scoliosis. *J Thorac Cardiovasc Surg* 1975;69:919-921
5. Greene JF, Fitzwater JL, Burgess J. Arterial lesions associated with neurofibromatosis. *Am J Clin Pathol* 1974;62:481-487
6. Leier CV, DeWan CJ, Aatasia LF. Fatal hemorrhage as a complication of neurofibromatosis. *J Vasc Surg* 1972;6:98-101.
7. Larrieu AJ, Hashimoto SA, Allen P. Spontaneous massive hemothorax in von Recklinghausen's disease. *Thorax* 1982;37:151-152
8. Brady DB, Bolan JC. Neurofibromatosis and spontaneous hemothorax in pregnancy: two case reports. *Obstet Gynecol* 1984;63:35S-38S
9. Salyer WR, Salyer DC. The vascular lesions of neurofibromatosis. *Angiology* 1974;25:510-519

J Korean Radiol Soc 2001;44:59 - 61

Spontaneous Hemothorax Caused by Rupture of an Intercostal Artery Aneurysm in Neurofibromatosis Type I: A Case Report¹

Chang Min Shim, M.D., Jae Boem Na, M.D., Jin Jong You, M.D., Sung Hoon Chung, M.D.

¹Department of Diagnostic Radiology, Gyeongsang National University, College of Medicine

Neurofibromatosis type I (NF-1) is the most common neurocutaneous syndrome. Associated vascular abnormalities are arterial occlusion, aneurysm, ectasia and arteriovenous malformation. Spontaneous massive hemothorax due to rupture of an arterial aneurysm is rare but fatal. It is, therefore, essential to determine the location of an aneurysm and provide immediate surgical or other interventional treatment. We report a case of spontaneous hemothorax caused by rupture of an intercostal arterial aneurysm diagnosed by CT and angiography.

Index words : Neurofibromatosis
Aneurysm, rupture
Thorax, hemorrhage

Address reprint requests to : Jae Boem Na, M.D., Department of Diagnostic Radiology, Gyeongsang National University Hospital
90 Chilam-dong, Chinju 660-702, Korea.
Tel. 82-591-50-8212 Fax. 82-591-758-1568

ECR

	,			
	(1)			

ECR 가

.

:

1

2001 . . .

()

ECR

.

2001 . . .

:

:

:

()