

CT Diagnosis of Tracheobronchial Rupture Following Blunt Trauma with Demonstration of the Injury Site : A Case Report¹

Bo Young Ahn, M.D., Kyung Ah Chun, M.D., Si Won Kang, M.D.,
Ki Tae Kim, M.D., Seog Hee Park, M.D.

Tracheobronchial disruption is a rare injury associated with blunt trauma, and for proper management, accurate diagnosis is essential. We describe a case of isolated tracheal rupture following blunt trauma, and the related CT findings, including details of the injury site. Preoperative bronchoscopy was not performed, but the patient immediately underwent surgery, which was successful.

This case demonstrates that CT scanning is very helpful both for diagnosis of tracheobronchial injury and for delineation of the exact injury site.

Index words: Trachea, injuries
Trachea, CT
Bronchi, injuries
Trauma

Tracheobronchial rupture following trauma is a rare entity, but its incidence is increasing (1). It is frequently fatal, but early diagnosis and management can reduce mortality and morbidity. Despite the frequent use of CT for the evaluation of chest injury after blunt trauma, diagnosis of tracheobronchial rupture by CT scan has rarely been reported: to our knowledge, CT detection of the injury site has been previously described in only one case (2). We describe a case of tracheobronchial rupture following blunt trauma in which CT was used to demonstrate the exact injury site.

Case Report

A 30-year-old-man was brought to the emergency ward after an automobile accident. He complained of

chest pain and dyspnea, though initial vital signs were stable.

Chest radiography indicated massive subcutaneous emphysema and pneumomediastinum (Fig. 1A, B). CT scans of the chest revealed subcutaneous emphysema, pneumomediastinum, and apparent communication between the mediastinum and tracheal lumen by way of a large tear in the membranous portion of the trachea just above the carina (Fig. 1C).

Immediate right posterolateral thoracotomy showed a 3-cm longitudinal tear in the posterior membranous portion of the trachea extending from 2 cm above the carina to the right main bronchus 1 cm below the carina. Mediastinal fat tissue contained huge amounts of air. The tear was repaired by means of a right posterolateral thoracotomy using 4-0 vicryl suture.

Postoperative CT scanning revealed a normal trachea and right main bronchus, with no evidence of remaining pneumomediastinum and subcutaneous emphysema. Postoperative bronchoscopy showed granulation tissue at the primary repair site, with no evidence of obstruction.

The patient progressed well and was discharged on the 12th postoperative day.

¹Department of Radiology, College of Medicine, The Catholic University of Korea

Received June 23, 1999; Accepted September 2, 1999

Address reprint requests to : Bo Young Ahn, M.D., Department of Radiology, Uijongbu St. Mary's Hospital, The Catholic University of Korea.

#65-1 Kumoh-Dong, Uijongbu City, Kyunggi Do 480-130, Korea.

Tel. 82-351-820-3138 Fax. 82-351-846-3080

E. mail. abycmc@cmc.cuk.ac.kr

Discussion

As the clinical signs and symptoms of acute airway injury after blunt chest trauma may be nonspecific and initially overlooked in the presence of more obvious damage to other organ systems, chest radiography and CT scanning are potentially important sources of diagnostic information (3). Clinical presentations of tracheobronchial rupture commonly include dyspnea, sternal tenderness, subcutaneous emphysema, hemoptysis and pneumomediastinum or pneumothorax (4). Several mechanisms appear to play a role in tracheobronchial disruption. The first is a severe crush injury to the chest, with compression of the tracheobronchial tree between the sternum and vertebral column, resulting in distraction of the carina. The second is a shearing effect on the

bronchus caused by rapid deceleration, and the third is a rapid increase in tracheobronchial pressure resulting from a crush injury to the chest with a closed glottis (5). The usual site of injury is within 2.5 cm of the carina, and the right main stem bronchus is more commonly involved than the left. Airway injury rarely occurs more distally (6,7).

Tracheobronchial injury following blunt trauma is uncommon and usually occurs in association with injury to other mediastinal or thoracic structures. Isolated tracheobronchial injury is rare. In our case, only tracheobronchial rupture following blunt chest trauma developed.

The radiologic manifestations of tracheobronchial rupture are well recognized and include subcutaneous emphysema, pneumomediastinum, pneumothorax, air surrounding a bronchus, upper thoracic fractures, ab-

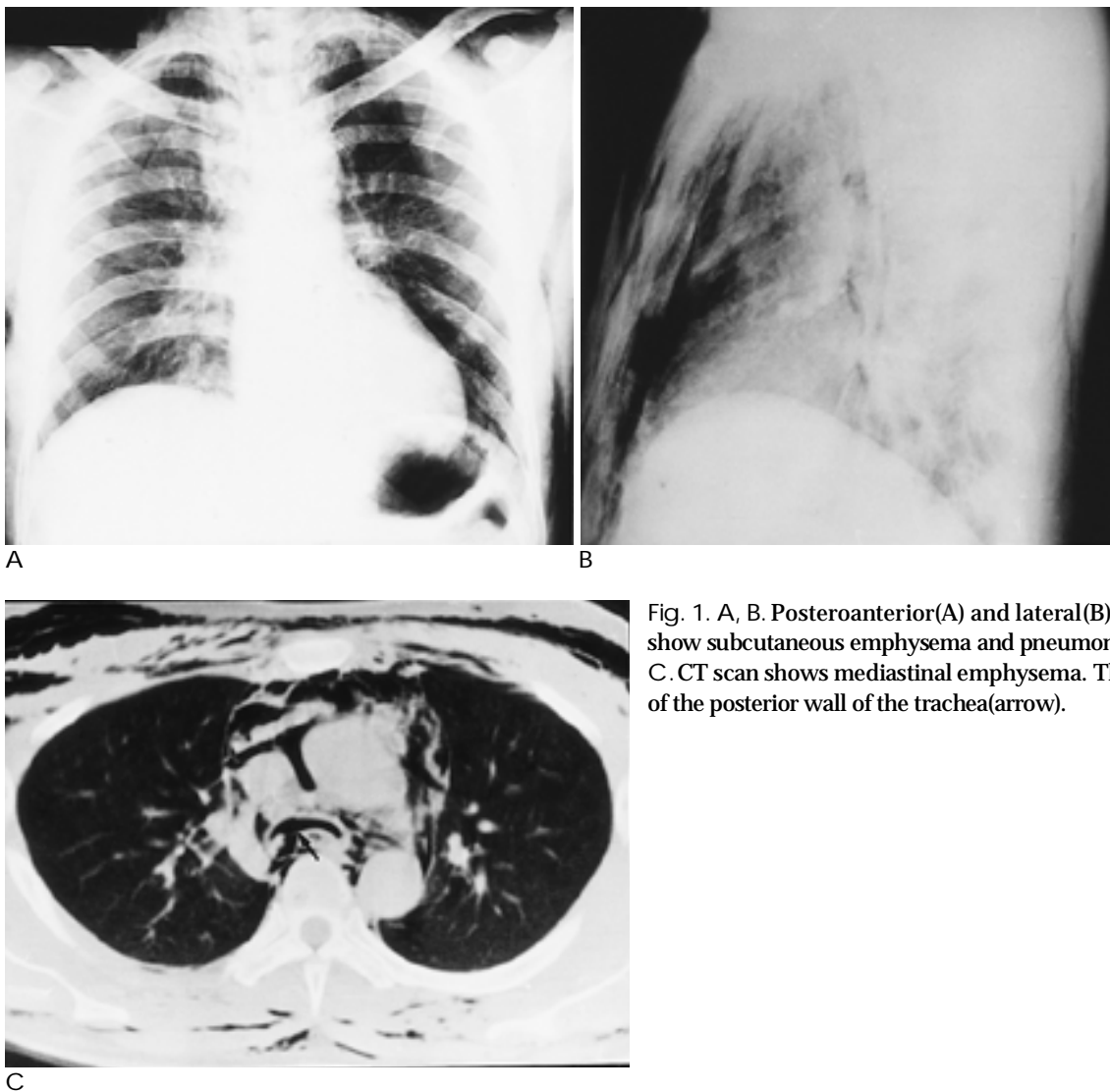


Fig. 1. A, B. Posteroanterior(A) and lateral(B) chest radiographs show subcutaneous emphysema and pneumomediastinum. C. CT scan shows mediastinal emphysema. There is a disruption of the posterior wall of the trachea(arrow).

normality of endotracheal tube configuration, and the presence of the fallen lung sign (collapse of the lung toward the lateral chest wall) (3). In tracheobronchial injury caused by blunt trauma, pneumomediastinum and subcutaneous emphysema are the most frequent radiographic findings. Pneumothorax with tracheobronchial transection is the result of rupture of the mediastinal pleura or injury to the right mainstem bronchus or distal left bronchus, allowing air to enter the pleural space on the ipsilateral side. In instances in which tracheobronchial injury does not communicate with the pleural space, pneumothoraces may be small or altogether absent. In our case, pneumothorax was not seen.

CT scanning has been a useful adjuvant to bronchoscopy in the diagnosis and delineation of tracheal injury, but only one case report, by Palder et al., has described the injury site (2). In the present case, the use of CT scanning helped determine the exact site of injury and management, and the procedure may be useful in cases of tracheobronchial injury in which clinical and plain radiographic findings are more subtle. The decision to proceed with bronchoscopy may be supported by CT findings. Even if CT scanning of a tracheobronchial injury site fails to provide definite diagnosis, CT provides additional information that contributes to diag-

nosis.

Thus, when a patient's clinical condition and plain radiographs suggest tracheobronchial rupture after blunt trauma, CT scanning can provide a noninvasive diagnostic evaluation of the exact site of tracheobronchial rupture.

References

1. Harvey-Smith W, Bush W, Northrop C. Traumatic bronchial rupture. *AJR* 1980;134:1189-1193
2. Palder SB, Shandling B, Manson D. Rupture of the thoracic trachea following blunt trauma: diagnosis by CAT scan. *J Pediatr Surg* 1991;26:1320-1322
3. Unger JM, Schuchmann GG, Grossman JE, Pellett JR. Tears of the trachea and main bronchi caused by blunt trauma: radiologic findings. *AJR* 1989;153:1175-1180
4. Symbas PN, Justicz AG, Ricketts RR. Rupture of the airways from blunt trauma: treatment of complex injuries. *Ann Thorac Surg* 1992;54:177-183
5. Baumgartner F, Sheppard B, de Virgilio C, et al. Tracheal and main bronchial disruptions after blunt chest trauma: presentation and management. *Ann Thorac Surg* 1990;50:569-574
6. Hancock BJ, Wiseman NE. Tracheobronchial injuries in children. *J Pediatr Surg* 1991;26:1316-1319
7. Millham FH, Rajii-Khorasani A, Birkett DF, Hirsch EF. Carinal injury; Diagnosis and treatment-case report. *J Trauma* 1991;31:1420-1422

1999;41: 1151- 1153

