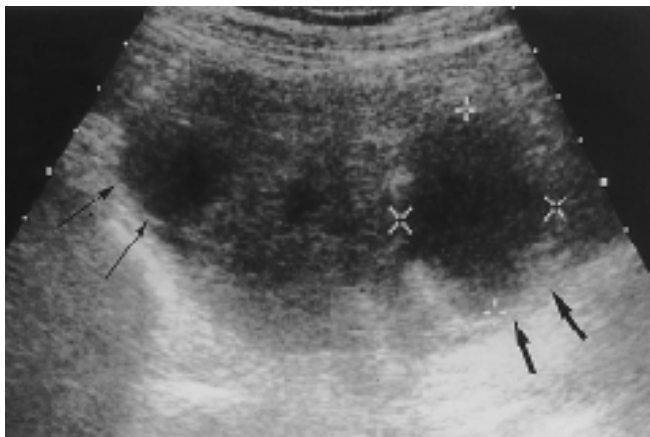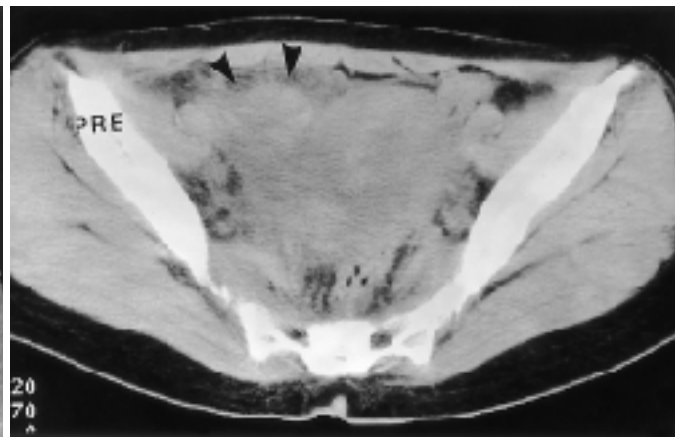


1 (hematosalpinx) (hydrosalpinx), 3), 4)
2
1998 11 30 1998 1 8 . , 5) (mesosalpinx), 6)

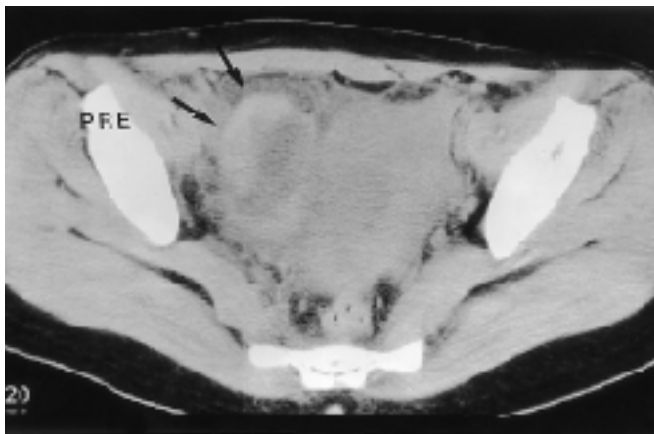
1) , 2) 가 (2).
 , 3) , 4) , 5) 46 %
 , 6) (2) , 가
 (1) 가 (1).
 1/3 가
 (fimbria) 가
 가
 가 (echogenic debris)
 (3-7).



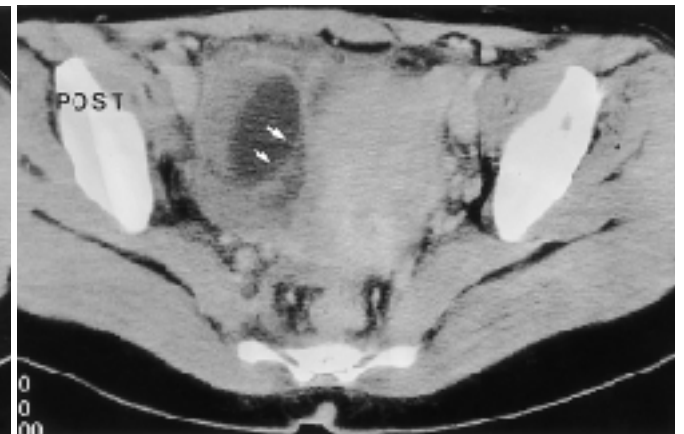
A



B



C



D

Fig. 1. 32-year-old woman with pelvic pain.

A. Longitudinal transabdominal ultrasonogram shows a well defined oval shaped mass with heterogeneous internal echo. Solid portion is located between two cysts in the upper(thin arrows) and lower portion(thick arrows) of the mass. On operation, the right fallopian tube was very long and tortuous, and was twisted at the ampullar portion.

B. CT at the level of the mid portion of the right adnexal mass(arrowheads) shows ill defined heterogeneous density mass mixed with spotty high densities in peripheral portion. Pathologic specimen shows diffuse hemorrhagic necrosis.

C. CT at the lower portion of the pelvic mass shows heterogeneous cystic mass with irregularly thickened high density peripheral portion.

D. High density peripheral portion is slightly enhanced and thin linear septum is noted medial aspect of the cyst, suggested the starting point of the tubal torsion(white arrows). PRE= unenhanced image, POST= enhanced image.

가

가

가

가

가

가

가

(2).

가

1. Nichols DH, Julian PJ. Torsion of the adnexa. *Clin Obstet Gynecol* 1985;28:375-380
2. McGowan L. Torsion of cystic or diseased adnexa tissue. *Am J Obstet Gynecol* 1964;88:135-136
3. Elchalal U, Caspi B, Schachter M, Borenstein R. Isolated tubal torsion : clinical and ultrasonographic correlation. *J Ultrasound Med* 1993;2:115-117
4. Caspi B, Ben-Galim P, Weissman A, Appleman Z. The engorged fallopian tube: a new sonographic sign for adnexal torsion. *J Clin Ultrasound* 1995;23:505-507
5. Sherer DM, Liberto L, Abramowicz JS, Woods JR. Endovaginal sonographic features associated with isolated torsion of the fallopian tube. *J Ultrasound Med* 1991;10:107-109
6. Propeck PA, Scanlan KA. Isolated fallopian tube torsion. *AJR* 1998;170:1112-1113
7. Baumgartel PB, Fleischer AC, Cullinan JA, Bluth RF. Color Doppler sonography of tubal torsion. *Ultrasound Obstet Gynecol* 1996;7:367-370

J Korean Radiol Soc 1999;40:755- 757

Isolated Fallopian Tubal Torsion : A Case Report¹

Hahm Jin-kyeung, M.D., Kim Young-kook, M.D.²

¹Department of Diagnostic Radiology, Chuncheon Medical Center

²Department of Obstetrics and Gynecology, Chuncheon Medical Center

Isolated torsion of the fallopian tube is a rare disease entity that clinicians should consider in adolescents and reproductive females with pelvic pain. The disease is clinically significant and should be considered in the differential diagnosis of both acute and recurrent lower abdominal pain. If not treated in time, it can cause tissue gangrene and be fatal. The authors report the ultrasound and CT findings in a case of isolated fallopian tubal torsion.

Index words : Fallopian tubes, torsion
Fallopian tubes, US

Address reprint requests to : Hahm Jin-kyeung, M.D., Department of Diagnostic Radiology, Chuncheon Medical Center
#17-1 Hyoja 3-dong, Chuncheon, Kangwon-do, 200-093, Koera.
Tel. 82-361-258-2328, Fax. 82-361-51-0374