

MR Imaging of Focal Cervical Edema Mimicking Carcinoma : A Case Report¹

Jung Sik Kim, M.D., Hong Kim, M.D.

We describe the MR findings in a patient with stage-I carcinoma confined to the posterior lip of the uterine cervix, a "mass-like", separate, localized area of edema developed in the anterior lip. Preoperative MR imaging could not distinguish edema from tumor, through MR imaging of the surgical specimen edema from tumor on account of the higher signal intensity of the former. Histopathologic correlation is illustrated.

Index words : Uterus, abnormalities
Uterus, MR

Peritumoral edema appearing as a halo of increased signal intensity on T2-weighted MR images is known to occur in tumors of the brain, bone, soft tissue, and liver(1-3). We recently encountered a patient with stage-Ib cervical carcinoma confined to the posterior cervical lip; an area of focal mass-like edema in the anterior cervical lip was also discovered. Differing from the usual form of peritumoral edema that surrounds a tumor, it formed a globular mass that was separate from it, and this was determined by in-vitro MR imaging to be due to tumor extension. Postsurgical in-vitro MR findings obtained after radical hysterectomy were different, however, and corresponded closely to pathologic findings.

Case report

A 40-year-old woman with several months' history of irregular vaginal bleeding was referred for evaluation of a gross cervical lesion. Physical examination revealed a 2 × 2-cm cervical ulcerated mass on the posterior cervical lip. The anterior lip was described as bulbous, but did not involve by the neoplasm. Biopsy of the ulcer revealed poorly differentiated squamous

carcinoma. Using both pelvic phased-array and endorectal cervical coils with a 1.5-T magnet(GE Medical Systems, Milwaukee), MR was performed. The former was used to obtain axial T1-weighted (750/16 [TR/TE]) and fast spin-echo (FSE) T2-weighted (4500/126) axial and sagittal images (30-cm FOV, 5-mm (axial T2) and 8-mm (axial T1 and sagittal T2) slice thickness, 2-mm interslice gap, 256 × 256 matrix); the latter (Medrad, Pittsburgh) to obtain T1-weighted axial (500/15) and FSE T2-weighted (4500/105) axial and sagittal images (12-cm FOV, 3-mm (axial T2) and 4-mm (axial and sagittal T2) slice thickness, no interslice gap, 256 × 256 matrix). Two days after imaging, radical hysterectomy, bilateral salpingo-oophorectomy and pelvic lymphadenectomy were performed. MR images of the surgical specimen were obtained after storage in 10 % formalin solution for 16 hours. Using a 5-inch surface coil, T1-weighted axial (500/10) and FSE T2-weighted (4000/100) axial and sagittal images were obtained (8-cm (axial) and 13-cm (sagittal) FOV, 4-mm slice thickness, 0 (axial) and 1-mm (sagittal) interslice gap, 256 × 256 matrix).

In-vivo FSE T2-weighted MR images showed a large, high signal intensity mass (39 × 21 × 54mm) occupying both the anterior and posterior cervical lips(Fig. 1A, B, C): an irregular central cavity was noted in the mass involving the posterior lip, and several small cysts were demonstrated along the inner margin of the mass involving the anterior lip. On FSE T2-weighted in-vitro MR images, however, two separate masses were dem-

¹Department of Diagnostic Radiology, Keimyung University, Dongsan Medical Center

Received April 14, 1998; Accepted August 7, 1998

Address reprint requests to: Jung Sik Kim, M.D., Department of Diagnostic Radiology, Keimyung University, Dongsan Medical Center, # 194 Dongsan Dong, Chung Ku, Taegu, 700-712, Korea.

Tel. 82-53-250-7767 Fax. 82-53-250-7766

onstrated, one each in the anterior and posterior lip (Fig. 2A, B). The signal intensity of the anterior lesion was significantly higher than that of the posterior lesion and was similar to that of the cysts seen along the inner margin of the anterior lip. The size of the anterior and posterior cervical lip masses were $20 \times 17 \times 32\text{mm}$

and $28 \times 30 \times 42\text{mm}$, respectively.

After in-vitro MR imaging, the cervix was divided into ten serial sections at 4.5mm intervals in the same planes of the specimen as its MR images. Each section was embedded in paraffin and cut with a microtome to field "giant" histologic tissue sections well matched to

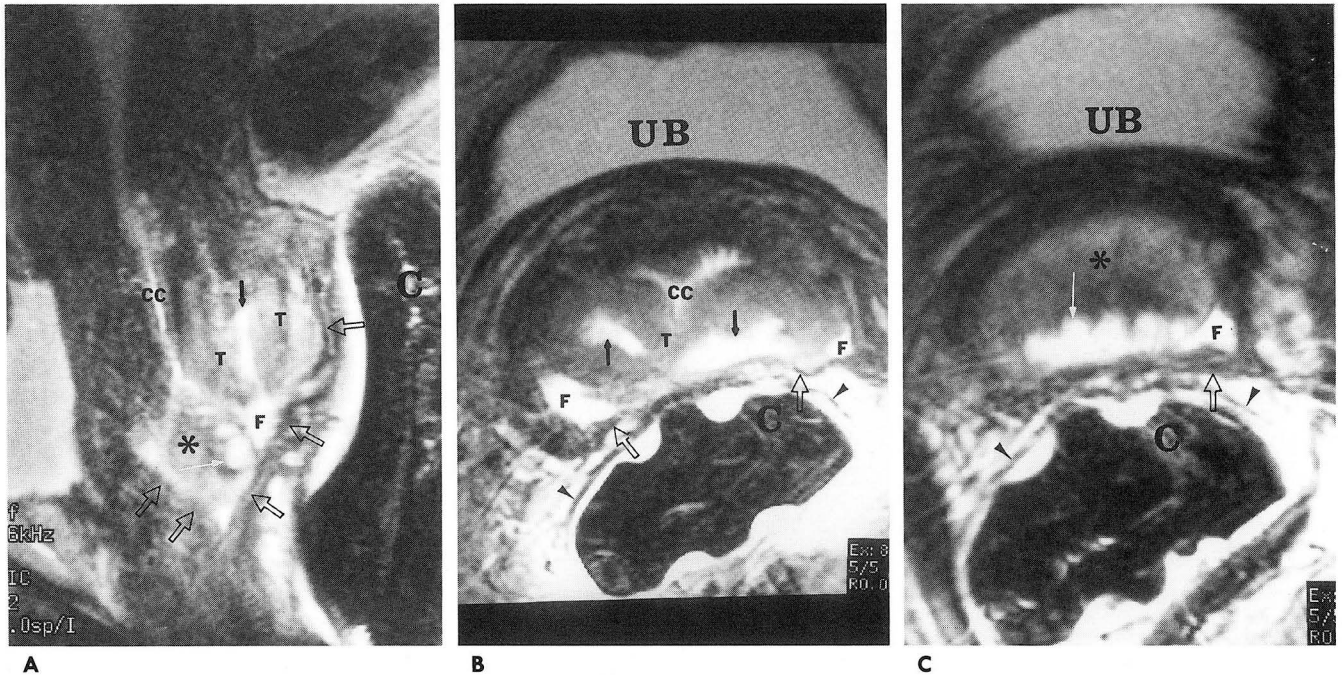


Fig. 1. In vivo MR images of 41-year old woman with stage-Ib cervical carcinoma.

A. Sagittal FSE T2-weighted image shows tumor (T) in posterior cervical lip with associated edema (*) and Nabothian cyst (white arrow) in anterior lip. Edema has similar signal intensity as tumor.

B. Axial FSE T2-weighted image through upper cervix shows tumor in posterior lip.

C. Axial FSE T2-weighted image through lower cervix shows edema in anterior lip with similar signal intensity as tumor.

C=endorectal cervical cell, CC=cervical canal, F=fluid, UB=urinary bladder, arrows=necrotic cavity, arrowheads=rectal wall, open arrows=vaginal wall

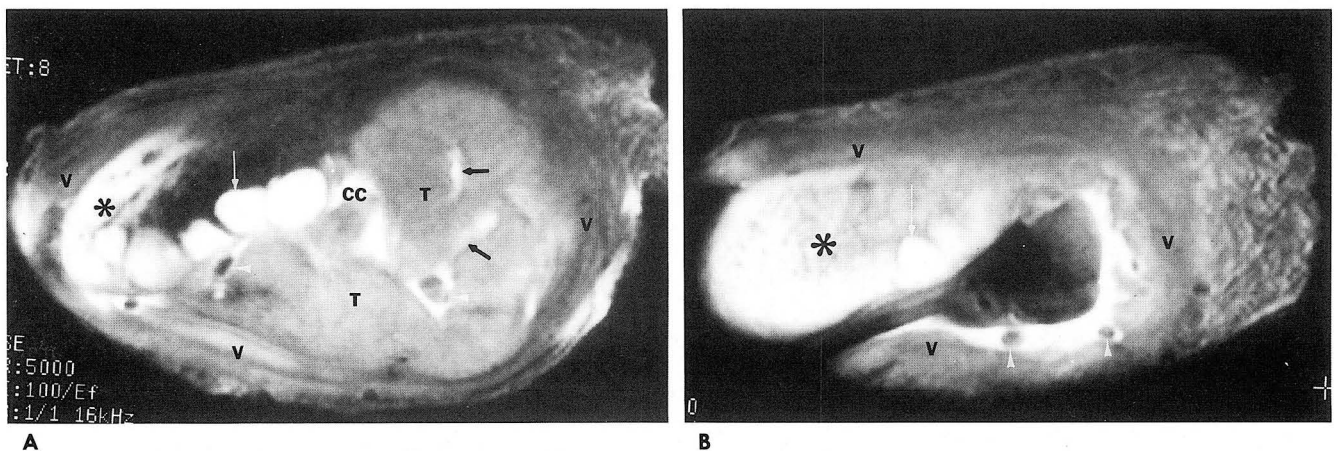


Fig. 2. In vitro MR images of the specimen.

A. Axial FSE T2-weighted image at same level as Fig. 1B shows tumor in the posterior cervical lip with lower signal intensity than edema.

B. Axial FSE T2-weighted image at same level as Fig. 1C shows only bright signal intensity of edema in anterior cervical lip.

V = vagina, white arrowheads = air bubbles

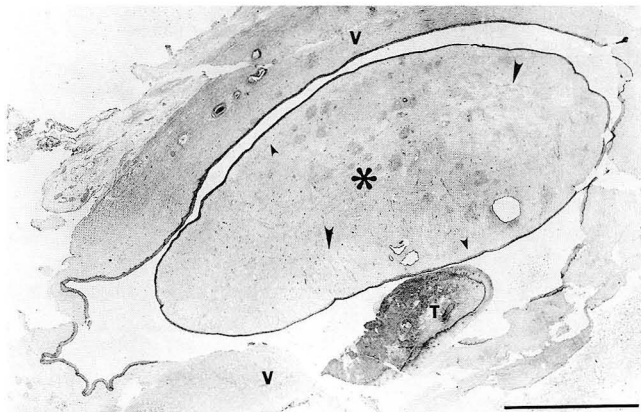


Fig. 3. "Giant" histological cross section of the anterior (*) and posterior (T) lips of the cervix and surrounding vaginal wall (V).

The anterior lip is approximately twice its normal size due to interstitial edema.

The edema is generalized, but is most notable as pale areas (large arrowheads) and beneath the epithelium (small arrowheads). The dark area in the posterior lip is the carcinoma. H & E stain. The scale=1 cm

the specimen MR imaging planes. A $28 \times 35 \times 35$ mm ulcerating tumor involving the posterior left cervical lip was found, corresponding closely to the posterior cervical lip mass seen on MR images of the in-vitro specimen. Microscopic examination showed moderately differentiated squamous cell carcinoma with a large central necrotic cavity. A thin rim of increased interstitial space, indicating edema, was noted along the tumor margin. A bulbous area ($18 \times 14 \times 34$ mm) in the anterior cervical lip, corresponding to the mass seen on MR images, was histologically normal except for the presence of interstitial edema (Fig. 3). Several Nabothian cysts, corresponding to the cysts seen on MR images, were demonstrated. In the surgically removed pelvic lymph nodes, no metastasis was demonstrated.

Discussion

Obstruction of lymph drainage is one of the most important causes of peritumoral edema (3, 4). The flow of water and protein from blood to the interstitium is normally balanced by the flow of lymph which carries water and protein back to the blood stream. However, because tumors lack a lymphatic system and compress lymphatic channels around them, edema usually develops within and around tumors (3, 4). In this patient, focal edema was demonstrated in an otherwise normal anterior cervical lip; it was separate from the carcinoma of the posterior lip. We believe, however, that this edema might have developed secondary to mass ef-

fect and lymphatic obstruction by the tumor, which involved 75% of the circumference of the cervix. Extensive lymphatic invasion was identified microscopically.

In-vivo MR images did not distinguish focal edema from tumor; both showed similar signal intensities on T1- and T2-weighted MR images. In retrospect, interpreting these in-vivo images while aware of the pathologic results, the Nabothian cysts located within the anterior cervical lip mass may help differentiate edema from tumors, which do not contain Nabothian cysts. On T2-weighted in-vitro MR images, however, edema was distinguished from the tumor on account of the higher signal intensity of the former. The difference between signal intensities of the anterior and posterior cervical masses and those of in-vitro MR images may be explained by the increased signal-to-noise ratio secondary to the close proximity of the specimen to the surface coil and the T2 prolongation effect of formalin (5, 6).

When determining the prognosis of cervical carcinoma, tumor volume is one of the most important factors (7). The treatment of stage-Ib cervical carcinoma varies according to tumor size; when the tumor is bulky, chemotherapy or radiotherapy is commonly used (8). The accurate evaluation of tumor size before initiating surgical treatment is therefore very important. Like us, other authors (9, 10, 11)-due to peritumoral edema and inflammation-overestimated tumor size. In our case, in-vivo MR images suggested it was twice as large as it in fact was.

Focal edema forming a globular mass similar in size to a tumor but separate from it is uncommon. In-vivo MR imaging could not distinguish edema from tumor, and on physical examination, clinicians noted that the tumor was not as large as it had appeared. If size and location of the tumor varies between clinical and MR imaging findings, re-evaluation of the imaging findings is therefore necessary, and the possibility that focal edema is mimicking the tumor should be considered.

References

1. Brant-Zawadzki M, Badami JP, Mills CM, Norman D, Newton TH. Primary intracranial tumor imaging: a comparison of magnetic resonance and CT. *Radiology* 1984;150:435-440
2. Kroon HM, Bloem JL, Holscher HC, van de Woude HJ, Reijnen M, Taminiau AHM. MR imaging of edema accompanying benign and malignant bone tumors. *Skeletal Radiol* 1994;23:261-269
3. Lee MJ, Saini S, Compton CC, Malt RA. MR demonstration of edema adjacent to a liver metastasis: pathologic correlation. *AJR* 1991;157:499-501

4. Steen RG. Edema and tumor perfusion: characterization by quantitative 1H MR imaging. *AJR* 1992; 158: 259-264
5. Auh YH, Lim TH, Lee DH et al. In vitro MR imaging of the resected stomach with a 4.7-T superconducting magnet. *Radiology* 1994; 191: 129-134
6. Kamman RL, Go KG, Stomp GP, Hulstaert CE, Berendsen HJC. Changes of relaxation times T1 and T2 in rat tissues after biopsy and fixation. *Magn Reson Imaging* 1985; 3: 245-250
7. Burghardt E, Hofmann HMH, Tamussino HK, Justich E, Ebner F, Haas J. Magnetic resonance imaging in cervical cancer: a basis for objective classification. *Gynecol Oncol* 1989; 33: 61-67
8. Kim DS, Moon H, Hwang YY, Cho SH. Preoperative adjuvant chemotherapy in the treatment of cervical cancer stage Ib, IIa and IIb with bulky tumor. *Gynecol Oncol* 1989; 29: 321-332
9. Hricak H, Lacey CG, Sandles LG, Chang YCF, Winkler ML, Stern JL. Invasive cervical carcinoma: comparison of MR imaging and surgical findings. *Radiology* 1988; 166: 623-631
10. Lien HH, Blomlie V, Kjorstad K, Abeler K, Kaalhus O. Clinical stage I carcinoma of the cervix: value of MR imaging in determining degree of invasiveness. *AJR* 1991; 156: 1191-1194
11. Sironi S, Belloni C, Taccagni G, DelMaschio A. Invasive cervical carcinoma; MR imaging after preoperative chemotherapy. *Radiology* 1991; 180: 719-722

대한방사선의학회지 1998; 39: 557-560

자궁경부암과 유사한 국소경부부종의 자기공명영상: 1예 보고¹

¹ 계명대학교 의과대학 방사선과학교실

김 정 식 · 김 홍

자궁경부의 후순(posterior lip)에 종양이 있는 환자에서 전순(anterior lip)에 국한된 종괴모양의 부종이 있었던 1례를 보고하고자 한다. 수술전 자기공명영상에서는 종양과 부종을 구별하지 못했으나 수술후 조직의 자기공명영상에서는 두 질환의 구별이 가능하였으며 조직 표본과 일치하였다.