

# Delayed Post-traumatic Collapse of the Vertebral Body (Kümmell disease) : Report of a Case with Serial Radiographs<sup>1</sup>

Son-Kwan Juhng, M.D., Jong-Jin Won, M.D.

Kümmell disease, the delayed post-traumatic collapse of the vertebral body, and its numerous postulated causes are discussed. A case is presented in which serial radiographs and magnetic resonance images demonstrate the presence of fracture and osteonecrosis.

**Index Words :** Spine, fractures  
Spine, injuries

In 1891, Kümmell described post-traumatic collapse of the vertebral body in which painful kyphosis developed in several patients after a symptom-free period of weeks to months following minor trauma(1, 2). Multiple theories of the pathogenesis of this collapse have been proposed. We report a case of Kümmell disease in which the radiographs and magnetic resonance (MR) images suggest the true mechanism.

## CASE REPORT

A 51-year-old man fell down from the roof(about 3 m high) of his house and had fractures of right proximal tibia and calcaneus as well as low back injury. Radiographs obtained at the time of injury showed mild to moderate collapse of L2 body(Fig. 1). Sequential plain radiographs 6 weeks after injury showed marked collapse of the L2 body and the presence of a vacuum phenomenon within the collapsed body(Fig. 2). Repeat plain radiographs(Fig. 3) and MR images(Fig. 4) 4 months after the fall were obtained because of progressively aggravating low back pain and paresthesia. MR images showed fracture through the body of L2 with posterior displacement of a bony fragment causing spinal narrowing.

## DISCUSSION

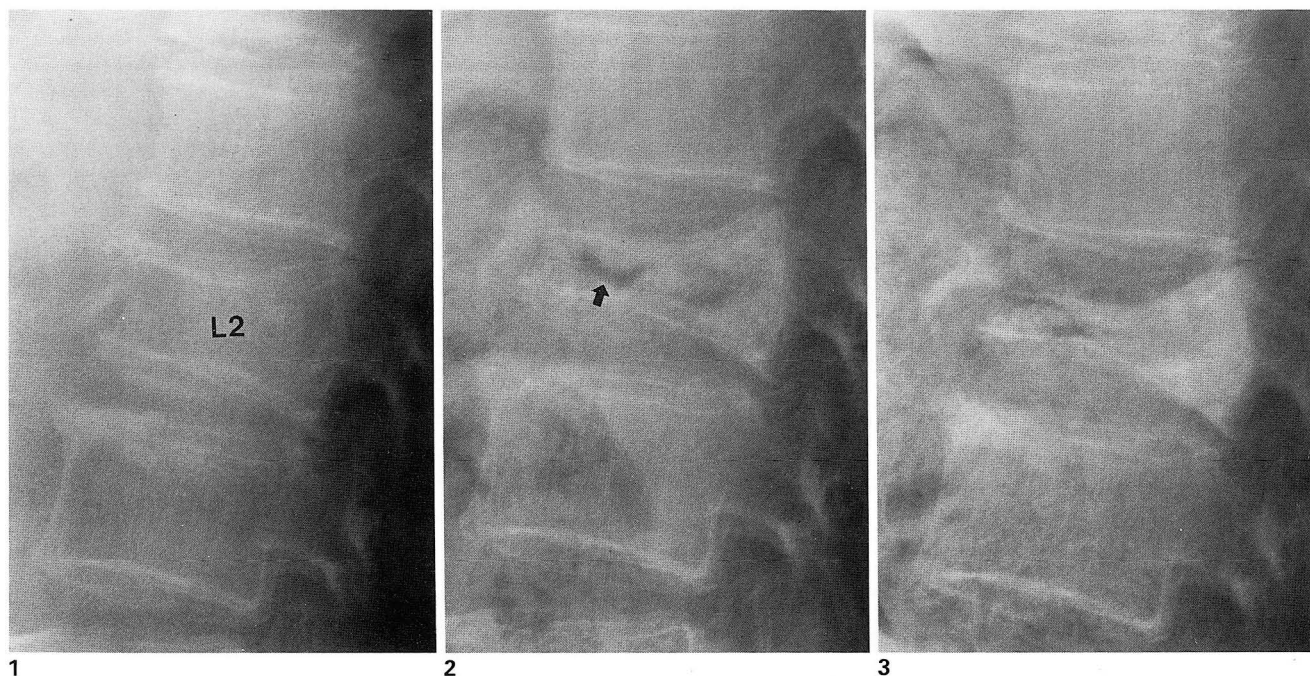
Kümmell reported the delayed post-traumatic vertebral collapses leading to gibbus deformity. In this

process there is no suppuration, as in the case of tuberculous spondylitis, or any condensations of the osseous masses, as in the case of luetic processes(1, 2). Subsequently, Schmorl and Junghanns, in 1926, provided pathologic observations supporting the concept of delayed posttraumatic collapse of vertebral bodies, although the nature of the underlying disease process was not clear(1). Since then nutritional, vasomotor, and neurologic disturbances, as well as various traumatic mechanism, have all been proposed as possible causes of the structural changes noted in the radiographs.

One of the interesting features of this patient is the intravertebral vacuum cleft. The intravertebral vacuum cleft corresponds to a gas like, radiolucent area within a transverse separation of the collapsed vertebral body. Vertebral collapse with vacuum cleft is thought to result from ischemic bone necrosis, because histologic signs of necrosis have been found in biopsy specimens(3) and because of the subchondral radiolucent line that can appear with traction in the case of hip osteonecrosis(4). However, in the case of vertebral body collapse with vacuum cleft, it is likely that bone ischemia may follow rather than precede vertebral collapse(5) or correspond to the development of pseudoarthrosis(6, 7).

The MR imaging appearance of avascular necrosis involving the vertebral body has been described(5, 8, 9). Naul et al(9) reported a horizontal area of markedly high signal intensity corresponding to the horizontal intravertebral area of lucency on radiographs on T2-weighted MR images. Since then, Malghem et al(5) found that the signal intensity of intravertebral vacuum cleft on T2- or T2\*-weighted or STIR images differed, depending on the duration of recumbency: The signal intensity within the cleft was low on the images ob-

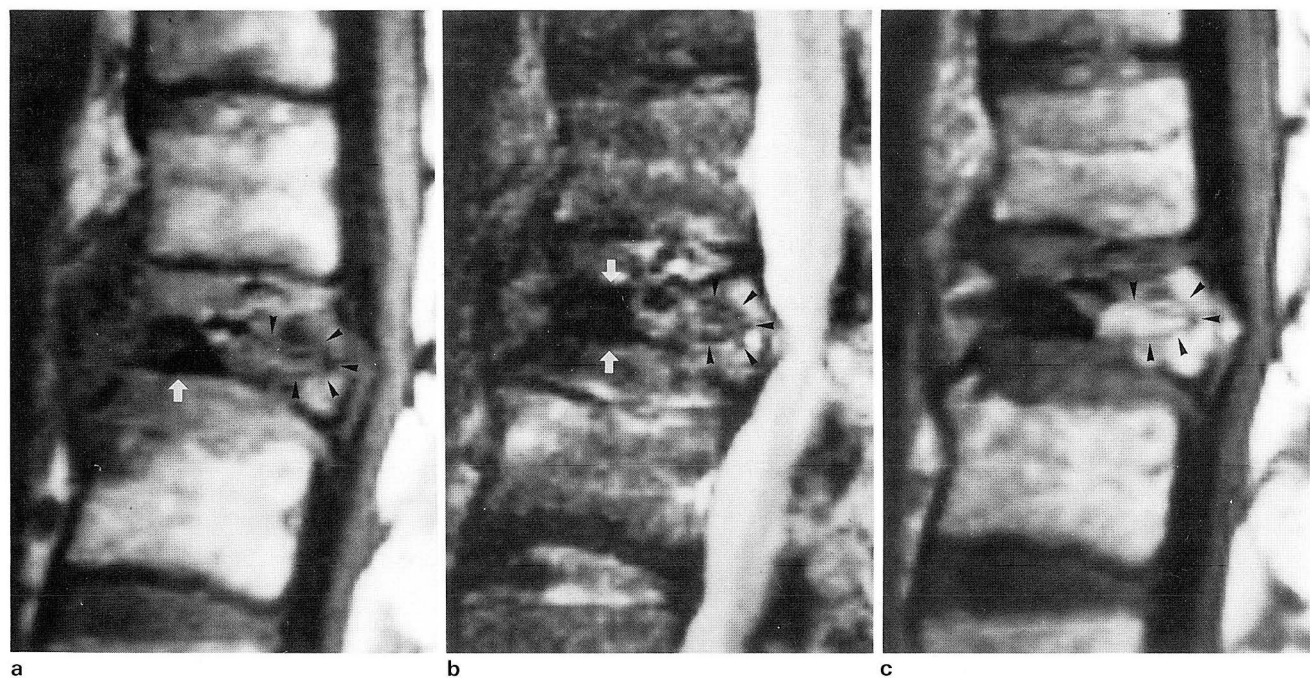
<sup>1</sup>Department of Radiology, Wonkwang University School of Medicine  
Received June 28, 1995 ; Accepted September 5, 1995  
Address reprint requests to : Seon-kwan Juhng, M.D., Department of Diagnostic Radiology, Wonkwang University School of Medicine  
# 344-2, Shinyong-dong, Iksan-city, Chonbuk, 570-180 Korea.  
Tel. 82-653-50-1514 Fax. 82-653-51-4749



**Fig. 1.** Initial lateral radiograph of the lumbar spine shows a mild to moderate anterior wedging of the second lumbar vertebra(L2) with a triangular bony fragment anterosuperiorly. The remaining vertebral bodies are normal.

**Fig. 2.** Repeat lateral examination 6 weeks after injury shows severe collapse of L2 body with a peculiar lucency extending into the vertebral body(arrow), and the body of L2 is slightly increased in density.

**Fig. 3.** Lateral examination 4 months after injury demonstrates further collapse and increased density in the body of L2.



**Fig. 4.** Sagittal T1-weighted(TR/TE, 600/15) (a) & T2-weighted (TR/TE, 2200/80) spin echo MR images(b) 4 months after injury reveal the collapsed vertebral body containing a signal void area(arrows) that correspond to the site of gas collection on plain radiograph, Fig. 3. Other portion of the vertebral body (arrow heads) shows portion of low signal on T1-weighted image, inhomogeneous high signal on T2-weighted image, and good enhancement on Gd-DTPA enhanced image(c) , indicating vascularized tissue. This may be due to viable fibrous mesenchymal or granulation tissue. Associated compression of the adjacent thecal sac by fragmented posterior aspect of the L2 body is evident.

tained immediately (less than 10 minutes) after supine positioning and was markedly high, suggestive of a fluid like content, after a prolonged time in the supine position. In addition to intravertebral vacuum cleft, we noted signal intensity of residual bone marrow changed according to pulse sequences; hypointense on T1-weighted images, inhomogeneous intermediate on T2-weighted images, and marked contrast enhancement on Gd-DTPA images. This same pattern has been reported in cases of avascular necrosis of the femoral head and is probably due to viable fibrous mesenchymal tissue (10).

Our case demonstrates that bone ischemia may follow vertebral fracture and that this accounts for the delayed post-traumatic vertebral collapse or Kümmell disease.

## REFERENCES

1. Brower AC, Downey EF, Jr. Kümmell disease: Report of a case with serial radiographs. *Radiology* **1981**; 141: 363-364
2. Resnick D, Niwayama G. *Osteonecrosis: Diagnostic techniques*, specific situations, and complications. In Resnick, eds. *Diagnosis of bone and joint disorders*. 3rd ed. Philadelphia: Saunders, **1995**; 3495-3558
3. Maldegue BE, Noel HM, Malghem JJ. The intravertebral vacuum cleft: A sign of ischemic vertebral collapse. *Radiology* **1978**; 129: 23-29
4. Martel W, Poznanski AK. The effect of traction on the hip in osteonecrosis. *Radiology* **1970**; 94: 505-508
5. Malghem JJ, Maldague B, Labaisse MA, et al. Intravertebral vacuum cleft: Changes in content after supine positioning. *Radiology* **1993**; 187: 483-487
6. Bretz WG, Jenkins RG. Gas density in an ununited fracture of a vertebral body. *J Bone Joint Surg[Am]* **1981**; 129: 1183-1184
7. Kumpan W, Salmonowitz E, Seidl G, Wittich GR. The intravertebral vacuum phenomenon. *Skeletal Radiol* **1986**; 15: 444-447
8. Lee SM, Suh SJ, Suh KJ. MR findings of intravertebral vacuum cleft: Report of two cases. *Journal of the Korean Radiological Society* **1994**; 31: 31-34
9. Naul LG, Peet GJ, Maupin WB. Avascular necrosis of the vertebral body: MR imaging. *Radiology* **1989**; 172: 219-222
10. Vande Berg BE, Malghem JJ, Labaisse MA, Noel HM, Maldegue BE. MR imaging of avascular necrosis and transient marrow edema of the femoral head. *RadioGraphics* **1993**; 13: 501-520

대한방사선의학회지 1995; 33(3): 429~431

## 외상성 척추체 지연허탈 (Kümmell 씨 병): 추적 단순 촬영 소견 (1예 보고)<sup>1</sup>

<sup>1</sup>원광대학교 의과대학 진단방사선과학교실

정 선 관 · 원 종 진

Kümmell 씨 병은 외상후 어느 정도 기간이 지난후에 척추체가 점차 심해지는 허탈을 보이는데, 정확한 기전은 알려져 있지 않다. 추적 단순 촬영 사진과 자기공명영상에서 척추체의 압박 골절후 무혈성 괴사에 의해 지연 허탈을 보인 1예를 보고한다.

## 국제 학술대회 일정표 [ I ]

- 1996/01/08-12 Radioactive Isotopes in Clinical Medicine and Research-Int. Symposium**  
 venue: Kongresszentrum Badgastein, Austria.  
 contact: Prof. Dr. H. Bergmann, Dept. of Nuclear Medicine,  
 Waehringer Guertel 18-20, A-1090 Vienna, Austria.
- 1996/01/18-21 MRI 1996: Ortho Weekend Review**  
 venue: The Westin Hotel Cincinnati, Ohio, USA.  
 contact: Stephen J. Pomeranz, M.D., MRI Education Foundation,  
 2600 Euclid Avenue, Cincinnati, OH 45219-2199, USA.  
 (tel: 1-513-2813400; fax: 1-513-2813420)
- 1996/01/29-01 8th Annual Int. Symposium on Vascular Diagnosis and Intervention**  
 venue: Fontainebleau Hilton Res. Miami Beach, Florida, USA.  
 contact: Miami Vascular Institute, Baptist Hospital,  
 8900 North Kendall Drive, Miami, Florida 33176, USA.  
 (tel: 1-305-5985992; fax: 1-305-2703600)
- 1996/02/01-05 XXX Annual Course of Radiology**  
 venue: Distrito Federal, Mexico.  
 contact: Dr. J.A. Perez Medizabal, Soc. Mexicana de Radiol.,  
 Coahuila No. 35, Col. Roma C.P. 06700 Mexico, D.F., Mexico.  
 (tel: 52-5-5745250; fax: 52-5-5742434)
- 1996/02/05-08 Nicer Southeast Asia Program: Musculoskeletal Radiology and Breast Imaging**  
 venue: Kuala Lumpur, Malaysia.  
 contact: The NICER Institute, att. Kristin Sandvik,  
 Postboks 4462 Torshov, N-0401 Oslo, Norway.  
 (tel: 47-22-891867; fax: 47-22-891210)
- 1996/02/13-14 Sandwichcursus Neuroradiologie/KNO-1e Cursus**  
 venue: The Netherlands.  
 contact: Mrs. F.E. Blommendaal, NVvRd,  
 P.O. Box 8171, 3503 RD Utrecht, The Netherlands.  
 (tel: 31-30-474294; fax: 31-30-474439)
- 1996/02/15-16 Sandwichcursus Neuroradiologie/KNO-2e Cursus**  
 venue: The Netherlands.  
 contact: MRS. F.E. Blommendaal, NVvRd,  
 P.O. Box 8171, 3503 RD Utrecht, The Netherlands.  
 (tel: 31-30-474294; fax: 31-30-474439)
- 1996/02/18-22 Annual Meeting and Course Society of Thoracic Imaging**  
 venue: The Ritz-Carlton Hotel Mauna Lani (Kona), Hawaii, USA.  
 contact: Dawne Ryals, Ryals & Associates,  
 P.O. Box 1925, Roswell, GA 30075-1925, USA.  
 (tel: 1-404-6419773; fax: 1-404-5529859)

제공 : 대한방사선의학회 국제협력위원회