

Giant Fibrovascular Polyp of the Esophagus : A Case Report¹

Jae Wook Ryoo, M.D., Jeung Sook Kim, M.D., Kyung Soo Lee, M.D.,
Jae Hoon Lim, M.D., Young Mog Shim, M.D.², Joung-ho Han, M.D.³

Fibrovascular polyp of the esophagus is a rare and benign pedunculated intraluminal tumor. The tumor consists of varying amount of vascular fibrous and adipose tissue that arises in the submucosa and is covered by squamous epithelium. We report the typical radiographic, CT and MR findings of a case of giant fibrovascular polyp of the esophagus.

Index Words : Esophagus, CT
Esophagus, MR
Esophagus, neoplasms

INTRODUCTION

Fibrovascular polyp of the esophagus is a rare and benign pedunculated intraluminal tumor. Microscopically the tumor consists of varying amount of vascular fibrous and adipose tissue that arises in the submucosa and is covered by squamous epithelium (1-5). Grossly the tumor is usually lobulated or club-like in shape, but the stalk is often comparatively thin (6).

Because surgical removal (cervical esophagotomy rather than thoracotomy even in patient with a large tumor) is the treatment of choice (6), exact determination of the site of pedicular attachment is important to the surgeons for planning the surgical approach. However, demonstration of pedicle is difficult and has been sometimes impossible on esophagogram even when the true nature of the lesion was known to the examiner beforehand (1-6). Cross sectional image modalities may be useful in the detection of the site of pedicular attachment. In this case report, we illustrate the typical radiographic, CT, and MR findings of a large fibrovascular polyp of the esophagus, emphasizing the role of cross-sectional images in the detection of the pedicle of the tumor.

CASE REPORT

A 52-year-old man complained of vomiting and feeling of tightness in the hypopharynx for 2 months with weight loss of 7 Kg during 3 months. Esophagoscopy was interpreted as normal. Esophagogram demonstrated contrast-filled dilated lumen throughout the esophagus. There were some areas of filling defects within the lumen with variable shape (Fig. 1a). CT scan demonstrated a soft tissue lesion in the esophagus from the level of thoracic inlet down to the level of gastroesophageal junction. The central portion of the lesion showed attenuation identical to that of subcutaneous fat whereas the peripheral portion showed that of chest wall muscle (Fig. 2b). At the level of aortic arch vessels, there was a polypoid soft tissue lesion arising from the posterolateral wall of the esophagus (Fig. 1c), suggesting the stalk of the lesion connected to the main mass cephalad and caudad. On T1-weighted MR images (TR/TE, 1791/17), the mass showed high-intensity signal centrally and low-intensity signal similar to the chest wall peripherally (Fig. 1d). On T2 weighted images (TR/TE, 3380/60), the signal was reversed with central low- and peripheral high-intensity signal (Fig. 1e). Because the tumor was considered too large to be resected by cervical esophagotomy and there was no confidence on the exact site of the pedicle, thoracotomy was performed. On operation field, there was a large, lobulated, intraluminal protruding mass covered with normal mucosa. The dimension of the mass was about 20 × 5 × 4 cm in size. It was pedunculated with thin stalk at arch vessel level as shown on CT scan. The histological feature was that of

¹Department of Diagnostic Imaging, Samsung Medical Center

²Department of Thoracic Surgery, Samsung Medical Center

³Department of Diagnostic Pathology, Samsung Medical Center

Received May 8, 1995; Accepted July 24, 1995

Address reprint requests to: Kyung Soo Lee, M.D., Department of Diagnostic Imaging, Samsung Medical Center, # 50 Irwon-Dong, Kangnam-Ku, Seoul, 135-230 Korea. Tel. 82-2-3410-2511, 2516 Fax. 82-2-3410-2559

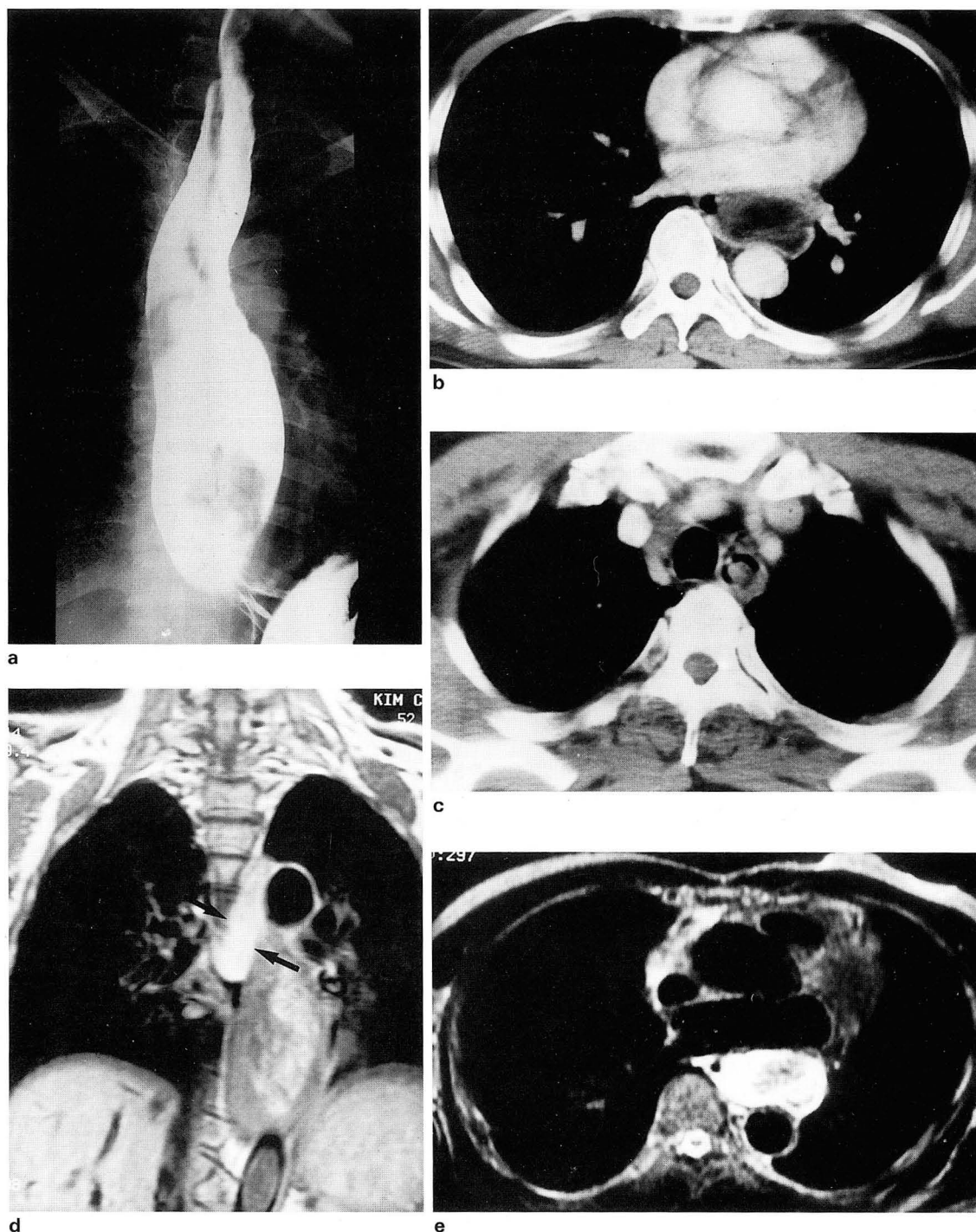


Fig. 1. A giant fibrovascular polyp in a 52-year-old man.

a. Esophagogram shows contrast-filled dilated lumen. There are several foci of filling defect with variable shape.

b. Enhanced conventional (10 mm collimation) CT scan obtained at level of inferior pulmonary vein shows heterogeneous soft tissue lesion in esophageal region. Central portion of the lesion shows fatty attenuation whereas peripheral portion shows soft tissue attenuation similar to thoracic muscles. Esophageal gas is seen right lateral to main lesion.

c. CT scan obtained at level of arch vessels shows round polypoid soft tissue lesion arising from posterolateral wall of esophagus. Posterolateral wall of esophagus per se is thickened. This portion was presumed to be pedicle preoperatively, which was confirmed on surgery.

d. Coronal T1-weighted (TR/TE, 1791/17) MR image shows elongated lesion involving the entire esophagus. Lesion is composed of central high-intensity signal and peripheral low-intensity signal similar to that of chest wall. Lesion with high-intensity signal (arrows) is also noticed superiorly right lateral to aortic arch.

e. Transaxial T2-weighted (TR/TE, 3380/60) image shows reversed nature of signal. Central portion shows low-intensity signal whereas peripheral portion shows high-intensity signal.

fibrovascular polyp without foci of malignant degeneration. Fat could be observed in the central portion of the lesion as was shown in CT and MR. The postoperative course and healing were uneventful.

DISCUSSION

Benign tumors of the esophagus are uncommon, accounting for about 17% of all esophageal neoplasms (3). These tumors are typically classified as intramural or intraluminal (1-3); leiomyoma and neurofibroma are representative of the former and fibrovascular polyp is of the latter. Most intraluminal tumors are pedunculated with a narrow stalk and may be diagnosed histologically as fibrovascular polyps. Malignant degeneration of a true benign fibrovascular polyp has never been reported (3). A variety of pathologic terms, including myxomas, myxofibromas, polypoid lipomas, and fibrolipomas, have been employed in the literature to classify these unusual lesions because of their heterogeneous microscopic appearance (3).

Fibrovascular polyps arise from the submucosal layer of the esophageal wall and are covered by normal mucosa. They might start as small tumors which, when growing, are gradually gripped by the peristalsis of the esophagus and become pedunculated by that mechanism (6).

The reported esophagographic finding of the tumor is oval-shaped or elongated sausage-like masses with usually smooth but sometimes lobulated surface (1, 2, 4-8). The mucosa of the tumor as well as that of the esophageal wall are usually quite normal although the folds are flattened or have disappeared due to dilatation of the esophagus harboring a large intraluminal mass (1-6). The surface of the latter may be grossly irregular, giving the impression that it is divided into two or more separate entities. No real obstruction to the contrast medium is usually encountered even when the tumor is large.

CT with its inherent high spatial resolution may be helpful in the management of the disease by determining the site of pedicular attachment of the tumor (1, 7, 8). By showing the exact site of pedicular attachment on CT scans, surgeons can perform resection of the tumor confidently by cervical esophagotomy. CT and MR are also useful in characterization of the lesion by

showing the fat and soft tissue which are the main components of the tumor (8).

Fibrovascular polyp of the esophagus often grows to be very large before symptoms appear. Symptoms include dysphagia, upper gastrointestinal bleeding due to ulceration of the tumor, epigastric or substernal pain, and respiratory symptoms, including asphyxia, cough, and pulmonary infections. The sudden appearance of a mass in the mouth is a fairly frequent single sign (3). The prognosis is excellent, however, if they are left undiagnosed and untreated, the prognosis might be grave owing to progressive emaciation of the patient, complications from the airway obstruction due to a prolapsed tumor and lethal bleeding from the tumor due to erosions and ulcerations (6).

It is noteworthy that the presence of even a large intraluminal tumor may escape detection at esophagoscopy as in our case. The tumor is in most cases covered by normal mucosa and the endoscopic picture can resemble that of a wide and folded esophagus mimicking achalasia or cardiospasm (6). Especially the large variety of pedunculated tumors often are difficult to detect endoscopically even when an intraluminal mass has been demonstrated radiologically.

REFERENCES

1. Walters NA, Coral A. Fibrovascular polyp of the esophagus: the appearances on computed tomography. *Br J Radiol* **1988**;61: 641-643
2. Jang GC, Clouse ME, Fleischner FG. Fibrovascular polyp: a benign intraluminal tumor of the esophagus. *Radiology* **1969**;92: 1196-1200
3. Taff LT, Schwartz IS, Boglioli LR. Sudden asphyxial death due to a prolapsed esophageal fibrolipoma. *Am J Forensic Med Pathol* **1991**;12: 85-88
4. Burrell M, Toffler R. Fibrovascular polyp of the esophagus. *Dig Dis* **1973**;18: 714-718
5. Patel J, Kieffer RW, Martin M, Avant GR. Giant fibrovascular polyp of the esophagus. *Gastroenterology* **1984**;87: 953-956
6. Elner A, Palm NG. Pedunculated intraluminal fibro-lipoma of the esophagus: case report. *Acta Otolaryngol* **1976**;82: 457-462
7. LeBlanc J, Carrier G, Ferland S, Boutet M. Fibrovascular polyp of the esophagus with computed tomographic and pathologic correlation. *Can Assoc Radiol J* **1990**;41: 87-89
8. Whitman GJ, Borkowski GP. Giant fibrovascular polyp of the esophagus: CT and MR findings. *AJR* **1989**;152: 518-520

식도의 거대 섬유혈관용종:1예 보고¹

¹삼성의료원 진단방사선과, ²삼성의료원 흉부외과

³삼성의료원 진단병리과

유재욱 · 이경수 · 김정숙 · 임재훈 · 심영목² · 한정호³

식도의 거대 섬유혈관용종은 양성의 드문 강내종양으로, 이 종양은 점막하에서 생기며 혈관 섬유조직과 지방조직의 다양한 비율로 구성되어 있고 편평상피세포로 싸여 있다. 이 종양은 가는 줄기 (stalk)를 가지는 것이 특징으로, 큰 종양을 가진 환자의 경우도 흉부절개술보다 경부식도절개술로 치료가 가능하다.

52세 남자 환자가 2달간의 구토와 하인두 압박감을 주소로 내원하였고, 식도조영술, 컴퓨터전산화단층촬영 및 자기공명영상에서 전형적인 소견을 보인 식도의 거대 섬유혈관용종 1예를 경험하였기에 보고한다.