

Value of the Left Portal Vein Angle (LPVA) on CT for the Diagnosis of Liver Cirrhosis : Comparison with the Caudate to Right Lobe (C/RL) Ratio¹

Yoong Ki Jeong, M.D., Byung Ihn Choi, M.D., Joon Koo Han, M.D.,
Hong Dae Kim, M.D., Kyung Mo Yeon, M.D.

Purpose : To verify the usefulness of left portal vein angle (LPVA) on CT scan in the diagnosis of liver cirrhosis and to compare its diagnostic value with that of caudate to right lobe ratio (C/RL ratio).

Materials and Methods : LPVA, an angle formed by a vertical line and a line connecting the center of the vertebral body to the umbilical point of the left portal vein, and C/RL ratio were measured on CT scans of 100 cirrhotic and 100 normal livers. Diagnostic values of LPVA and C/RL ratio were compared statistically.

Results : The mean of LPVA was 18.9° (SD ; 7.6) for normal livers and 25.8° (SD ; 8.4) for cirrhotic livers ($P < 0.001$). The mean of C/RL ratio was 0.47 (SD ; 1.10) for normal livers and 0.58 (SD ; 0.14) for cirrhotic livers ($P < 0.001$). When LPVA was greater than 30°, liver cirrhosis was diagnosed with 36% sensitivity and 92% specificity. When C/RL ratio was greater than 0.60, the diagnose of liver cirrhosis was with 41% sensitivity and 90% specificity. There was no significant difference of the diagnostic accuracy between LPVA and C/RL ratio in ROC analysis.

Conclusion : Both LPVA and C/RL ratio are useful diagnostic indices of liver cirrhosis on CT scan. LPVA is more convenient to measure than C/RL ratio.

Index Words : Liver, CT

Liver, cirrhosis

Computed tomography(CT), clinical effectiveness

INTRODUCTION

Liver cirrhosis is an irreversible alteration of lobular and vascular architecture of the liver, consisting of diffuse parenchymal necrosis, active formation of connective tissue leading to hepatic fibrosis and nodular regeneration (1). It is common end response of the liver to a variety of insults and injuries including alcohol abuse and viral infection.

Although diagnosis of liver cirrhosis is a pathologic diagnosis made by performing a needle biopsy, imaging diagnosis has been attempted. Ultrasonography is a modality widely used in the evaluation of chronic liver disease. But, the sonographic features of liver cirrhosis are nonspecific. There is a significant

sonographic overlap between liver cirrhosis and other diffuse parenchymal liver diseases ; decreased beam penetration through the liver, poor depiction of the intrahepatic vessels, and increased parenchymal echogenicity are seen in both disorders (2-6). On CT scan, several hepatic morphologic changes have been reported as strongly suggestive of cirrhosis ; decrease of the overall liver volume, nodularity of the liver contour caused by regenerating nodules, fibrous scarring, and nonuniform lobar atrophy and/or hypertrophy (7-10). But, there are not generally accepted objective indices for the diagnosis of liver cirrhosis. Harbin et al. (11) proposed a ratio of transverse caudate lobe width to right lobe width (C/RL ratio) on CT scan, representing relative atrophy of the right hepatic lobe and enlargement of caudate lobe in cirrhotic liver, as an objective diagnostic index of liver cirrhosis. They reported that if C/RL ratio exceeds 0.65, the diagnosis of liver cirrhosis can be made with 100% specificity, and 94% accuracy which approach those of percutaneous liver biopsy. But, there is a technical pitfall in obtaining C/RL ratio. If the main portal vein is oriented trans-

¹Department of Radiology, Seoul National University College of Medicine

Received June 8, 1995 ; Accepted May 12, 1995

Address reprint requests to : Byung Ihn Choi, M.D., Department of Radiology, Seoul National University Hospital, # 28, Yongon-dong, Chongno-gu, Seoul, 110-744 Korea. Tel. 82-2-760-2584 Fax. 82-2-743-6385

versely, with its horizontal axis almost directly continuous with the axis of the right portal vein, the right lateral wall of the main portal vein can not be marked exactly; therefore, measurement of C/RL ratio is difficult. Another problem, which makes C/RL ratio not to be used widely in practice, is that it requires mathematical calculation.

The purpose of this study is to propose LPVA, representing position of the umbilical portion of the left portal vein, as a new diagnostic index of liver cirrhosis on CT scan, which can be easily obtained and used. This study will also determine its diagnostic efficacy by comparing with that of C/RL ratio.

MATERIALS and METHODS

The control group was composed of 100 normal healthy subjects. They were 64 men and 36 women. The age ranged from 27 to 73 years with mean age of 55. The study group was composed of 100 patients with liver cirrhosis. They were 73 men and 27 women. The age ranged from 32 to 71 years with mean age of 55.

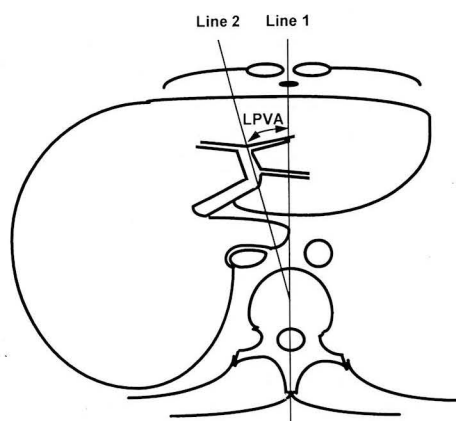


Fig. 1. Method of obtaining left portal vein angle (LPVA). The angle between line 1 and line 2, is defined as LPVA.

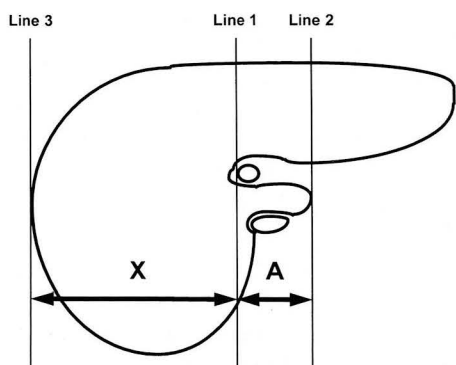


Fig. 2. Method of obtaining caudate to right lobe (C/RL) ratio. The distances between lines 1 and 2 (A), and between lines 1 and 3 (X) were measured and expressed as A/X (C/RL ratio).

The diagnosis of cirrhosis in each patient was based on clinical features, CT findings except LPVA and C/RL ratio ($n=82$), and histopathological examination ($n=18$). Clinical features included esophageal varix on endoscopy ($n=58$), history of ascites ($n=34$), and abnormal liver function test ($n=67$). CT findings included nodularity of liver contour ($n=60$) and splenomegaly ($n=52$). Among 100 patients with cirrhosis, 76 were considered to be related to hepatitis B virus (HBV), 12 hepatitis C virus (HCV), and three alcoholism. In nine cases, a definite cause could not be determined (cryptogenic cirrhosis).

All CT scans were performed with a GE 9800 scanner (GE Medical Systems, Milwaukee, USA) and a Somatom Plus-S scanner (Siemens, Erlangen, FRG). Contiguous ten millimeter sections through the liver were obtained after intravenous bolus injection of 100 mL of

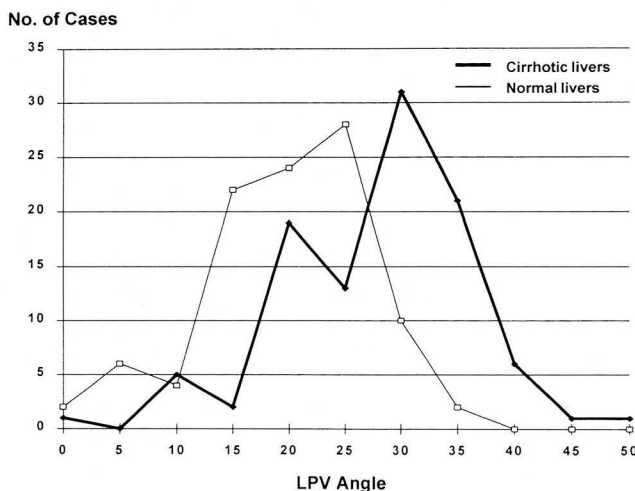


Fig. 3. Graph illustrates the distribution of LPVAs for 100 cirrhotic and 100 normal livers.

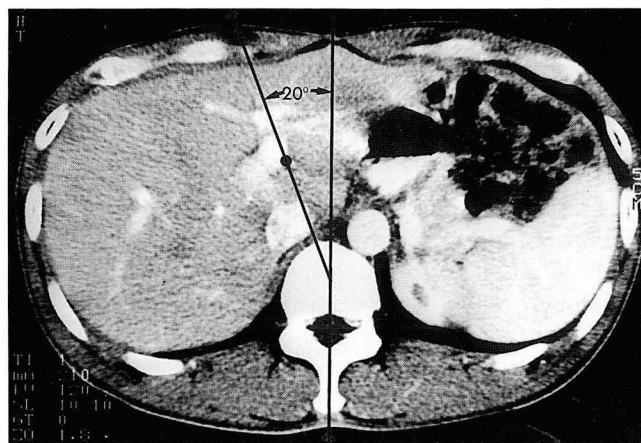


Fig. 4. LPVA is determined by a line drawn through the center of the vertebral body to the umbilical point of the left portal vein and a vertical line drawn through the center of the rectus abdominis muscle to the spinous process of the vertebra. The angle measures 20° on this CT scan of a normal healthy subject. ●; umbilical point

meglumine iogliclate 68% (Rayvist 300, Schering AG, FRG).

Radiologic analysis

Measurements were obtained from hard copy images of each liver. The left portal vein was identified and its umbilical point was determined. The main portal vein and its level of bifurcation was also examined, and if the vein appeared to bifurcate between adjacent scans, the more caudal scan was chosen.

Left Portal Vein Angle (LPVA): A line (Fig. 1, line 2) was drawn connecting the center of the vertebral body to the umbilical point of the left portal vein. A vertical line (Fig. 1, line 1) was drawn connecting the center of the rectus abdominis muscle to the spinous process of the vertebra. The angle between line 1 and line 2 was measured and defined as LPVA.

Caudate to Right Lobe ratio using the main portal vein (C/RL ratio): A line (Fig. 2, line 1) was drawn parallel to the midsagittal plane through the right lateral

parallel to the midsagittal plane through the right lateral wall of the main portal vein. A second line (Fig. 2, line 2) was drawn parallel to the line 1 through the most medial margin of the caudate lobe. A third line (Fig. 2, line 3) was drawn parallel to the line 1 through the most lateral margin of the right lobe. The distances between lines 1 and 2 (A), and between lines 1 and 3 (X) were measured and expressed as the ratio A/X (C/RL ratio). This method was same as that of Harbin (11).

Statistical analysis

The mean values and standard deviations (SDs) of LPVA and C/RL ratio of normal and cirrhotic livers were calculated, and Student's t-test was used to evaluate the statistical difference between normal and cirrhotic livers. Using decision-matrix analysis (12), sensitivity, specificity, and diagnostic accuracy were

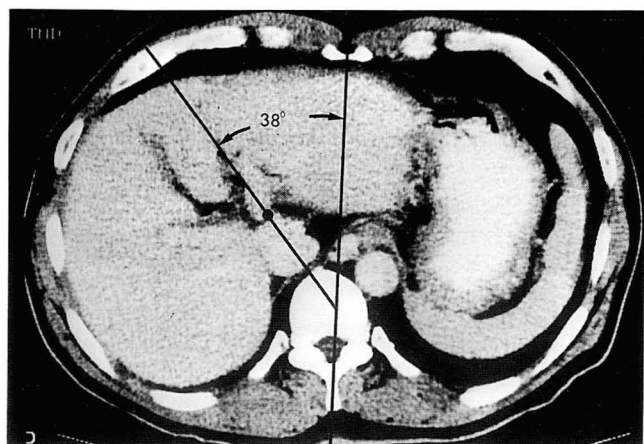


Fig. 5. CT scan of a 60-year-old patient with liver cirrhosis shows the lateral displacement and counterclockwise rotation of the umbilical portion of the left portal vein and large LPVA (38°). ● ; umbilical point

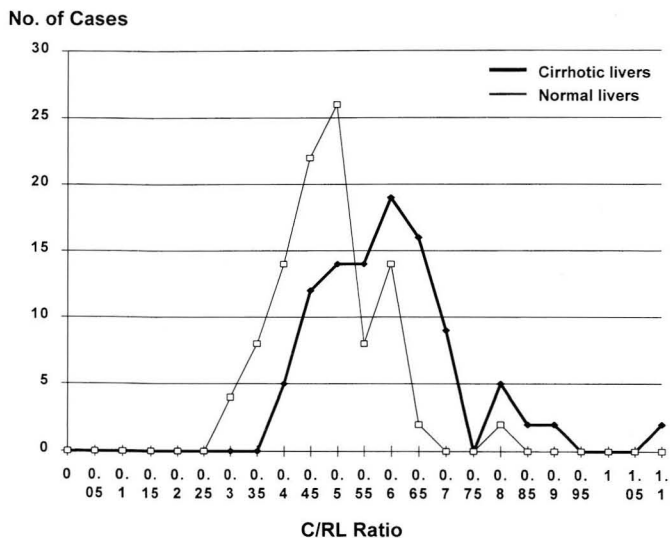


Fig. 6. Graph illustrates the distribution of C/RL ratios for 100 cirrhotic and 100 normal livers.

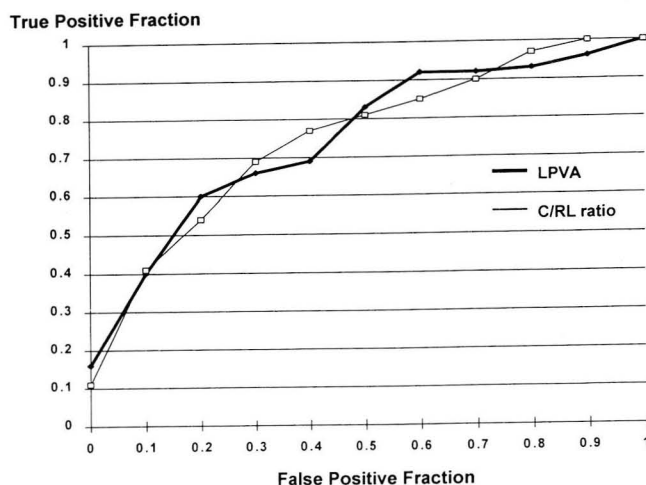


Fig. 7. ROC curves of LPVA and C/RL ratio. The vertical scale is the true positive ratio (i. e., the sensitivity) and the horizontal scale, the false positive ratio (i. e., 1-specificity).

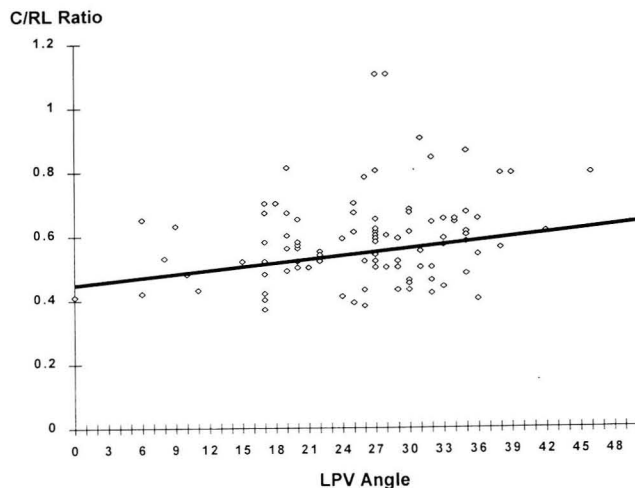


Fig. 8. Scattergram superimposed with regression line shows correlation between LPVA and C/RL ratio.

calculated, respectively. The diagnostic value of LPVA was compared with that of C/RL ratio by means of receiver operating characteristic (ROC) analysis, a well-established technique for comparing the performance of diagnostic systems (13).

RESULTS

LPVAs for all 100 cirrhotic and 100 normal livers were shown in Fig. 3. The mean was 18.9° (SD; 7.6°) for normal livers and 25.8° (SD; 8.4°) for cirrhotic livers (Fig. 4, 5). There was a significant statistical difference of LPVA between patients with cirrhosis and normal subjects ($P < 0.001$).

C/RL ratios for all 100 cirrhotic and 100 normal livers were shown in Fig. 6. The mean was 0.47 (SD; 0.10) for normal livers and 0.58 (SD; 0.14) for cirrhotic livers. There was a significant statistical difference of C/RL ratio between patients with cirrhosis and normal subjects ($P < 0.001$).

If a LPVA of more than 30° and a C/RL ratio of more than 0.60 were considered to be positive for the diagnosis of the cirrhosis, liver cirrhosis can be diagnosed with high specificity (Table 1, 2).

ROC curves of LPVA and C/RL ratio were obtained (Fig. 7). The areas under the curves are 75% for LPVA and 75% for C/RL ratio. There was no significant difference between ROC curve of LPVA and that of C/RL

ratio. Plot of correlation between LPVA and C/RL ratio was obtained also (Fig. 8). LPVA weakly correlated with C/RL ratio (correlation coefficient; 0.23, $P < 0.05$).

DISCUSSION

Relative atrophy of the right hepatic lobe and the medial segment of the left hepatic lobe, and enlargement of the lateral segment of the left hepatic lobe in cirrhosis have been described through volumetric measurement on CT scan (10). Because the umbilical portion of the left portal vein passes between the lateral and medial segment of the left hepatic lobe, the alteration in the position of the umbilical portion of the left portal vein can be anticipated in cirrhotic patients, resulting in increase of LPVA. In liver cirrhosis, there are gross alterations in the intrahepatic blood flow and the formation of numerous pathologic intrahepatic portocaval shunts (14-16). The increase or decrease in volume of portions of the liver could be explained by abnormal distribution of the portal blood, rich in hepatotrophic factors, insulin being one of the most important, which enter the liver by way of the splanchnic circulation (17, 18).

Our study indicates that both LPVA and C/RL ratio could be used in the diagnosis of the liver cirrhosis on CT scan with a considerable specificity. But, C/RL ratio did not reveal such a high sensitivity and accuracy as

Table 1. Decision Matrix Analysis(LPVA)

| Positive test for cirrhosis = LPVA $\geq 30^\circ$ | | | Positive test for cirrhosis = LPVA $\geq 25^\circ$ | | |
|--|----------------|----------------|--|----------------|----------------|
| | Cirrhosis(+) | Cirrhosis(-) | | Cirrhosis(+) | Cirrhosis(-) |
| Test(+) | 36 | 8 | Test(+) | 64 | 26 |
| Test(-) | 64 | 92 | Test(-) | 36 | 74 |

| Nosologic Probabilities | | | Nosologic Probabilities | | |
|-----------------------------|--|--|-----------------------------|--|--|
| Sensitivity = 36% (36/100) | | | Sensitivity = 74% (74/100) | | |
| Specificity = 92% (92/100) | | | Specificity = 74% (74/100) | | |
| Accuracy = 64% (128/200) | | | Accuracy = 69% (138/200) | | |

LPVA = Portal Vein Angle

Table 2. Decision Matrix Analysis(C/RL Ratio)

| Positive test for cirrhosis = C/RL ratio ≥ 0.60 | | | Positive test for cirrhosis = C/RL ratio ≥ 0.65 | | |
|--|----------------|----------------|--|----------------|----------------|
| | Cirrhosis(+) | Cirrhosis(-) | | Cirrhosis(+) | Cirrhosis(-) |
| Test(+) | 41 | 10 | Test(+) | 28 | 4 |
| Test(-) | 59 | 90 | Test(-) | 72 | 96 |

| Nosologic Probabilities | | | Nosologic Probabilities | | |
|-----------------------------|--|--|-----------------------------|--|--|
| Sensitivity = 41% (41/100) | | | Sensitivity = 28% (28/100) | | |
| Specificity = 90% (90/100) | | | Specificity = 96% (96/100) | | |
| Accuracy = 66% (131/200) | | | Accuracy = 62% (124/200) | | |

C/RL ratio = Caudate-to-right-lobe ratio

Habin suggested, only 28 of 100 patients with liver cirrhosis had a C/RL ratio greater than or equal to 0.65. Giorgio et al. (19) reported that sensitivity of C/RL ratio on CT scan was very low for the cases of alcoholic cirrhosis, low for cryptogenic cirrhosis, but high for HBV-related cirrhosis(66%). Although our study could not compare viral cirrhosis with nonviral cirrhosis, sensitivity of C/RL ratio for viral cirrhosis was low (29%), using the same criterion of their study. In our study, C/RL ratio for normal liver was 0.47 (S. D. : 0.10), which is consistent with the data of Kim (20) and Harbin (11).

Potential technical pitfalls should be considered when obtaining LPVA. There are difficulties in exact determination of the umbilical point of the left portal vein ; a) obtuse angulation of the left portal vein at the umbilical point, b) vertical orientation of the left portal vein.

In conclusion, LPVA is a new useful index in the diagnosis of liver cirrhosis with a same level of diagnostic accuracy of C/RL ratio and can be used easily in practice because it is more convenient to measure than C/RL ratio.

REFERENCES

1. Sherlock S, Dooley J. *Diseases of the liver and biliary system*. 9th ed. Oxford : Blackwell scientific publications, **1993**; 17-32
2. Dewbury KC, Clark B. The accuracy of ultrasound in the detection of cirrhosis of the liver. *Br J Radiol* **1979**; 32 : 945-948
3. Sanford NL, Walsh P, Matis C, Baddeley H, Powell LW. Is ultrasonography useful in the assessment of diffuse parenchymal liver disease? *Gastroenterology* **1985**; 89 : 186-191
4. Needeelman L, Kurtz AB, Rifkin MD, Cooper HS, Pasto ME, Goldberg BB. Sonography of diffuse benign liver disease : accuracy of pattern recognition and grading. *AJR* **1987**; 146 : 1011-1014
5. Ralls PW, Johnson MB, Kanel G, et al. FM sonography in diffuse liver disease : prospective assessment and blinded analysis. *Radiology* **1986**; 161 : 451-454
6. Ferral H, Male R, Cardiel M, Munoz L. Cirrhosis : diagnosis by liver surface analysis with high frequency ultrasound. *Gastrointest Radiol* **1992**; 17 : 74-78.
7. Laing FC, Jeffrey RB, Federle MP, et al. Non-invasive imaging of unusual regenerating nodules in the cirrhotic liver. *Gastrointest Radiol* **1982**; 7 : 245-249
8. Waller RM, Oliver TW Jr, McCain AH, Sones PJ Jr, Bernardino ME. Computed tomography and sonography in hepatic cirrhosis and portal hypertension. *RadioGraphics* **1984**; 4 : 677-715
9. Fisher MR, Gore RM. Computed tomography in the evaluation of cirrhosis and portal hypertension. *J Clin Gastroenterol* **1985**; 7 : 173-181
10. Torres WE, Whitmire LF, Gedgaudas-McClees K, Bernardino ME. Computed tomography of hepatic morphologic changes in cirrhosis of the liver. *J Comput Assist Tomogr* **1986**; 10 : 47-50
11. Harbin WP, Robert NJ, Ferrucci JT. Diagnosis of cirrhosis based on regional changes in hepatic morphology. *Radiology* **1980**; 135 : 273-283
12. McNeil BJ, Adelstein SJ. Determining the value of diagnostic and screening tests. *J Nucl Med* **1976**; 17 : 439-448
13. Metz CE. ROC methodology in radiologic imaging. *Invest Radiol* **1986**; 21 : 720-733
14. Popper H, Elias H, Petty DE. Vascular pattern of cirrhotic liver. *Am J Clin Pathol* **1952**; 22 : 717-729
15. Popper H. Pathologic aspects of cirrhosis. A review. *Am J Pathol* **1977**; 87 : 228-264
16. Huet PM, DuReau A, Marleau D. Arterial and portal blood supply in cirrhosis : a functional evaluation. *Gut* **1979**; 20 : 792-796
17. Starzl TE, Porter KA, Kashiwagi N. Portal hepatotrophic factors, diabetes mellitus and acute liver atrophy, hypertrophy and regeneration. *Surg. Gynecol Obstet* **1975**; 141 : 843-858
18. Huet PM, Marleau D, Lavoie P, Viallet A. Extration of I125-albumin microaggregates from portal blood. An index of fuctional portal blood supply in cirrhotics. *Gastroenterology* **1976**; 70 : 74-81
19. Giorgio A, Amoroso P, Lettieri G, et al. Cirrhosis : value caudate to right lobe ratio in diagnosis with US. *Radiology* **1986**; 161 : 443-445
20. Kim YS, Jeong BR, Kim KS. Caudate to right lobe ratio of normal liver by computed tomography. *J Korean Radiol Soc* **1987**; 23(4) : 604-607

간경화증 진단에서 CT상의 좌간문맥각의 가치: 미상엽대 우엽비와의 비교¹

¹서울대학교 의과대학 진단방사선과학교실

정용기 · 최병인 · 한준구 · 김홍대 · 연경모

목 적: 간경화증 진단에 있어서 CT 상의 좌간문맥각의 유용성을 알아보고 미상엽대 우엽비와 진단적 가치를 비교하고자 하였다.

대상 및 방법: 100개의 간경화증간과 100개의 정상간의 CT영상에서 좌간문맥각, 수직선과 척추체부의 중심과 좌간문맥이 회전하는 점을 연결하는 선이 이루는 각과 미상엽대 우엽비를 측정하였다. 좌간문맥각과 미상엽대 우엽비의 진단적 가치를 통계적으로 비교하였다.

결 과: 좌간문맥각은 정상간에서 평균 18.9° (표준편차 : 7.6°) 이고 간경화증간에서 평균 25.6° (표준편차 : 8.4°) 로 유의한 차이가 있었다 ($P < 0.001$). C/RL 비는 정상간에서 평균 0.47 (표준편차 : 0.10) 이고 간경화증간에서 평균 0.58 (표준편차 : 0.14) 로 유의한 차이가 있었다 ($P < 0.001$). 좌간문맥각을 30° 이상으로 하였을 때는 예민도 36%, 특이도 92%로, C/RL 비를 0.60 이상으로 하였을 때는 예민도 41%, 특이도 90%로 간경화증을 진단할 수 있었다. 통계적으로 두 지표간의 진단적 정확도는 차이가 없었다.

결 론: 좌간문맥각과 C/RL 비는 CT에서 간경화증을 진단할 수 있는 유용한 지표이며, 좌간문맥각은 C/RL 비와 비교하여 보다 간편하게 측정할 수 있는 지표로 사료된다.