

# Primary Pulmonary Lymphoma : A Report of 2 Cases<sup>1</sup>

Yong Hoon Kim, M.D., Jeong Sook Kim, M.D., Seung Eun Chung, M.D.,  
Gham Hur, M.D., Il Hyang Ko, M.D.<sup>2</sup>, Young Tae Kwak, M.D.<sup>3</sup>,  
Soo Jeon Choi, M.D.<sup>4</sup>.

**Purpose :** Primary pulmonary lymphoma(PPL) arising in the lung as the initial site is very rare. Authors experienced two cases of PPL and report the radiologic findings and clinical characteristics with a brief review of the literature.

**Methods and Materials :** Plain chest radiograph and enhanced axial CT scan of the chest were taken. We analyzed radiologic findings of the two cases and correlated with bronoscopic and pathologic findings.

**Results :** Plain chest radiograph showed a mass like consolidative lesion on RML without peripheral atelectasis. Chest CT scan revealed a mass like consolidation with airbronchogram and the absence of a hilar mass or thoracic adenopathy. Percutaneous needle aspiration and biopsy(PCNA and PCNB) of the RML mass confirmed B-cell lymphoma, in both cases.

**Conclusion :** PPL must be included in the differential diagnosis of chronic alveolar consolidation such as bronchioloalveolar cell carcinoma.

**Index Words :** Lymphoma  
Lung neoplasms, CT

Lymphomas of the lung may be "primary" without identifiable extrapulmonary disease; alternatively, lymphoma in the lung may be a manifestation of widely disseminated disease or a direct extension from an adjacent site such as mediastinum(1-4).

Primary pulmonary lymphoma(PPL) arising in the lung as the initial site is very rare. The radiologic findings of the PPL were reported lobar consolidation in CT and plain chest radiograph(5). When lobar consolidation is chronic, two unusual neoplastic conditions-PPL and bronchioloalveolar cell cancer(BACC)-must be included in the differential diagnosis.

We report two cases of PPL and illustrate its radiologic findings and clinical characteristics.

## CASE REPORT

### Case 1.

A 76-year-old man was admitted because of a hemoptysis. He did not have any significant contri-

buted factors in his medical history except for hypertension during past 20 years without medication. Physical examinations and laboratory data were nonspecific.

A plain chest radiograph showed a consolidative lesion in RML, but no evidence of peripheral atelectasis(Fig. 1a). Chest CT scan revealed a mass like consolidation in RML with patent and stretched bronchi and the absence of a hilar mass or thoracic adenopathy. Opened bronchi showed proximal narrowing and somewhat peripheral dilatation within the lesion (Fig. 1b).

B-cell lymphoma was confirmed by PCNA and PCNB of the RML consolidative mass. Microscopically, the tumor mass was composed of small neoplastic lymphoid cells with monotonous features in general. Immunohistochemically, the tumor cells showed a monoclonality: weak positivity for B cell marker(L26) and negative reaction for T cell marker(UCHL1). This monoclonality strongly suggested the malignant lymphoma (Fig. 3a).

### Case2.

A 35 year-old man underwent annual physical examinations and took chest radiograph in September, 1992. The patient had been asymptomatic without any episode of coughing, hemoptysis or weight loss. However, the chest radiograph showed an ill-de-

<sup>1</sup>Department of Radiology, Sanggye Paik Hospital Inje University

<sup>2</sup>Department of Pathology, Sanggye Paik Hospital Inje University

<sup>3</sup>Department of Thoracic Surgery, Sanggye Paik Hospital Inje University

<sup>4</sup>Department of Internal Medicine, Sanggye Paik Hospital Inje University

Received April 26, 1994; Accepted May 20, 1995

Address reprint requests to: Yong Hoon Kim, M.D., Department of Radiology, Sanggye Paik Host. Sanggye-7dong, Nowon-gu, Seoul, 139-207 Korea. Tel. 82-2-950-1182

defined mass with peripheral infiltration in RML. In October, 1992, a chest radiograph and a chest CT scan were taken.

The chest radiograph showed a  $3 \times 2.8$  cm round ill-defined mass in RML(Fig. 2a). The chest CT scan revealed slightly enhanced round mass with spiculated border on parenchymal window, but mediastinal lymph node were not enlarged(Fig. 2c). The PCNA and PCNB were performed and the specimens were compatible with chronic inflammation.

Follow-up chest radiograph obtained 11 months later showed that the mass was slightly increased in size, compared with previous film(Fig. 2b). Biopsy was repeated to ruled out possible malignancy. The histopathology was consistent with low grade B-cell lymphoma(Fig. 3b).

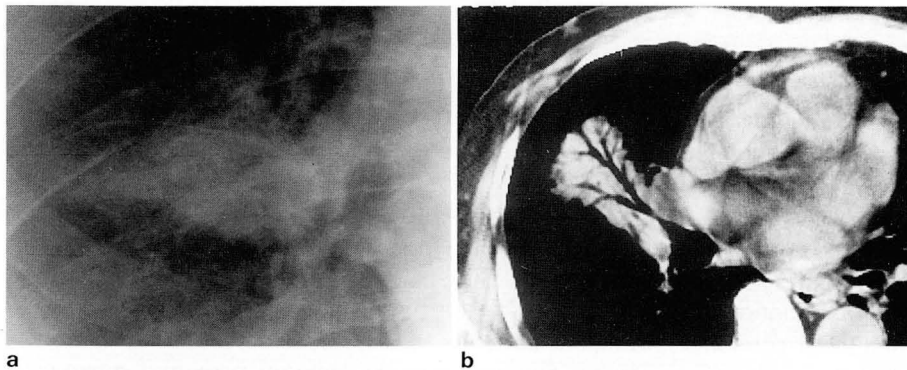
## DISCUSSION

PPL is one of the least common forms of extra-nodal lymphoma. It has remained poorly understood in terms of its histogenesis and natural history. Its good prognosis, compared with other pulmonary tumors and malignant lymphomas at other site, was appreciated by Saltzstein(1963), but he interpreted the very low incidence of dissemination as evidence that many such

lesions were not true lymphomas but some form of reactive hyperplasia, which he termed "pseudolymphoma".

PPL was manifested occasionally as chronic consolidation such as our cases(5), and some cases were reported as an interstitial pattern on the chest films(6). Chronic air-space consolidation can be caused by a wide variety of disorders. Benign entities include untreated, incompletely treated pneumonia, tuberculosis, or fungus infection. Noninfectious causes include lipoid pneumonia and alveolar sarcoid. In addition to obstructive pneumonia secondary to an obstructing hilar mass, two unusual neoplasms must always be excluded-PPL and bronchioloalveolar cell carcinoma.

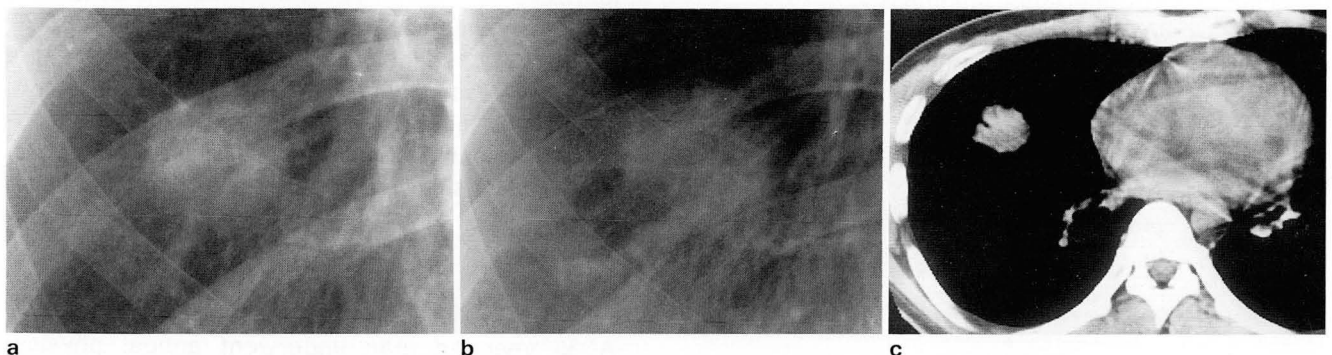
In disseminated malignant lymphoma, either a prior history of lymphoma or extensive nodal involvement is usually present. Chest radiographic changes of disseminated lymphoma include mediastinal or hilar lymphadenopathy, multiple parenchymal nodular densities, or pleural effusions. In contrast, PPL arises in the lung as the initial site, and extrapulmonary spread is usually not a feature, but it typically manifest as one or more well-circumscribed nodular mass ranging in size from 2 to 10 cm in diameter on chest radiograph(2-5). Air bronchograms are often identified within the pulmonary lesion. Most patients with PPL are asymptomatic.



**Fig. 1.** Case 1 : 76-year-old man with hemoptysis.

a. Plain chest radiograph shows a consolidative lesion in RML without peripheral atelectasis.

b. CT scan reveals a mass-like consolidation with air bronchogram in RML.

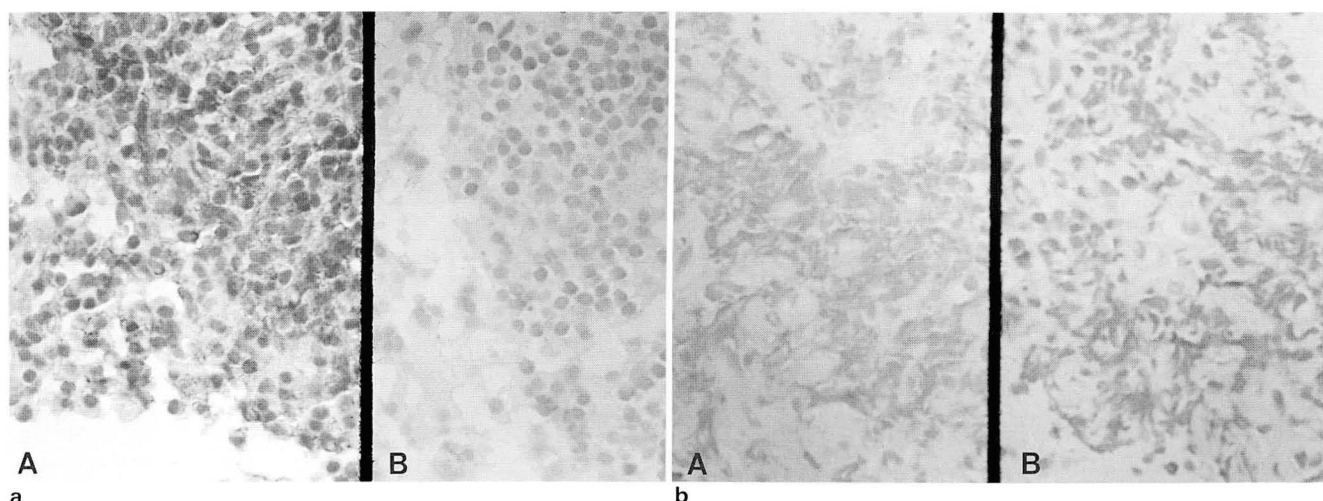


**Fig. 2.** Case 2 : 35-years-old man without subjective symptom.

a. Initial chest radiograph shows a  $3 \times 2.8$  cm sized ill-defined round mass in RML.

b. 11 months later, follow-up chest radiograph shows slightly increase of mass in size( $3.5 \times 3$  cm).

c. Initial CT scan shows a round consolidation with spiculated border in RML.



**Fig. 3.** Pathologic findings of both cases.

a. Case 1 : Immunohistochemical staining for B cell marker(L26) shows diffuse strong positivity in the neoplastic lymphoid cells(A) and negative reaction for T cell marker(UCHL1)(B)( $\times 1000$ ).

b. Case 2 : Immunohistochemical staining for B cell marker(L26) shows diffuse weak positivity in the neoplastic lymphoid cells(A) and negative reaction for T cell marker(UCHL1)(B)( $\times 1000$ ).

matic, and the lesion is discovered on incidental chest radiograph.

PPL may be associated with immunocompromised patients such as AIDS or organ transplantation, and it presents as a nodular lesion on the chest radiograph (7). Case 1 in this study was associated with amyloidosis which, to our knowledge, has not been previously reported. But the relationship between both entities is not certain.

The choice of treatment for PPL is surgical resection rather than systemic chemotherapy. Cure rates of 80–90% have been reported when complete resection has been achieved(1–3). But when complete surgical resection cannot be achieved, adjuvant chemotherapy or radiation may be warranted.

Bronchioloalveolar cell carcinoma must be included in the differential diagnosis of lobar consolidation. Many of the lesions grow slowly, showing little change for months or even years. Characteristics of both entities are the tendency to maintain bronchial integrity, that visualization of an airbronchogram is common(8). CT findings in bronchioloalveolar cell carcinoma include stretching, spreading, and uniform narrowing of the involved but unobstructed bronchi(9). Similar but less pronounced changes were present in our cases. But in contrast to PPL, bronchioloalveolar cell carcinoma may have symptoms including production of copious mucous sputum. When alveolar consolidation is chronic, PPL and bronchioloalveolar cell carcinoma must be included in the differential diagnosis.

## REFERENCES

1. L'Hoste RJ, Jr., Filippa DA, Lieberman PH, Bretsky S. Primary pulmonary lymphomas. A clinicopathologic analysis of 36 cases. *Cancer* **1984**; 54:1387-1406
2. Koss M, Hochholzer L, Nichols PW, Wehunt W, Lazarus A. A primary non-Hodgkin's lymphoma and pseudolymphoma of the lung. A study of 161 patients. *Hum Pathol* **1983**; 14:1024-1038
3. Turner RR, Colby TV, Doggett RS. Well-differentiated lymphocytic lymphoma: a study of 47 patients with primary manifestation in the lung. *Cancer* **1984**; 54:2088-2096
4. Kennedy JL, Nathwani BN, Burke JS, Hill LR, Rappaport H. Pulmonary lymphomas and other pulmonary lymphoid lesions. A clinicopathologic and immunologic study of 64 patients. *Cancer* **1985**; 56:539-552
5. Bosanko CM, Korobkin M, Fantone JC, Rubin SB, Lynch JP. Lobar primary pulmonary lymphoma: CT findings. *J Comput Assist Tomogr* **1991**; 15:679-682
6. Aliaga L, Garcia F, Lecumberri F. Primary pulmonary lymphoma. Radiologic manifestations of well-differentiated lymphocytic lymphoma. *Rev Med Univ Navarra* **1987**; 31:93-96
7. Pielzleitner D, Huebsch P, Mayerhofer S, Chott A, Zielinski C. Primary pulmonary lymphoma in a patient with the acquired immune deficiency syndrome. *Thorax* **1989**; 44:438-439
8. Hill CA. Bronchioloalveolar carcinoma: a review. *Radiology* **1984**; 150:15-20
9. Im JG, Choi BI, Park JH, et al. CT findings of lobar bronchioloalveolar carcinoma. *J Comput Assist Tomogr* **1986**; 10:320-322

## 폐의 원발성 림프종:2예 보고<sup>1</sup>

<sup>1</sup>인제대학교 의과대학 부속 상계백병원 진단 방사선과학교실

<sup>2</sup>병리학교실, <sup>3</sup>흉부외과학교실, <sup>4</sup>내과학교실

김용훈 · 김정숙 · 정승은 · 허 감 · 고일향<sup>2</sup> · 곽영태<sup>3</sup> · 최수전<sup>4</sup>

**목 적:** 폐의 원발성 림프종은 드문 질환으로 저자들은 폐포 세기관지 세포암(Bronchioloalveolar cell carcinoma)과 감별을 요하는 폐의 원발성 림프종 2예를 경험하였기에 문헌고찰과 함께 보고하는 바이다.

**대상 및 방법:** 2예 모두 단순 흉부사진, CT를 시행하였으며 경피적 조직생검을 통하여 확진 하였다.

**결 과:** 단순 흉부사진상 두예 모두 종괴양 경화로 나타났으며 변연부 폐허탈은 보이지 않았다. CT 스캔상 기관지내 공기 음영을 동반한 우중엽의 경화가 있었고 기관지가 좁아지는 소견은 없었으며 다른 부위에 림프선 비대도 없었다. 경피적 조직생검상 B 세포 형태의 림프종으로 확진되었다.

**결 론:** 폐의 원발성 림프종은 만성 폐포성 경화로 나타날 수 있으며 이 경우 폐포 세기관지 세포암과의 감별이 필요할 것으로 생각된다.