

## The Major Aortopulmonary Collateral Arteries in Pulmonary Atresia with Ventricular Septal Defect: Chest Radiologic Findings

Sung-jin Kim, M.D., Yeon Hyeon Choe, M.D.\*, Ji Eun Kim, M.D.,  
Kil Sun Park, M.D., Dae Yeong Kim M.D.

*Department of Radiology, Chungbuk National University College of Medicine*

### — Abstract —

The chest radiographs and angiograms were retrospectively evaluated in 47 patients with pulmonary atresia (PA) and ventricular septal defect (VSD) to determine the characteristic findings of major aortopulmonary collateral arteries (MAPCAs) on the chest radiographs. Of 47 patients, 23 had MAPCAs and 24 had only PDA for blood supply of whole right and left lung. Chest radiographs enabled identification of 16 of 23 patients with MAPCAs. The most common finding of MAPCAs was inappropriately large peripheral pulmonary vasculature ( $n = 16$ , 69.6%). The other findings were tortuosity of pulmonary vasculature ( $n = 12$ , 52.2%), focal uneven distribution of pulmonary vasculature ( $n = 12$ , 52.2%), and two descending pulmonary arteries ( $n = 4$ , 17.4%). When chest radiographs showed two or more findings of MAPCAs, MAPCAs could be differentiated from PDA with statistical significance ( $p < 0.005$ ). It is concluded that chest radiographs may help to identify MAPCAs before angiography if two-dimensional echocardiography suggests PA with VSD.

**Index Words:** Pulmonary atresia, 564.1555

Pulmonary artery, collaterals, 564.91

Aorta, angiography, 563.124

Lung, radiography, 60.11

In the cases of pulmonary atresia (PA) with ventricular septal defect (VSD), the lungs are usually supplied by patent ductus arteriosus (PDA), major aortopulmonary collateral arteries (MAPCAs), and acquired collateral arteries. The angiograms should provide information about the sources of the pulmonary blood supply and the detailed anatomy of the central pulmonary artery and of the intrapulmonary pulmonary artery. When the MAPCAs are the sources of the pulmonary blood supply, selective angiography should be performed, because this

is essential for diagnosis and for determining operability and surgical approach. The angiography usually requires large quantity of contrast materials and is a time-consuming procedure. If the angiographers know the sources of the pulmonary blood supply before cardioangiography, they may take appropriate angiographic approach to save time. Although two-dimensional echocardiography is a good noninvasive mean of evaluating PA with VSD, it is limited in the evaluation of collateral blood supply. To authors' knowledge, although the

\*세종병원 방사선과

\*Department of Radiology, Sejong General Hospital

이 논문은 1992년 4월 28일 접수하여 1992년 8월 21일에 채택되었음

Received April 28, Accepted August 21, 1992

angiographic, pathologic findings, and hemodynamic changes of MAPCAs have well been documented (1-6), diagnostic evaluation of these patients with chest radiographs have not been reported previously. The purpose of our work was to recognize the characteristic findings of MAPCAs on the chest radiographs of the patients with PA and VSD that was previously diagnosed by angiography.

## MATERIALS AND METHODS

Fifty patients had PA with VSD and one patient had tetralogy of Fallot with severe pulmonary stenosis. Of these 51 patients, 23 patients had MAPCAs, 24 patients had PDA, two patients had only acquired collateral arteries and two patients had systemic-pulmonary shunt. The last four patients were excluded in this review, because the chest radiographs of these patients would not exactly be representative of the findings of MAPCAs. The patients consisted of 26 males and 21 females, and the age ranged from one month to 32 years old (mean:3.36 years).

In the cases with MAPCAs, all patients (n = 23) had aortograms and selective angiograms of at least one MAPCA. The aortograms were obtained in anteroposterior (AP; N = 16) or elongated right anterior oblique (RAO; n = 7) view and selective angiograms wholly in AP view. In the cases with PDA, all patients had aortograms with AP (n = 18) or RAO view (n = 6). The RAO view obtained in 30 to 45 degrees right anterior oblique view with 30 to 45 degrees caudocranial angulation. The chest radiographs were obtained in posteroanterior only. The interval between chest radiographic and angiographic examinations ranged one to three days (mean:1.2days). All chest radiographs were reviewed in random order, and separately from the corresponding angiograms by two observers, without the knowledge of the presence of MAPCAs or PDA. A conclusion was reached by consensus.

Emphasis was given to the following features: (1) inappropriately large peripheral pulmonary vasculature compared with the adjacent pulmonary vasculatures, (2) focal uneven-distribution of pulmonary vasculature, (3) two descending pulmonary arteries (the one lying inferomedial and the other lying superomedial to the bronchus intermedius), and (4) tortuosity of pulmonary vasculature. We used the term "focal uneven-distribution" when the pulmonary vascularity was increased or decreased in less than half lung field and asymmetrical to the opposite lung field. We compared these chest radiographic findings with the findings of aortograms and selective angiograms.

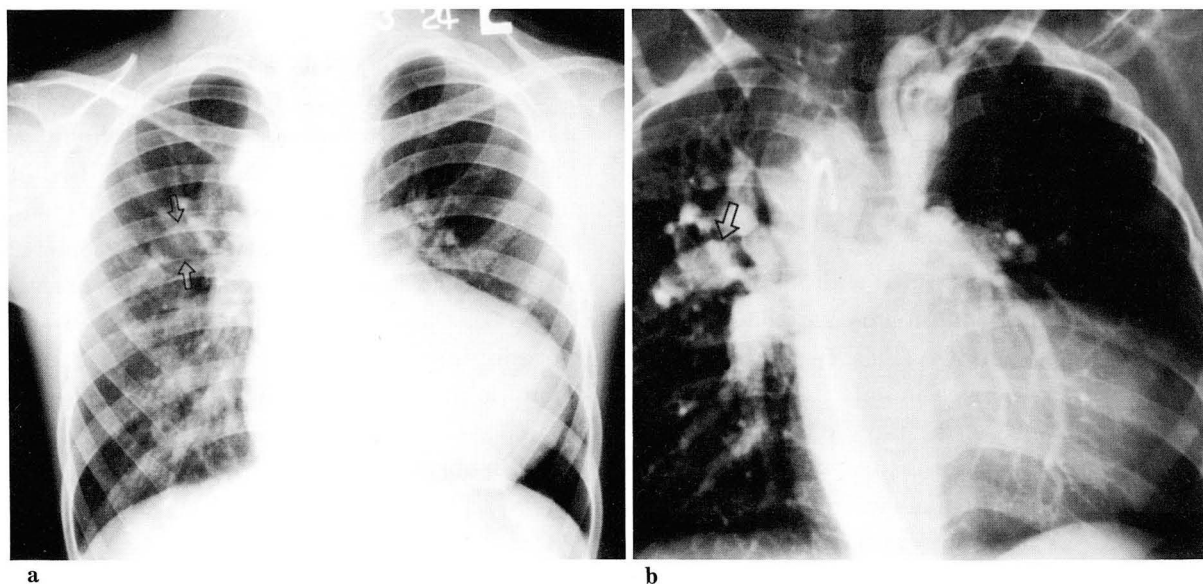
## RESULTS

On angiograms, confluent pulmonary artery was seen in 15 (65.2%) and nonconfluent pulmonary artery in eight (34.8%) of the 23 patients with MAPCAs. The numbers of MAPCAs ranged from one to four (mean:2.3), with two (n = 10) or three (n = 9) being the most common. All patients with PDA had confluent pulmonary artery and no demonstrable MAPCAs.

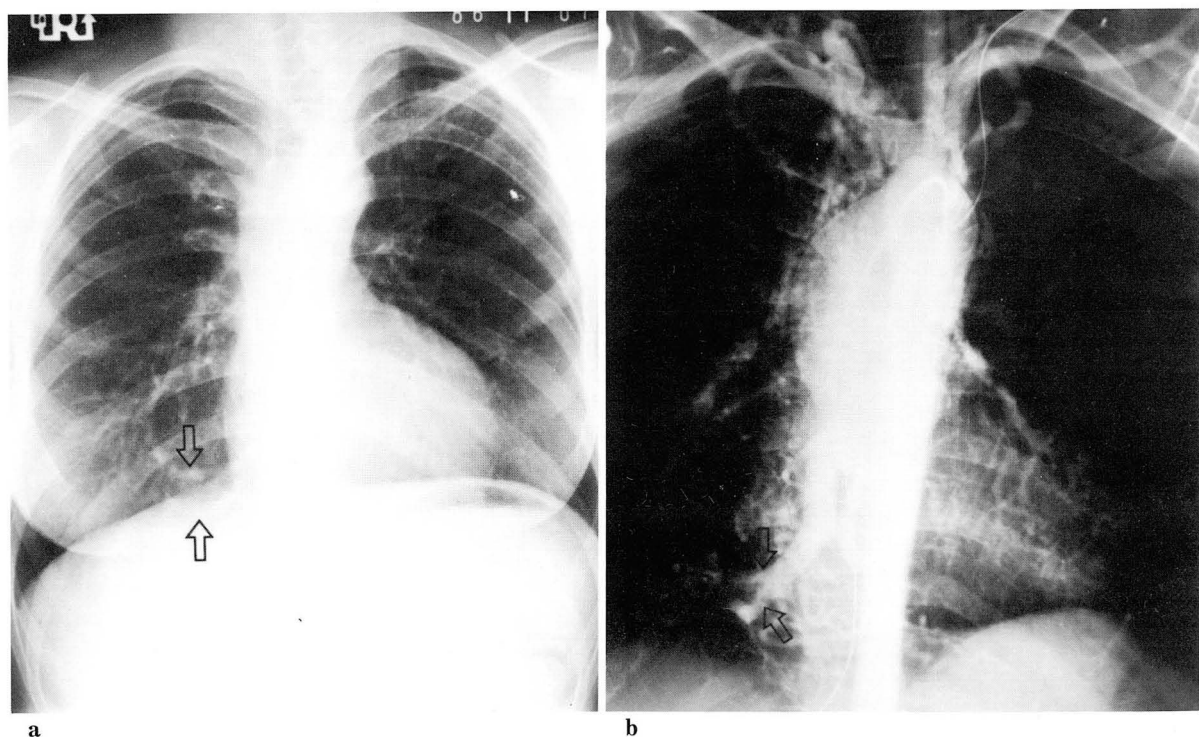
The most common chest radiographic abnormality of MAPCAs was an inappropriately large peripheral pulmonary vasculature (Fig. 1), seen

**Table 1.** Comparison of Results from MAPCAs with Results from PDA

	MAPCAs (n = 23)	PDA (n = 24)
Inappropriately large peripheral pulmonary vasculature	16(69.6%)	1(4.2%)
Focal uneven-distribution of pulmonary vasculature	12(53.2%)	3(12.5%)
Tortuosity of pulmonary vasculature	12(52.2%)	2(8.3%)
Two descending pulmonary artery	4(17.4%)	0(0.0%)



**Fig. 1.** Eight-year-old male patient with pulmonary atresia with ventricular septal defect. (a) The pulmonary vascularity is markedly increased on right side but decreased on left. Abnormally large vessel (arrow) is seen at the right upper lung field. (b) Aortogram shows confluent pulmonary artery and at least two MAPCAs. The poststenotic portion of pulmonary artery (arrow) supplied by MAPCA is markedly dilated and exactly correlated with the abnormally large vessel seen on chest radiograph.



**Fig. 2.** Eighteen-year-old female patient. (a) The chest radiograph shows decreased pulmonary vascularity on both lungs. Two tortuous vessels are seen at the right cardiophrenic angle area (arrow). (b) Aortogram shows many small acquired collateral arteries. A MAPCA supplies the tortuous vessels seen on the chest radiograph (arrow).

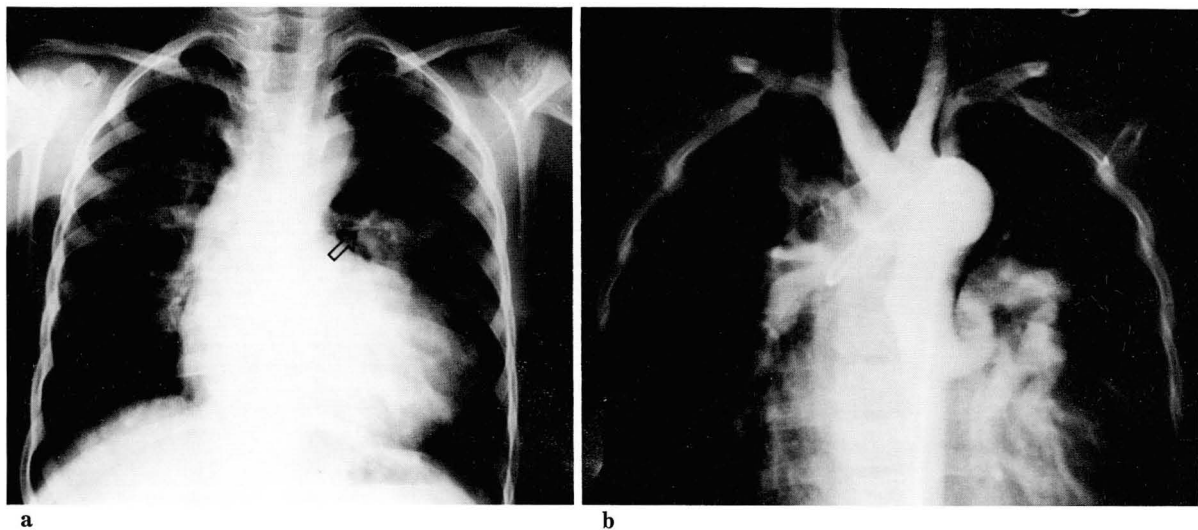
in 16 (69.6%) patients, but this finding was found in only one of 24 patients with PDA (Table 1). Interestingly, this vessel often was not converted to the hilum. A tortuosity of pulmonary vasculature ( $n = 12$ ) and focal uneven distribution of pulmonary vasculature ( $n = 12$ ) were also common findings of MAPCAs (Fig. 2,3). These two findings were accompanied with inappropriately large peripheral pulmonary vasculature, but, in the patients with PDA, these two findings were very uncommon, seen in only three and two of 24 patients. Two of the three patients showing tortuosity of the pulmonary vasculature had pulmonary hypertension. And one of the two patients with focal uneven distribution of pulmonary vasculature had extensive acquired collateral arteries. Although the finding of two descending pulmonary arteries was found in only four patients, this was the most specific finding of MAPCAs not demonstrated in the patients with PDA. This finding was well correlated angiographically with the course of the MAPCA and the pulmonary artery supplied. The one lying superolateral to the bronchus intermedius was true interlobar artery, but the other lying inferomedial to the bronchus intermedius arose

from the MAPCA (Fig. 4).

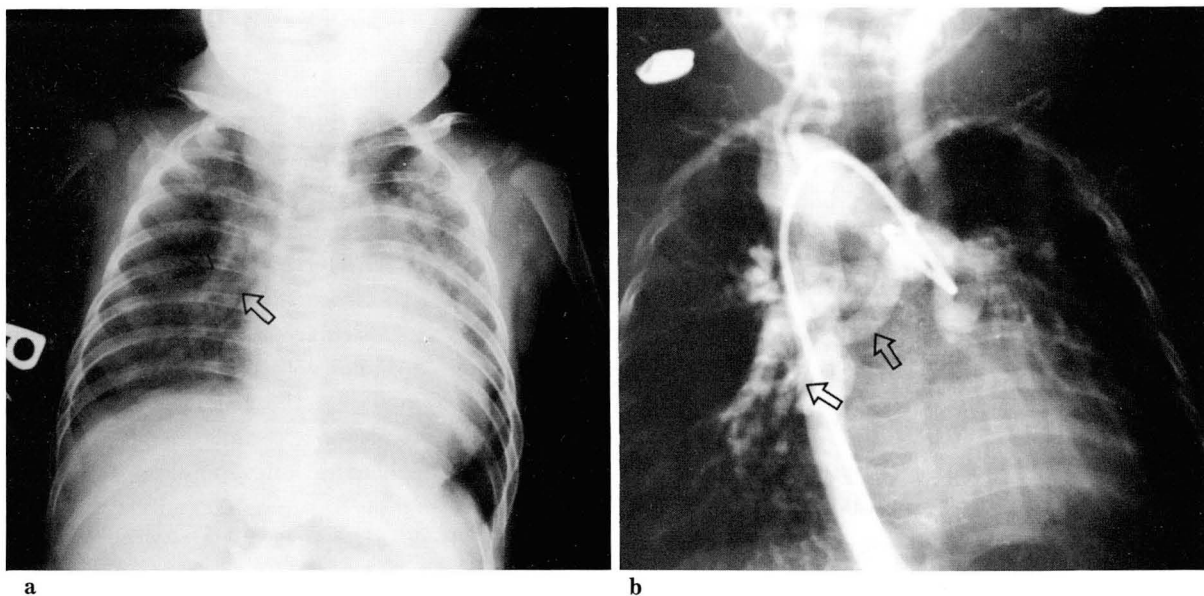
Sixteen (69.6%) of the 23 patients with MAPCAs and only one (4.2%) patient with PDA had abnormalities in two or more of the four findings. Thus, if the chest radiographs showed two or more findings of MAPCAs in the patients with PA and VSD, the possibility of the presence of MAPCAs had statistical significance ( $X^2 = 19.01$ , 1df,  $p < 0.005$ ). of the 16 patients with two or more findings of the MAPCAs, nine had confluent pulmonary artery (9/15, 60%) and seven had nonconfluent pulmonary artery (7/8, 87.5%), but difference between these two groups did not achieve statistical significance ( $X^2 = 0.79$ , 1df,  $p > 0.1$ ).

## DISCUSSION

In patients with PA and VSD but without PDA, survival depends on the collateral arteries. Usually, the MAPCA connects with a segmental pulmonary artery at the hilum, which is the only source of blood supply to the segment (1). The MAPCAs have the high incidence of stenosis in their course (1-6). The sites of stenosis are



**Fig. 3.** Seven-year-old male patient. (a) The chest radiograph shows focal decrease in pulmonary vascularity on left upper lung field and abnormally large vessel without demonstrable left main pulmonary artery (arrow) at the hilar area. (b) Aortogram shows markedly decreased vascularity on the left upper lung field. A large MAPCA supplying left lower lung field does not connect with the left main pulmonary artery.



**Fig. 4.** One-month-old female patient. (a) The chest radiograph shows two descending pulmonary arteries on the right (arrow). (b) The one supplied by a MAPCA lies beneath and medial to the bronchus intermedius (arrow). Whereas, the other lying above and lateral to the bronchus intermedius arises from the right pulmonary artery.

usually at the MAPCA-pulmonary artery connection and at the origin of MAPCA from the aorta (1-4). The stenosis prevents full transmission of flow and pressure from the systemic to the pulmonary side and protects the distal pulmonary vascular bed (3,5). When the MAPCAs are not stenotic, pulmonary hypertension is inevitable in the portion of the lung supplied (2,3). The poststenotic portion of pulmonary artery is dilated, and often showed sinusoidal dilatation (1,2,3). The larger the communication with systemic collateral artery is, the larger the pulmonary artery within the lung becomes (1,3).

In our cases, the usual findings of MAPCAs on chest radiographs were inappropriately large peripheral pulmonary vasculature, tortuosity of pulmonary vasculature, and focal uneven-distribution of pulmonary vasculature. These findings can be explained by local pulmonary hypertension due to MAPCAs and poststenotic dilatation of the pulmonary arteries. We could demonstrate that these three findings of the MAPCAs on chest radiographs were well cor-

related with the dilated tortuous pulmonary arteries connected with MAPCAs, and focal increase or decrease in pulmonary vascularity on aortograms. Occasionally, inappropriately large pulmonary vasculature was not conversion to the hilum or was seen without demonstrable proximal pulmonary artery (Fig. 3). These features strongly suggested that the inappropriately large pulmonary vasculature was supplied from MAPCAs. Two descending pulmonary arteries, which was the most specific finding, could be identified at the right side only. On aortograms, two parallel descending pulmonary arteries at the right side were demonstrated in 10 patients. We could not detect this finding on chest radiographs in six patients due to overlapped heart shadow. We think this finding may be more easily identified on the adequately exposed film or bucky film.

In our cases with PDA, the patients had only confluent pulmonary artery, and hardly showed any findings of the MAPCAs. The reason of these may be that if the PDA is the sole source of blood supply of the lungs, in contrast to the



MAPCAs, the patients have fully developed pulmonary arteries (4). Only one patient with PDA showed two findings of MAPCAs (inappropriately large peripheral pulmonary vasculature and tortuosity of pulmonary vasculature), but, even this patient had acquired collateral arteries.

Our series have two limitations. One is that although chest radiographs showed the findings of MAPCAs, it could not reveal the numbers or origins of MAPCAs. The other is that no patient with PDA had MAPCAs for the blood supply to the lungs. It cannot, therefore, be assumed from our study that the findings of MAPCAs on chest radiographs will exclude the patients with PDA and MAPCAs as they did in the patients with PDA. Fortunately, the patients with PDA and MAPCAs are not common. Also it has been mentioned infrequently (6,7).

In summary, in the patient with PA and VSD which can be easily diagnosed by two-dimensional echocardiography, the various findings of MAPCAs, particularly those seen in combination, may help to detect the presence or absence of MAPCAs before angiocardiograms.

## REFERENCES

1. Haworth SJ. Collateral arteries in pulmonary atresia with ventricular septal defect A precarious blood supply. *Br Heart J* 1980;44:5-13
2. Mcgoon MD, Fulton RE, Davis GD, Ritter DG, Neill CA, White RI. Systemic collateral and pulmonary artery stenosis in patients with congenital pulmonary atresia and ventricular septal defect. *Circulation* 1977;56:473-479
3. Rabinovitch M, Herrera-deLeon V, Castaneda AR, Reid L. Growth and development of the pulmonary vascular bed in patients with tetralogy of Fallot with or without pulmonary atresia. *Circulation* 1981;64:1234-1249
4. Jefferson K, Rees S, Somerville J. Systemic arterial supply to the lungs in pulmonary atresia and its relation to pulmonary artery development. *Br Heart J* 1972;34:418-427
5. Macartney F, Deverall P, Scott O. Hemodynamic characteristics of systemic arterial blood supply to the lungs. *Br Heart J* 1973; 35:28-37
6. Thiene G, Frescura C, Bortolotti U, Maschio AD, Valente M. The systemic pulmonary circulation in pulmonary atresia with ventricular septal defect: Concept of reciprocal development of the fourth and sixth aortic arches. *Am Heart J* 1981;101:339-344
7. Frescura C, Talenti E, Pellegrino PA, Mazzucco A, Faggian G, Theine G. Coexistence of ductal and systemic pulmonary arterial supply in pulmonary atresia with ventricular septal defect. *Am J Cardiol* 1984;53:348-349

1. Haworth SJ. Collateral arteries in pulmonary

### <국문 요약>

#### 심실중격결손을 동반한 폐동맥 폐색 환자에서의 주 대-폐동맥 측부동맥 : 단순흉부사진 소견

충북대학교 의과대학 방사선과학교실, 세종병원방사선과\*

김성진 · 최연현\* · 김지은\* · 박길선 · 김대영

단순흉부사진에서 주 대-폐동맥 측부동맥(major aortopulmonary collateral artery : MAPCA)의 특징적인 소견을 알아내기 위하여 폐동맥폐색과 심실중격결손이 있는 환자 47명의 혈관조영상과 단순흉부사진을 후향적으로 분석하였다. 총 47명의 환자중, 23명에서는 MAPCA가, 나머지 24명에서는 개방동맥관(patent ductus arteriosus : PDA)이 양측 폐의 주된 혈액공급원이었다. 단순흉부사진상 23명의 환자 중 16명에서 MAPCA의 존재를 알아낼 수 있었다. MAPCA에서 가장 흔히 보이는 소견은 비정상적으로 큰 변연부 폐혈관이었다(N=16, 69.6%). 그 외, 사행성의 폐혈관(N=12, 52.2%), 부분적으로 비균질 분포를 보이는 폐혈관(N=12, 52.2%), 및 두 개의 하행폐동맥(N=4, 17.4%)이 MAPCA를 시사하는 소견이었다. 단순흉부사진에서 이러한 소견 중 둘 이상이 관찰되었을 경우, 폐의 혈액공급원은 MAPCA였으며, 이와같은 결과는 통계적인 유의성을 보였다( $p<0.005$ ).

결론적으로, 심초음파검사상 심실중격결손과 폐동맥폐색이 의심되는 환자의 경우, 단순흉부사진에서 이와같은 소견을 확인함으로써 MAPCA의 존재유무를 혈관조영술 시행전에 알아낼 수 있을 것으로 생각된다.