

A Case of Infliximab-induced Multifocal Motor Neuropathy in a Patient with Rheumatoid Arthritis and Literature Review

Bomi Seo¹, Yeong Jin Jeong¹, Seokchan Hong², Yong-Gil Kim², Chang-Keun Lee², Bin Yoo²

¹Department of Internal Medicine, ²Division of Rheumatology, Department of Internal Medicine, Asan Medical Center, University of Ulsan College of Medicine, Seoul, Korea

Tumor necrosis factor (TNF) inhibitors are increasingly used in treatment of rheumatoid arthritis (RA), ankylosing spondylitis, psoriatic arthritis, and inflammatory bowel diseases including Crohn's disease and ulcerative colitis. Rarely, anti-TNF therapy is associated with neurological complications, including both central and peripheral nervous system disorders. To the best of our knowledge, only one case of infliximab-associated multifocal motor neuropathy with conduction block in a patient with spondyloarthritis has been reported to date in Korea. Here, we report on the case of a 58-year-old Korean woman affected by RA who developed multifocal motor neuropathy after infliximab treatment. (*J Rheum Dis* 2016;23:250-255)

Key Words. Infliximab, Motor neuropathy, Rheumatoid arthritis

INTRODUCTION

Tumor necrosis factor (TNF), an inflammatory cytokine originating from T lymphocytes and macrophages, plays an important role in the development and maintenance of rheumatoid arthritis (RA) [1]. TNF antagonists effectively treat several immune-mediated inflammatory diseases, such as RA, spondyloarthropathies, and inflammatory bowel disease. There are two classes of TNF antagonist: anti-TNF monoclonal antibodies (infliximab, adalimumab, and golimumab) and soluble TNF receptor-Fc fusion proteins (etanercept) [2]. The adverse effects of anti-TNF therapy are well known and include injection/infusion reactions, infection (e.g., tuberculosis), vasculitis, congestive heart failure, malignancy, and pancytopenia [3]. Additionally, neurological adverse events after anti-TNF therapies can develop in both the central nervous system (e.g., multiple sclerosis, optic neuritis, and acute transverse myelitis) and peripheral nervous system (e.g., Guillain-Barré syndrome, Miller Fisher syndrome, chronic inflammatory demyelinating polyneuropathy, mono-

neuritis multiplex, axonal sensorimotor polyneuropathy, and multifocal motor neuropathy with conduction block [MMNCB]) [4].

Multifocal motor neuropathy (MMN) is a rare, slowly progressive, inflammatory neuropathy that involves asymmetric weakness of a distal limb without sensory involvement [5]. Several cases of MMNCB associated with TNF antagonists have been reported worldwide, but only one case of MMNCB has been reported in Korea, which developed during infliximab treatment of ankylosing spondylitis [6]. We here describe a 58-year-old Korean woman with RA who developed MMNCB after treatment with infliximab.

CASE REPORT

A 58-year-old woman presented with progressive weakness and a tingling sensation in both hands and legs for 5 months. She complained that it was difficult to climb stairs and elevate her legs as well as handle chopsticks and fasten the buttons. Before coming to our medical cen-

Received : August 26, 2015, **Revised :** August 31, 2015, **Accepted :** September 1, 2015

Corresponding to : Bin Yoo, Division of Rheumatology, Department of Internal Medicine, Asan Medical Center, University of Ulsan College of Medicine, 88 Olympic-ro 43-gil, Songpa-gu, Seoul 05505, Korea. E-mail : byoo@amc.seoul.kr

pISSN: 2093-940X, eISSN: 2233-4718

Copyright © 2016 by The Korean College of Rheumatology. All rights reserved.

This is a Free Access article, which permits unrestricted non-commercial use, distribution, and reproduction in any medium, provided the original work is properly cited.

ter, she had been diagnosed with seropositive RA 10 years previously and commenced treatment with methotrexate and low-dose steroids 5 years prior. Four years previously, she underwent surgery due to spondylolisthesis. After this operation, she denied all of neurologic symptoms

such as weakness, sensory change, or radiating pain. For the past year, she had received infliximab infusion combined with methotrexate every 2 months to control RA activity. After six of these infusions, she developed progressive bilateral weakness of the legs and hands.

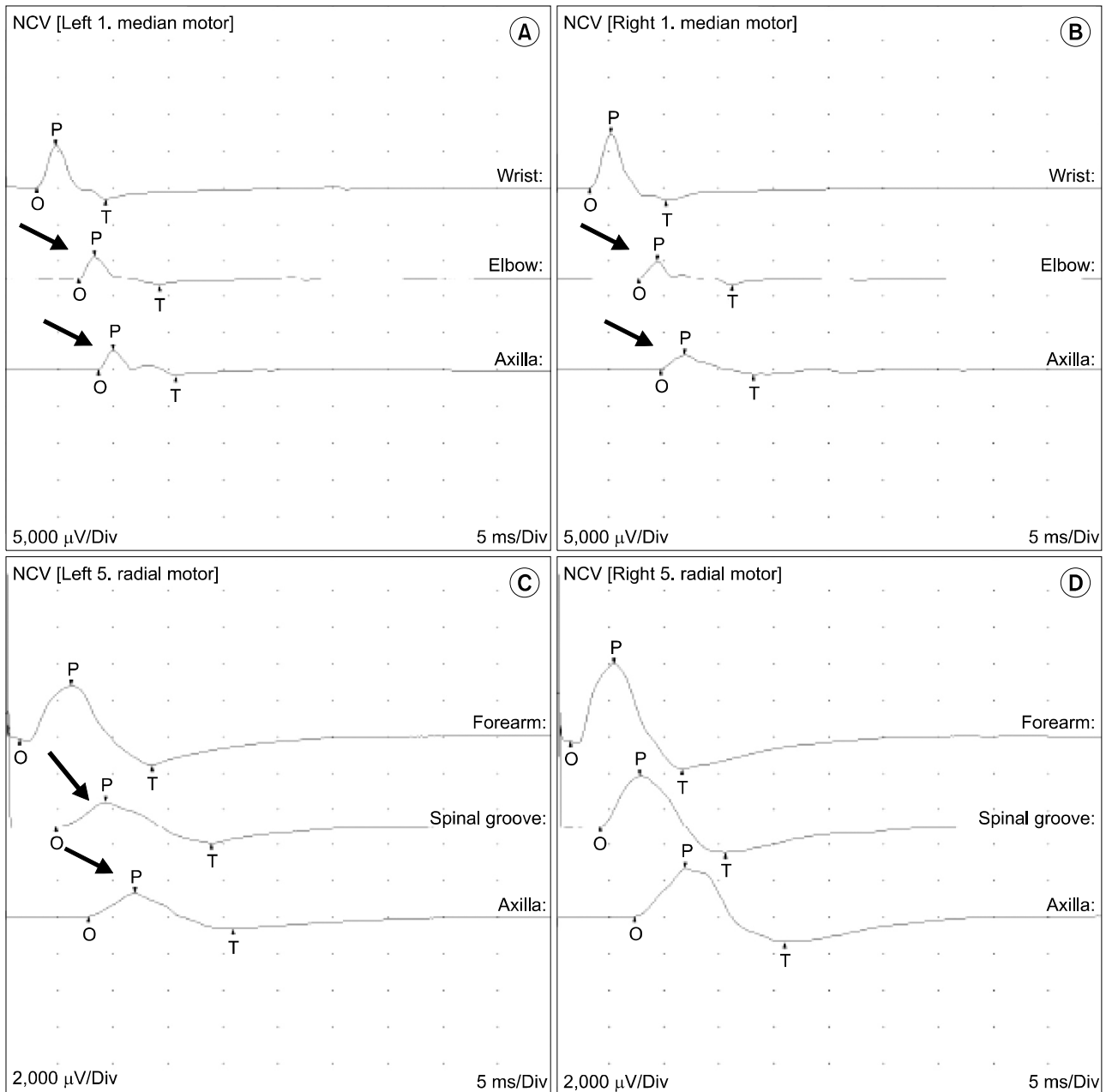


Figure 1. Motor nerve conduction studies of bilateral median (A, B) and radial (C, D) nerves during the first examination of the study patient, performed several months after symptom onset. It is notable that in panels A and B, the muscle responses after stimulation at the axilla and elbow (arrows) were reduced in amplitude and area by 50% compared with those after a more distal stimulation at the wrist. In panel C, muscle responses after stimulation at the spinal groove and axilla (arrows) showed a 50% reduction in amplitude and area as compared with those after more distal stimulation at the forearm. These findings are in accordance with the definition of a focal motor conduction block across that nerve segment. On the other hand, in panel D, it was evident that the muscle responses after stimulation at the spinal groove and axilla were less than 50% reduced in amplitude and area as compared with those after more distal stimulation at the forearm. NCV: nerve conduction velocity, O: onset, P: peak, T: threshold.

On examination, her body temperature was 37.0°C and her blood pressure and pulse rate were 121/81 mmHg and 77 beats per minutes. Her respiration appeared normal with a respiratory rate of 18 breaths per minute. On neurological examination, first dorsal interosseus, thenar, and hypothenar muscle atrophies were present in both hands without fasciculation. She had bilateral arm weakness that was slightly worse in the right arm. The proximal and distal muscle powers of her arms were Medical Research Council (MRC) grade 4+ and 3, respectively. Finger flexion was MRC grade 4 on the left and the right, and finger spread and thumb abduction were MRC grade 3+ on the right and MRC grade 4 on the left. Additionally, she had bilateral leg weakness with proximal and distal muscle powers of MRC grade 4+ and 4. The sensation in both arms was normal. The vibration and position sense of both legs were almost normal. The pinprick sensation of both legs was decreased, below the L1 level in the right leg and below the knee in the left leg. There were no pathologic reflexes.

Complete blood counts were normal with white blood cell count of 6,400/ μ L (neutrophils 75.7%, lymphocytes 15.3%, and monocytes 8%), hemoglobin level of 11.0 g/dL, and platelet count of 297,000/ μ L. Her C-reactive protein was normal at 0.34 mg/dL (reference range 0 to 0.5 mg/dL) but her erythrocyte sedimentation rate was elevated at 57 mm/h (reference range 0 to 20 mm/h). Other laboratory test results, including renal and liver function tests, blood electrolyte levels, coagulation tests, serum B12, and folate were normal. Serum anti-MAG antibody and anti-ganglioside antibodies, such as anti-GM1, anti-GQ1b, and GD1b, were negative. There was no monoclonal band on protein electrophoresis. Routine screening tests for hepatitis, cryoglobulinemia, thyroid tests, and antinuclear antibody were negative. A genetic study of hereditary neuropathy with liability to pressure palsy was negative. Paraneoplastic antibodies were negative. Rheumatoid factor was 133.0 IU/mL (reference range 0 to 15 IU/mL) and anti-cyclic citrullinated peptide antibody was positive (25 U/mL) (reference range <7.0 U/mL).

Nerve conduction studies showed the presence of definite conduction block in the bilateral median and left radial nerves (Figure 1). A significant decrease in motor conduction velocity was evident in both the median nerves. Sensory conduction studies of the bilateral median, radial, ulnar and sural nerves were unremarkable. Additionally, brain magnetic resonance imaging was

normal. Based on the neurologic data, she was diagnosed with MMNCB following treatment with infliximab. This therapy with infliximab was thus discontinued and intravenous immunoglobulin (IVIG), 400 mg/kg daily, for 5 days was immediately started. Three months after IVIG infusion, her muscle weakness was neither progressive nor improved and follow-up nerve conduction studies showed no interval change compared with the previous study (Figure 2).

Three months after discontinuing infliximab treatment, she suffered hand arthralgia again and swelling and tenderness of both wrists and both hand proximal interphalangeal joints were identified. A 125 mg subcutaneous injection of abatacept was then started. While considering an evaluation of treatment, she decided to receive follow-up evaluations at a hospital nearer her home and she was transferred to that facility.

DISCUSSION

There have been several reports of adverse neurological events associated with anti-TNF therapy and there are several theories on the mechanism of anti-TNF therapy-induced neuropathy. Anti-TNF therapy decreases the regression of myelin-specific T-cell reactivity because TNF- α inhibits T-cell reactivity to autoantigens. The prolonged survival of activated T-cells increases cytokine production. By interrupting the equilibrium of the immune system, these immunoregulatory changes can lead to neuropathy [5]. Other reports of immunoregulatory changes related to anti-TNF therapy include increased antigen-presenting cell function and T-cell signaling that lead to an attendant increased production of either Th1 or Th2 cytokines in cavities that restrict the entrance of these agents [7]. Other theories to explain the adverse effect of anti-TNF therapy are either an ischemic mechanism or vasculitis. Vasculitis after anti-TNF therapy is induced by the immune complex deposits on the walls of small blood vessels [2]. Various mechanisms for this have been suggested, and these remain the subject of speculation and debate with no consensus as yet.

Solomon et al. [8] reported previously that etanercept, a soluble and dimeric fusion protein of the human p75 TNF receptor linked to the Fc portion of human immunoglobulin (Ig)G1, is associated with most cases of central nervous system syndromes, whereas a smaller number of central neurological complications were related to adalimumab and infliximab, an anti-TNF monoclonal.

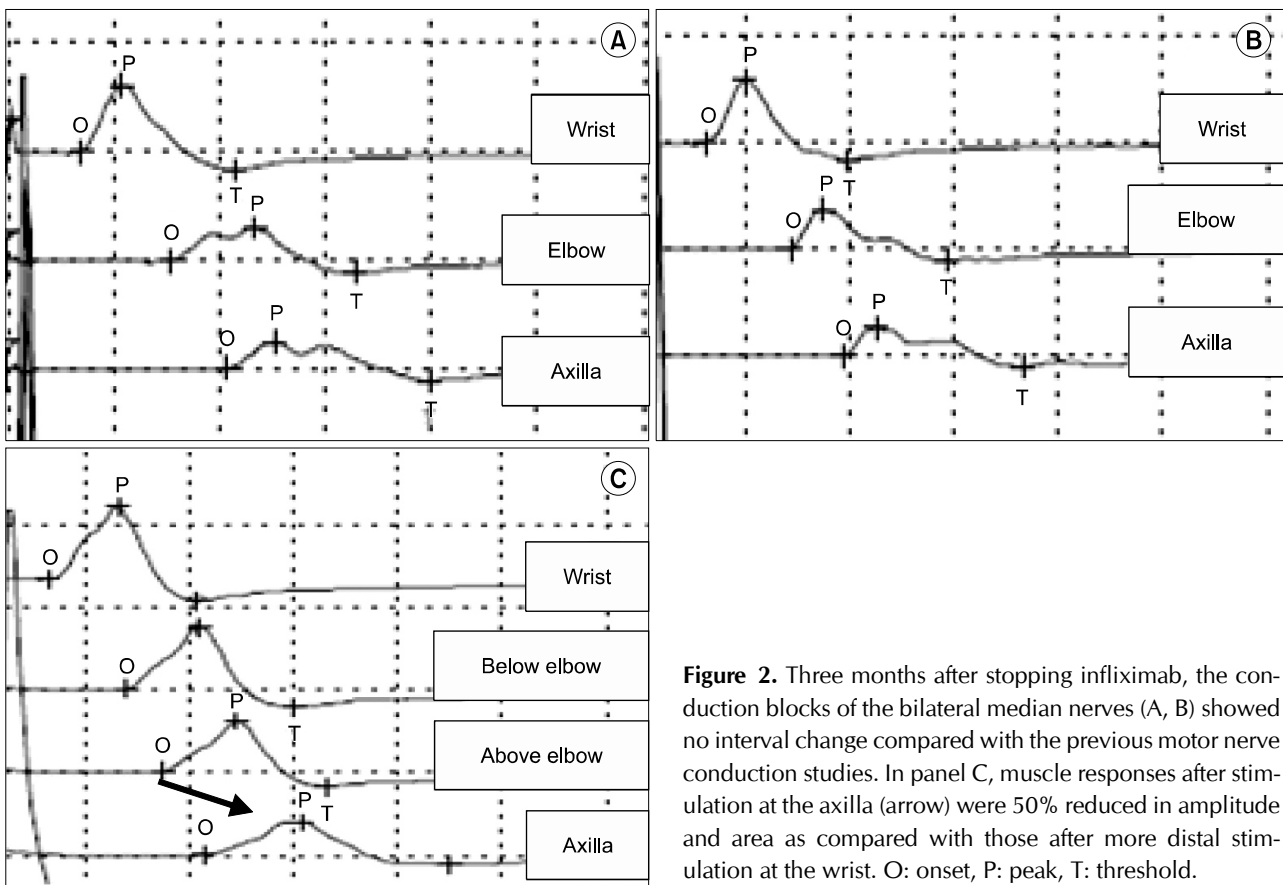


Figure 2. Three months after stopping infliximab, the conduction blocks of the bilateral median nerves (A, B) showed no interval change compared with the previous motor nerve conduction studies. In panel C, muscle responses after stimulation at the axilla (arrow) were 50% reduced in amplitude and area as compared with those after more distal stimulation at the wrist. O: onset, P: peak, T: threshold.

Interestingly, the cases in that series treated with infliximab were mostly related to optic neuritis and neuromuscular syndromes such as MMNCB.

According to previous reports of anti-TNF agents-related MMNCB cases, most MMNCB patients were treated with infliximab, except for only one case that was treated with both infliximab and etanercept (Table 1) [6,9-19]. This is consistent with the treatment profile in the case series described by Solomon et al. [8]. It is unclear why MMNCB is mainly associated with infliximab therapy and further studies are needed to confirm these findings. As indicated by Table 1, anti-TNF agents were immediately stopped after MMNCB diagnosis in most previous cases. In addition, some of these patients were treated with IVIG, high-dose methylprednisolone, or plasma exchange. Regardless of the additional management approach, most previous MMNCB patients showed improvement in their symptoms after the discontinuation of anti-TNF agent therapies.

Our current patient showed slow, stepwise, progressive, and asymmetric limb weakness for several months after infliximab therapy. A nerve conduction study and electro-

myogram revealed a motor conduction block in this patient with normal sensory nerve conduction in the arms segments. These findings indicated MMN, according to established diagnostic criteria [5]. Although caution should be used when making a causal connection between anti-TNF agents and MMNCB, infliximab-induced MMNCB could be considered a possibility based on proposed criteria [20] i.e., temporal association (the cardinal symptoms/signs occurred after exposure to TNF antagonists); lack of likely alternative explanations (clinical manifestation and diagnostic evaluations, including the absence of IgM anti-GM1 antibodies and nerve conduction study results matching MMNCB); biologic plausibility (anti-TNF agents block a cytokine playing a crucial role in many aspects of the immune system); analogy (there are prior published reports); and specificity (the defining symptoms and laboratory findings of the disorder are the same as those seen in previous cases).

There is no the definite treatment for this complication [21]. However, permanent weakness and disability in patients with MMN are determined by the duration without IVIG treatment and the amount of axon loss [21].

Table 1. Published cases of multifocal motor neuropathy with conduction block occurring after anti-TNF treatment

	Singer et al. [9]	Cocito et al. [10]	Rodriguez-Escalera et al. [11]	Tektonidou et al. [12]	Fardet et al. [13]	Lozeron et al. [14]	Paolazzi et al. [15]	Carrilho et al. [16]	Theibich et al. [17]	Kim et al. [6]	Fernández-Menéndez et al. [18]
No. of patients	2 (2*)	1	1	1 (2*)	1 (7*)	1 (5*)	1	1	1 (6)*	1	1
age/sex	28/F (A); 45/F (B)	40/F	34/F	60/M	39/M	45/M	54/M	64/F	57/M	49/F	24/M
Underlying disease	CD (A); collagenous colitis and seronegative arthritis (B)	RA	Symmetric polyarthritis	RA	HS	PsA	AS	CD	PsA	AS	CD
Predisposing anti-TNF agents	Infliximab	Infliximab	Infliximab	Infliximab	Infliximab	Infliximab; etanercept	Infliximab	Infliximab	Infliximab	Infliximab	Infliximab
Type of neuropathy	Predominantly motor neuropathy with CB [†]	MMNCB	MMNCB	MMNCB	MMNCB	MMNCB [†]	MMNCB	MMNCB	MMNCB	MMNCB	MMN-like disease
Duration from symptoms to active management	Less than 3 wk (A); about 4 mo (B)	4 mo	Not described	Not described	Not described	4 wk	11 mo	Not described	Not described	Not described	About 2 mo
Treatment for neuropathy	HD IV MP (A); none (B)	IVIG	IVIG	IVIG	Not described	IVIG; secondarily IVIG+PE	None	None	None	None	IVIG
Duration of follow-up after treatment termination	5 wk (A); 3 mo (B)	13 mo	6 mo	4 mo	Not described	3 mo	10 mo	6 mo	Not described	3 mo	5 mo
Improvement	Partial (A); marked (B)	Marked	Complete	Complete	Not described	Complete	Marked	Marked	No further progression	Marked	Marked

AS: ankylosing spondylitis, CB: conduction block, CD: Crohn's disease, F: female, HS: hidradenitis suppurativa, IVIG: intravenous immunoglobulin, HD IV MP: high dose intravenous methylprednisolone (1g/d, 3 days), M: male, MMN: multifocal motor neuropathy, MMNCB: multifocal motor neuropathy with conduction block, ND: not determined, PE: plasma exchange, PsA: psoriatic arthritis, RA: rheumatoid arthritis, TNF: tumor necrosis factor. * Number in parentheses is the total number of patients who are reported in the case. [†] Three cases were considered to represent acute MMN [19].

Therefore, early recognition of MMN and its proper treatment is very important. If a patient with anti-TNF therapy presents new or unusual neurological symptom, physicians should consider adverse events and the discontinuance of anti-TNF agents, proper evaluation, and a treatment such as IVIG.

SUMMARY

We report a case of infliximab-induced MMN in a patient with RA. Patients who treated with anti-TNF agents should be monitored for signs and symptoms of neurological disease associated with anti-TNF therapy.

CONFLICT OF INTEREST

No potential conflict of interest relevant to this article was reported.

REFERENCES

- Choy EH, Panayi GS. Cytokine pathways and joint inflammation in rheumatoid arthritis. *N Engl J Med* 2001;344:907-16.
- Stübgen JP. Tumor necrosis factor- α antagonists and neuropathy. *Muscle Nerve* 2008;37:281-92.
- Lin J, Ziring D, Desai S, Kim S, Wong M, Korin Y, et al. TNF α blockade in human diseases: an overview of efficacy and safety. *Clin Immunol* 2008;126:13-30.
- Kaltsounoudis E, Voulgari PV, Konitsiotis S, Drosos AA. Demyelination and other neurological adverse events after anti-TNF therapy. *Autoimmun Rev* 2014;13:54-8.
- Vlam L, van der Pol WL, Cats EA, Straver DC, Piepers S, Franssen H, et al. Multifocal motor neuropathy: diagnosis, pathogenesis and treatment strategies. *Nat Rev Neurol* 2011;8:48-58.
- Kim RB, Kang DH, Lee SY, Han JS, Lim SK, Song SH, et al. Multifocal motor neuropathy with conduction blocks during TNF- α antagonist therapy in a patient with spondyloarthropathy. *J Rheum Dis* 2013;20:177-80.
- Magnano MD, Robinson WH, Genovese MC. Demyelination and inhibition of tumor necrosis factor (TNF). *Clin Exp Rheumatol* 2004;22(5 Suppl 35):S134-40.
- Solomon AJ, Spain RI, Kruer MC, Bourdette D. Inflammatory neurological disease in patients treated with tumor necrosis factor α inhibitors. *Mult Scler* 2011;17:1472-87.
- Singer OC, Otto B, Steinmetz H, Ziemann U. Acute neuropathy with multiple conduction blocks after TNF α monoclonal antibody therapy. *Neurology* 2004;63:1754.
- Cocito D, Bergamasco B, Tavella A, Poglio F, Paolasso I, Costa P, et al. Multifocal motor neuropathy during treatment with infliximab. *J Peripher Nerv Syst* 2005;10:386-7.
- Rodriguez-Escalera C, Belzunegui J, Lopez-Dominguez L, Gonzalez C, Figueroa M. Multifocal motor neuropathy with conduction block in a patient with rheumatoid arthritis on infliximab therapy. *Rheumatology (Oxford)* 2005;44:132-3.
- Tektonidou MG, Serelis J, Skopouli FN. Peripheral neuropathy in two patients with rheumatoid arthritis receiving infliximab treatment. *Clin Rheumatol* 2007;26:258-60.
- Fardet L, Dupuy A, Kerob D, Levy A, Allez M, Begon E, et al. Infliximab for severe hidradenitis suppurativa: transient clinical efficacy in 7 consecutive patients. *J Am Acad Dermatol* 2007;56:624-8.
- Lozeron P, Denier C, Lacroix C, Adams D. Long-term course of demyelinating neuropathies occurring during tumor necrosis factor- α -blocker therapy. *Arch Neurol* 2009;66:490-7.
- Paolazzi G, Peccatori S, Cavatorta FP, Morini A. A case of spontaneously recovering multifocal motor neuropathy with conduction blocks (MMNCB) during anti-TNF α therapy for ankylosing spondylitis. *Clin Rheumatol* 2009;28:993-5.
- Carrilho PE, Araújo AC, Alves O, Kotze PG. Motor neuropathy with multiple conduction blocks associated with TNF- α antagonist. *Arq Neuropsiquiatr* 2010;68:452-4.
- Theibich A, Dreyer L, Magyari M, Loch H. Demyelinating neurological disease after treatment with tumor necrosis factor α -inhibiting agents in a rheumatological outpatient clinic: description of six cases. *Clin Rheumatol* 2014;33:719-23.
- Fernández-Menéndez S, González Nafria N, Redondo-Robles L, Sierra-Ausín M, García-Santiago R, Saponaro-González A. Multifocal-motor-neuropathy-like disease associated with Infliximab treatment in a patient with Crohn's disease. *J Neurol Sci* 2015;349:246-8.
- Barber CE, Lee P, Steinhart AH, Lazarou J. Multifocal motor neuropathy with conduction block following treatment with infliximab. *J Rheumatol* 2010;37:1778-80.
- Miller FW, Pollard KM, Parks CG, Germolec DR, Leung PS, Selmi C, et al. Criteria for environmentally associated autoimmune diseases. *J Autoimmun* 2012;39:253-8.
- Tristano AG. Neurological adverse events associated with anti-tumor necrosis factor α treatment. *J Neurol* 2010;257:1421-31.