

A Case of Bad Prognosis for Membranous Nephropathy in a Patient with Mixed Connective Tissue Disease

Mi Young Kim², Ho Seok Koo¹, Young Ki Seo², Jung Hwa Min², Kyung Jin Lee², Soo Yeon Jo², Haeng Il Koh¹

¹Division of Nephrology, ²Department of Internal Medicine, Inje University Seoul Paik Hospital, Inje University College of Medicine, Seoul, Korea

Incidence of renal involvement in mixed connective tissue disease (MCTD) is low. In the presence of glomerulonephritis, membranous nephropathy (MN) in MCTD is common. A 47-year-old woman presented with hypothyroidism. She developed Raynaud's phenomenon, arthralgia, and incomplete lupus erythematosus, diagnosed with MCTD. One year after then, the patient developed persistent proteinuria (1+) without hematuria. Following diagnosis with MCTD, her renal function began to deteriorate. The renal biopsy showed late stage MN. For the treatment of MN with mild proteinuria and MCTD, we prescribed an angiotensin II receptor blocker and 7.5 mg of methotrexate per week and 300 mg of hydroxychloroquine daily. The patient had a reduced estimated glomerular filtration rate of 55% for the subsequent eight years. The MN in MCTD is known to show good renal prognosis. Here, we report on a rare case of MN in MCTD in Korea with a bad prognosis. (*J Rheum Dis* 2015;22:260-262)

Key Words. Mixed connective tissue disease, Glomerulonephritis, Membranous glomerulonephritis

INTRODUCTION

Mixed connective tissue disease (MCTD) is characterized by overlapping clinical features of systemic lupus erythematosus, systemic sclerosis, polymyositis, and very high titers of anti-U1 RNP antibodies. The clinical manifestations of MCTD include Raynaud phenomenon and arthralgia [1,2]. Incidence of renal involvement in MCTD is lower (approximately 10%) than any other composite disease. Severe renal disease is rare in MCTD, as the presence of anti-U1 RNP antibodies may protect against renal involvement [1,3]. In the presence of glomerulonephritis, the membranous nephropathy (MN) in MCTD is as common as any other glomerulonephritis [4]. The prognosis of MN in MCTD is good, with most cases only having mild proteinuria and preserved renal function [5,6]. Here, we report a case MN of MCTD with rapid deterioration of renal function, with details on the late stage case of MN in MCTD with a bad prognosis.

CASE REPORT

Twenty-one years before her MCTD diagnosis, a 47-year-old woman presented with hypothyroidism. Two years before the MCTD diagnosis, the patient also experienced Raynaud's phenomenon. The patient developed morning stiffness, joint swelling (proximal interphalangeal, metacarpophalangeal), and incomplete lupus erythematosus (arthritis, anti-double-stranded DNA [anti-dsDNA] [+], fluorescent antinuclear antibody [FANA] [+]) at the time she was diagnosed with MCTD. The patient showed symptoms including swollen fingers, synovitis, and Raynaud's phenomenon. The rheumatoid arthritis factor was 480.3 IU/mL. The patient was anti-RNP antibody-positive (238.2 U/mL) with a speckled antinuclear antibody of 1:1,280. Consequently, the patient was diagnosed with MCTD based on the diagnostic criteria [7]. She began a treatment regimen consisting of 7.5 mg of methotrexate per week, 300 mg of hydroxy-

Received : June 9, 2014, **Revised :** (1st) August 11, 2014, (2nd) September 22, 2014, **Accepted :** September 22, 2014

Corresponding to : Ho Seok Koo, Division of Nephrology, Department of Internal Medicine, Inje University Seoul Paik Hospital, Inje University College of Medicine, 9 Mareunnae-ro, Jung-gu, Seoul 04551, Korea. E-mail : hoseok.koo@gmail.com

pISSN: 2093-940X, eISSN: 2233-4718

Copyright © 2015 by The Korean College of Rheumatology. All rights reserved.

This is a Free Access article, which permits unrestricted non-commercial use, distribution, and reproduction in any medium, provided the original work is properly cited.

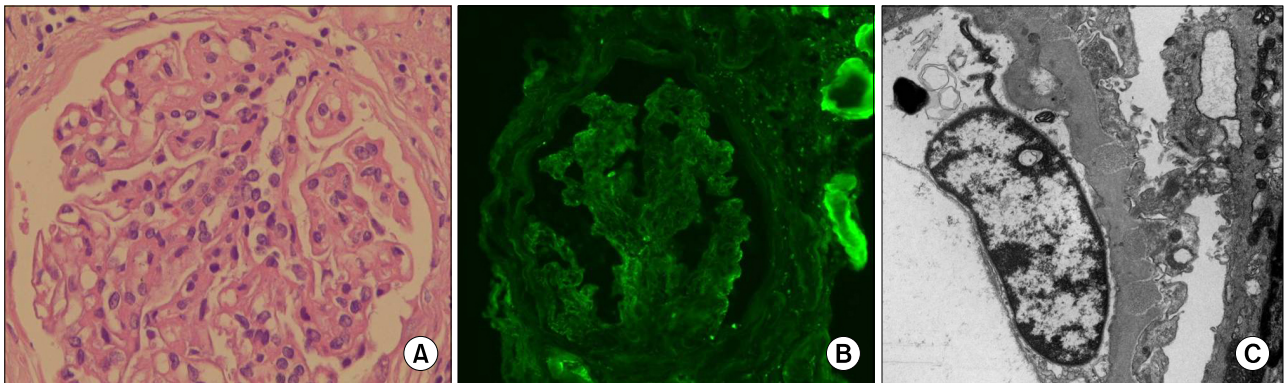


Figure 1. (A) Glomeruli sclerosis of 23.1% involves mesangial cells and endothelial cells (H&E, $\times 400$). (B) Immunoglobulin G was slightly stained in the periphery (IF, $\times 400$). (C) Electron-dense deposits were in some subepithelial and intramembranous deposits. The diffuse effacement of podocyte foot process and a dome and spike formation were evident (EM, $\times 10,000$).

chloroquine and 7.5 mg of meloxicam (an non-steroidal anti-inflammatory drug, NSAID) daily.

In 2004, proteinuria and hematuria were not present. The patient's renal function was normal (0.8 mg/dL, estimated glomerular filtration rate [GFR]: 80 mL/min/1.73 m²). However, the patient's renal function began to deteriorate in 2005. While on an angiotensin II receptor blocker (ARB), her blood pressure was 130/95 mmHg. When she was admitted for a renal biopsy, she was in a state of stage 3 chronic kidney disease (modification of diet in renal disease [MDRD] estimated glomerular filtration rate [eGFR]: 39.6 mL/min/1.73 m²) with proteinuria. The decreased eGFR was 0.55 mL/min/1.73 m² per month. On admission, the patient's systolic blood pressure was 120 mmHg and her diastolic blood pressure was 80 mmHg. Her body temperature was normal. A physical examination revealed no abnormalities of skin, muscle, joints, or extremities. Laboratory test results included the following: hemoglobin, 12.6 g/dL; white blood cell, 4,540/mm³ (lymph 39.4%); platelet, 161,000/mm³; serum total protein, 7.2 g/dL; albumin, 3.5 g/dL; blood urea nitrogen, 17 mg/dL; creatinine, 1.69 mg/dL; serum C3, 88 mg/dL; serum C4, 16 mg/dL; CH50, 39 IU/mL; FANA, positive at 1:1,280 with a speckled pattern; anti-dsDNA, negative; anti-Jo Ab (–); anti-centromere Ab (–); anti-SCL 70 Ab (–); proteinuria, 1+; and red blood cell, 0-1/HPF in urinalysis. The amount of 24-hour proteinuria was 0.813 g. Result of renal biopsy was late stage MN with glomerular collapse, global sclerosis (23.1%), segmental sclerosis (30.8%), irregular thickening with irregular inner and outer contours of the glomerular basement membrane (GBM), focal tubular atrophy, tubulitis, and mild focal hypercellularity in the mesangial and endothelial

cells (Figure 1). To treat MN which showed only mild proteinuria, we used an ARB. After receiving the ARB, the patient's proteinuria improved from 1+ to negative or trace with spot urine protein creatinine ratio of 0.67 g/g creatinine. One year ago, her NSAID administration was stopped. Currently, hydrochloroquine is being prescribed for the treatment of MCTD. The last level of serum creatinine was 1.40 mg/dL, with MDRD eGFR at 40 mL/min/1.73 m².

DISCUSSION

According to the literature, all NSAIDs can induce MN [8]. In one study, authors suggested that MN were caused by NSAIDs [8]. The authors stated that: NSAIDs are the only cause of MN; proteinuria improves within 1 to 36 weeks after NSAID cessation; proteinuria does not recur after 5 to 13 weeks following NSAID cessation. To diagnose MN caused by NSAIDs, all criteria should be met [8]. In our patient, the proteinuria was maintained and the eGFR was decreased even after a year of NSAID cessation.

In our patient, the rate of renal function loss was 55% for the eight years following the MCTD diagnosis. The known renal function preservation rate was 80% in idiopathic MN for the same period [9]. There are no studies on the rate of renal function loss in MCTD. If U1-RNP has a protective effect on MCTD, then NSAIDs could have caused the renal function to deteriorate in our patient. But after a year of NSAID cessation, there was no change in the proteinuria or eGFR. Further studies are needed to clarify whether the symptoms of MCTD can be controlled without NSAIDs.

Poor prognostic factors in idiopathic MN include age, sex, race, hypertension, serum albumin, serum cholesterol, serum creatinine at the time of clinical manifestation, and urine protein (nephrotic syndrome, 24-hour urine protein > 8 g for six months). In a renal biopsy, focal sclerosis and tubulointerstitial disease are also poor prognostic factors [10]. The poor prognostic factor in our patient was hypertension based on light microscopy assay. Our patient showed 23.1% global sclerosis, 30.8% segmental sclerosis, focal tubulitis, and interstitial fibrosis. Moreover, there was a 30.8% glomerular collapse with GBM of irregular thickening with irregular inner and outer contours, indicating late stage of MN.

In other case reports [11,12], light microscopy did not show sclerosis. We could not compare the prognosis because there is no previous report on the stage of MN in MCTD. There have been reports on the prognosis of renal involvement in MCTD [6]. However, those reports did not include descriptions on the type of MN. The renal involvement was not shown in the patients who died or had active disease. To determine the renal prognosis, we must know the type of glomerulonephritis, change of the eGFR, and changes in proteinuria and hematuria. However, this information was unavailable in previous case reports. Therefore, we cannot determine the precise prognosis. In another case report involving six patients with MN, only one patient fully recovered from acute renal failure [6]. Other patients showed normal creatinine levels during an observation period of 10.1 ± 1.8 years. There was no information about the prognostic factors of MN, so we could not determine the precise prognosis [6]. In one case report [11], the proteinuria improved from 3+ to 1+ within 24 months after treatment with prednisolone, but the renal function declined due to chemotherapy for lymphoma.

Up to now, there are few studies about the renal prognosis of MN in MCTD. NSAIDs used for management of MCTD symptoms can be a cause of MN. Proteinuria can be an indicator of nephropathy in MCTD. Use of routine urinalysis and renal biopsy should be considered in patients with MCTD to avoid the toxic effects of NSAIDs. The low rate of renal involvement in MCTD is its hallmark. There are some reports that the rate of renal involvement could be up to 25%. However, there is no report about MN in MCTD in Korea. Therefore, this is the first report on the prognosis of MN in MCTD in Korea.

SUMMARY

Renal prognosis of MN in MCTD is generally known to be good. Here, we report a rare case of MN in MCTD in Korea with a bad prognosis.

CONFLICT OF INTEREST

No potential conflict of interest relevant to this article was reported.

REFERENCES

1. Sharp GC, Irvin WS, Tan EM, Gould RG, Holman HR. Mixed connective tissue disease: an apparently distinct rheumatic disease syndrome associated with a specific antibody to an extractable nuclear antigen (ENA). *Am J Med* 1972;52:148-59.
2. Aringer M, Smolen JS. Mixed connective tissue disease: what is behind the curtain? *Best Pract Res Clin Rheumatol* 2007;21:1037-49.
3. Sharp GC, Irvin WS, May CM, Holman HR, McDuffie FC, Hess EV, et al. Association of antibodies to ribonucleoprotein and Sm antigens with mixed connective-tissue disease, systematic lupus erythematosus and other rheumatic diseases. *N Engl J Med* 1976;295:1149-54.
4. Pope JE. Other manifestations of mixed connective tissue disease. *Rheum Dis Clin North Am* 2005;31:519-33.
5. Burdt MA, Hoffman RW, Deutscher SL, Wang GS, Johnson JC, Sharp GC. Long-term outcome in mixed connective tissue disease: longitudinal clinical and serologic findings. *Arthritis Rheum* 1999;42:899-909.
6. Kitridou RC, Akmal M, Turkel SB, Ehresmann GR, Quismorio FP Jr, Massry SG. Renal involvement in mixed connective tissue disease: a longitudinal clinicopathologic study. *Semin Arthritis Rheum* 1986;16:135-45.
7. Alarcón-Segovia D, Cardiel MH. Comparison between 3 diagnostic criteria for mixed connective tissue disease. Study of 593 patients. *J Rheumatol* 1989;16:328-34.
8. Radford MG Jr, Holley KE, Grande JP, Larson TS, Wagoner RD, Donadio JV, et al. Reversible membranous nephropathy associated with the use of nonsteroidal anti-inflammatory drugs. *JAMA* 1996;276:466-9.
9. Schieppati A, Mosconi L, Perna A, Mecca G, Bertani T, Garattini S, et al. Prognosis of untreated patients with idiopathic membranous nephropathy. *N Engl J Med* 1993;329:85-9.
10. Reichert LJ, Koene RA, Wetzels JF. Prognostic factors in idiopathic membranous nephropathy. *Am J Kidney Dis* 1998;31:1-11.
11. McLeish KR, Smith MR, Gohara AF. Non-Hodgkin's lymphoma and membranous nephropathy in mixed connective tissue disease. *Am J Med Sci* 1985;290:152-4.
12. Kobayashi S, Nagase M, Kimura M, Ohyama K, Ikeya M, Honda N. Renal involvement in mixed connective tissue disease. Report of 5 cases. *Am J Nephrol* 1985;5:282-9.