



독시사이클린에 의한 말라리아 신속검사의 위음성 결과 1예

A Case of False-negative Malaria Rapid Diagnostic Test Induced by Treatment with Doxycycline

임재형 · 백은정

Jae-Hyung Lim, M.D., Eun Jung Baek, M.D.

한양대학교 의과대학 진단검사의학과

Department of Laboratory Medicine, College of Medicine, Hanyang University, Seoul, Korea

Rapid diagnostic tests (RDTs) for malaria using antibodies against pan-*Plasmodium* antigen lactate dehydrogenase (pLDH) are commonly used for malaria diagnosis. The level of malaria parasitemia determined by peripheral blood smears (PBS) correlates with the pLDH concentration in most cases. We report a case of malaria recurrence associated with false-negative RDT results. A 22-year-old male patient was admitted to the Armed Forces Capital Hospital with fever and chills, and was diagnosed with malaria infection. Four days after antimalarial treatment, these symptoms recurred. After admitting to our hospital, doxycycline was administered for 4 days. Even after administration of doxycycline, the malaria parasites in blood smears remained positive, but RDT showed negative results. Therefore, for patients receiving doxycycline, serial blood smear testing should be performed to exclude false-negative malaria RDT results.

Key Words: Malaria, Rapid diagnostic test, Peripheral blood smear, Doxycycline, Lactate dehydrogenase

INTRODUCTION

Rapid diagnostics tests (RDTs) using anti-pan-*Plasmodium* lactate dehydrogenase (pLDH) antibody have been widely used along with peripheral blood smears (PBS) for the diagnosis of malaria. Malaria parasitemia, as determined by PBS, correlates with pLDH concentration in most cases [1]. Here, we report a case of malaria recurrence associated with false-negative RDT results, suggesting

that caution must be exercised in the diagnosis of malaria when using anti-pLDH antibody.

CASE

A 22-year-old man was admitted to the hospital following 4 days of fever and chills. One month prior, the patient, with no remarkable medical history, was admitted to the Armed Forces Capital Hospital and was diagnosed with malaria. He was administered chloroquine for 3 days and primaquine for 11 days, and his symptoms subsided. However, the symptoms recurred 4 days before admission to our hospital. On admission, his leukocyte count was 6,400/ μ L; hemoglobin, 14.8 g/dL; platelet, 78,000/ μ L; and C-reactive protein was elevated, 3.61 mg/dL. No pathogens were isolated from sputum or throat cultures. PBS was performed and more than 300 fields were examined at high magnification ($\times 400$). At the time of admission, both PBS and RDT (Malaria Ag Pf/Pan test, Standard Diagnostics, Yongin, Korea) results were negative.

Due to negative RDT and PBS results and low clinical suspicion

Corresponding author: Eun Jung Baek, M.D., Ph.D.

<https://orcid.org/0000-0001-5477-6486>

Department of Laboratory Medicine, Hanyang University Guri Hospital,
153 Gyeongchun-ro, Guri 11923, Korea

Tel: +82-31-560-2485, Fax: +82-31-560-2489, E-mail: doceunjung@hanyang.ac.kr

Received: October 2, 2018

Revision received: October 10, 2018

Accepted: October 11, 2018

This article is available from <http://www.labmedonline.org>

© 2019, Laboratory Medicine Online

© This is an Open Access article distributed under the terms of the Creative Commons Attribution Non-Commercial License (<http://creativecommons.org/licenses/by-nc/4.0/>) which permits unrestricted non-commercial use, distribution, and reproduction in any medium, provided the original work is properly cited.

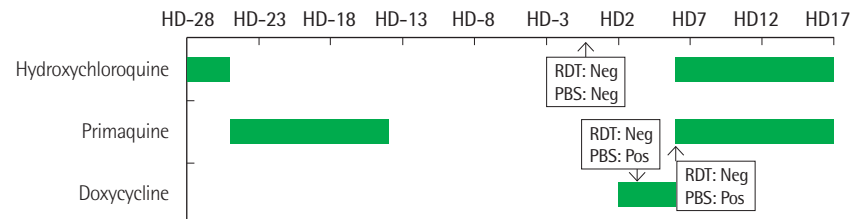


Fig. 1. Flow chart of diagnostic tests and treatments.

Abbreviations: HD, hospital day of admission; RDT, rapid diagnostic test; PBS, peripheral blood smear; Neg, negative; Pos, positive.

of malaria reinfection or recurrence, clinicians initiated a course of doxycycline for suspected epidemic hemorrhagic fever (EHF). On the 3rd day of hospitalization, PBS was repeated and yielded a positive result with a titer of 1,131/ μ L, rising to 1,360/ μ L on the 5th day. However, RDTs performed on both days remained negative. The patient was administered hydroxychloroquine and primaquine, and PBS results were negative after three days of treatment; he was discharged 10 days after admission (Fig. 1).

To evaluate the inconsistency between the RDT and PBS results on the 3rd and 5th days, the RDT was re-evaluated using internal quality control samples, but the results did not differ. A prozone phenomenon due to a high level of pLDH has been previously described [2], so to investigate this potential explanation, the specimens were diluted 2 and 4 times with normal saline; however, the results of this test were also negative.

DISCUSSION

Diagnosis of malaria based only on RDTs is cost-effective and operationally advantageous, since RDTs are easy to perform and provide results rapidly [3]. Most RDTs detect parasite histidine-rich protein 2 (pHRP-2) and pLDH from *Plasmodium falciparum* and *Plasmodium* spp., respectively. While the pHRP-2 antigen can be detected up to 40 days post-antibiotics treatment [4], the pLDH antigen has very short half-life of less than 2 days, and the median time on treatment for this test to become negative was reported as just 2 days [5]. Even though RDTs show good correlation with PBS results and can be used for evaluation of the treatment response and follow-up, low blood levels of pLDH can lead to false-negative results [1, 6]. We were not able to evaluate the pLDH level in this patient's sample; the parasitemia was much higher than that reported previously with low detectable pLDH (<1,000/ μ L) [1, 6]. Similarly, Jang et al. [1] reported 7 cases of high parasitemia with

low pLDH levels, but did not provide additional detailed data regarding treatment history. pLDH levels reflect the level of viable parasitemia [7], and the World Health Organization guidelines also state that parasitemia is the most important criteria for confident diagnosis [8].

In this case, we suspect that doxycycline administration may have influenced the RDT results. Doxycycline exhibits antimicrobial activity via inhibition of bacterial cell wall synthesis and eliminates malarial parasites in hepatocytes. Due to its effectiveness, doxycycline is administered as a therapeutic and preventive drug for malaria [9]. Despite a lack of studies reporting a direct association between doxycycline treatment and RDT results, Pasricha et al. [10] showed that 50% of patients with malarial infection and negative PBS and RDT results at the time of admission, had a history of treatment with doxycycline. Even though anti-malarial drugs decrease the number of parasites in the blood [11], in our case, the malarial parasite titers were not low. These reports suggest that antibiotics administration lowered the pLDH concentration due to a decreased number of viable parasites, resulting in false-negative RDT results. Therefore, in patients receiving doxycycline, serial PBS testing should be performed to exclude false-negative malarial RDT results. Further studies are required to elucidate the effect of doxycycline administration on RDT results.

요약

pan-*Plasmodium* antigen lactate dehydrogenase (pLDH)에 대한 항체를 이용하는 말라리아 신속검사는 말초혈액도말법과 함께 말라리아 감염을 진단하는 대표적인 검사 방법이다. 혈청에서의 pLDH의 농도는 말초혈액도말법에서 확인할 수 있는 말라리아 원충수와 상관관계가 있다고 알려져 있다. 우리는 말초혈액도말법에서 말라리아 원충을 관찰할 수 있었지만 신속검사에서 위음성 결과가 보고된 증례를 보고하고자 한다. 22세 남자 환자가 발열과 오

한으로 국군수도병원으로 내원하였고 말라리아 감염으로 진단 후 치료받았다. 치료 종료 후 4일째부터 다시 증상이 재발하여 독시사이클린을 4일간 투약했다. 독시사이클린 투여 후 말초혈액도말법에서 말라리아 원충이 지속적으로 관찰되었지만 신속검사에서는 위음성으로 일관되게 보고되었다. 신속검사와 독시사이클린 간의 연관성을 배제할 수 없기 때문에 독시사이클린을 투여받은 환자들은 말초혈액도말법을 통하여 말라리아 신속검사 결과를 확인해야 할 것이다.

AUTHORS' DISCLOSURES OF POTENTIAL CONFLICTS OF INTEREST

No potential conflicts of interest relevant to this article were reported.

REFERENCES

1. Jang JW, Cho CH, Han ET, An SS, Lim CS. pLDH level of clinically isolated *Plasmodium vivax* and detection limit of pLDH based malaria rapid diagnostic test. *Malar J* 2013;12:181.
2. Gillet P, Scheirlinck A, Stokx J, De Weggheleire A, Chauque HS, Canhanga OD, et al. Prozone in malaria rapid diagnostics tests: how many cases are missed? *Malar J* 2011;10:166.
3. Kim HS, Kang G, Lee S, Yoon CG, Kim M. Cost-benefit analysis of malaria chemoprophylaxis and early diagnosis for Korean soldiers in malaria risk regions. *J Korean Med Sci* 2018;33:e59.
4. Dalrymple U, Arambepola R, Gething PW, Cameron E. How long do rapid diagnostic tests remain positive after anti-malarial treatment? *Malar J* 2018;17:228.
5. Grandesso F, Nabasumba C, Nyehangane D, Page AL, Bastard M, De Smet M, et al. Performance and time to become negative after treatment of three malaria rapid diagnostic tests in low and high malaria transmission settings. *Malar J* 2016;15:496.
6. Fogg C, Twesigye R, Batwala V, Piola P, Nabasumba C, Kiguli J, et al. Assessment of three new parasite lactate dehydrogenase (pan-pLDH) tests for diagnosis of uncomplicated malaria. *Trans R Soc Trop Med Hyg* 2008;102:25-31.
7. Piper R, Lebras J, Wentworth L, Hunt-Cooke A, Houzé S, Chiodini P, et al. Immunocapture diagnostic assays for malaria using *Plasmodium* lactate dehydrogenase (pLDH). *Am J Trop Med Hyg* 1999;60:109-18.
8. World Health Organization. Guidelines for the treatment of malaria - 3rd edition. Geneva: World Health Organization, 2015:27-30.
9. Gaillard T, Madamet M, Pradines B. Tetracyclines in malaria. *Malar J* 2015;14:445.
10. Pasricha JM, Juneja S, Manitta J, Whitehead S, Maxwell E, Goh WK, et al. Is serial testing required to diagnose imported malaria in the era of rapid diagnostic tests? *Am J Trop Med Hyg* 2013;88:20-3.
11. Miller RS, McDaniel P, Wongsrichanalai C. Following the course of malaria treatment by detecting parasite lactate dehydrogenase enzyme. *Br J Haematol* 2001;113:558-9.