

Leakage of SuperEBA in root-end cavities prepared with 3 new ultrasonic tips: KaVo Isthmus, KaVo T-shape and KiS tip

Woo-Cheol Lee

Department of conservative Dentistry, School of Dentistry, Seoul National University

ABSTRACT

KAVO ISTHMUS, KAVO T-SHAPE과 KIS TIP의 3종 초음파기구로 형성한 역충전와동의 SUPEREBA 변연누출에 관한 연구

이 우 철

서울대학교 치과대학 보존학교실

치근단 수술시 구동형 수술현미경과 미세수술기구들이 사용됨에 따라 치근단 절제술 후 역충전와동의 효과적인 형성 및 충전을 위해 새로운 초음파기구가 개발되었다. 따라서 본연구에서는 최근 상품화되어 사용되고 있는 초음파기구중 신속하게 역충전와동을 형성할 뿐 아니라 충분한 깊이를 제공하여 역충전재료의 변연누출 감소에 효과적인 것으로 알려져 있는 3종의 초음파기구를 사용하여 역충전와동을 형성한 후 SuperEBA로 충전하여 그 변연누출을 비교하였다. 모두 56개의 근첨형성이 완료된 단근치를 선택하여 Profile .06를 사용하여 근관형성한 후 음성대조군 2개를 제외한 54개의 치아를 수직가압법으로 충전하였다. 근단부 3mm를 절제한 뒤 KaVo Isthmus, KaVo T-shape 그리고 KiS tip을 각각 18개의 치아에 사용하여 역충전와동을 형성하고 그중 각각 2개의 양성대조군 치아를 제외한 나머지 치아에 SuperEBA로 충전하였다. 각치아는 1% methylene blue dye에 침윤시켜 1주일 후 종절단하여 그 색소침투정도를 측정, 비교하였다. 실험결과 측정된 평균 변연누출은 KaVo Isthmus가 $1.5 \pm 1.4\text{mm}$, KaVo T-shape이 $1.7 \pm 1.2\text{mm}$ 이고 KiS tip은 $1.1 \pm 0.7\text{mm}$ 이었으며, 통계적으로 유의할만한 차이는 없었다. 따라서 초음파기구를 사용한 역충전와동의 임상기술 성공여부는 술자의 편의도와 임상적 사용시 조작능력에 달려 있는 것으로 사료된다.

I . Introduction

Endodontic treatment is known to have varying rates of success by several studies from 89 to 95%^{7,13,14}. If non-surgical retreatment of failed root canal treatment is unfeasible, surgical therapy is recommended. Periapical surgery includes resection of root apex, preparation of retrograde cavity, and improving the apical seal by filling the root end cavity. When retrograde fillings were placed, the cavity preparation was accomplished with burs. However, these fillings tend to be shallow, leaky and ineffective. Recently, ultrasonic tips are developed and introduced to prepare retrograde cavity cleaner, deeper and therefore provide enhanced retrograde seal⁶. Ultrasonic preparation also allows retrograde cavities

parallel to the long axis of the root. Ilgenstein¹⁹ has developed a new set of KaVo SONICflex retro tips, claiming fast and efficient cutting with 3 to 4mm diamond preparation surface. The retrotips are available in two shapes, Isthmus and T-shape, each in two sizes and left and right configuration. Kim also designed KiS microsurgical ultrasonic tips with six different configurations which give better access than other ultrasonic instruments.

Several materials such as amalgam, Glass ionomer cement, and zinc oxide-eugenol cement have been evaluated for clinical use as retrograde filling materials. Oynick and Oynick¹⁰ reported use of SuperEBA to be suitable root-end filling material by demonstrating in vivo healing and biological compatibility. Dorn and Gartner⁵ also reported a 95% success rate

utilizing SuperEBA as a root-end filling material. In a number of in vitro leakage studies^{1,7)} demonstrated that SuperEBA has better sealing ability compared to other root-end filling materials. However, none of these studies compares leakage created by newly designed ultrasonic tips.

The purpose of this study was to compare the leakage of SuperEBA placed into retrograde cavities prepared with 3 different ultrasonic tips: KaVo SONICflex retro Isthmus, T-shape and Obtura Spartan KiS tips.

II . Materials and Methods

56 single-rooted extracted human maxillary and mandibular teeth were collected and stored in deionized water and thymol. No previous root canal treatment had been done on the teeth, and the specimens with large restorations, cervical defects, crack, and root fractures were excluded from this study. Adherent soft tissue, periodontal ligament and calculus were removed after soaking in physiological sterile saline. Following access preparation, the working

length was determined by inserting a #10 K-file into the orifice of the canal and advancing apically until it was visible at the foramen then subtracting 1mm from this measurement. The root canals were prepared with Gates Glidden burs and Profile .06 taper rotary instruments using crown-down technique, rinsed with 2.5% sodium hypochlorite, and dried with paper points. The canals were then obturated with non-standardized gutta-percha using warm vertical technique with Obtura back fill and Grossman's sealer. Teeth were then stored in physiologic saline at 37°C for 7 days. All root-end resection procedures were executed under the surgical microscope (Carl Zeiss Inc., Thornwood, NY). As shown in flow chart (Fig. 1), the obturated teeth were randomly divided into 3 groups: KaVo SONICflex retro Isthmus, T-shape (Kaltenbach & Voigt GmbH, Biberach, Germany) and KiS tip (ObturaSpartan, Fenton, MO) preparation group, 18 teeth each. Among these, two teeth from each group served as positive controls. After decoronated the obturated teeth, the apical 3mm of each root was resected under copious water spray with diamond burs in a high-speed handpiece

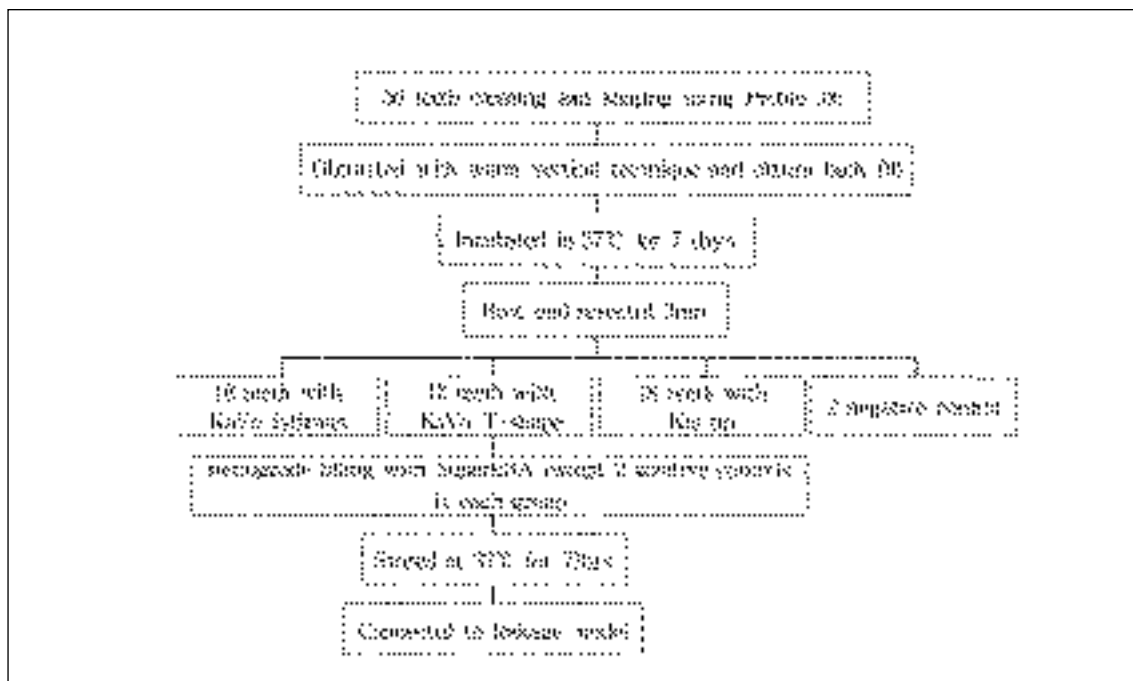


Fig. 1. Flow chart of the experimental design.

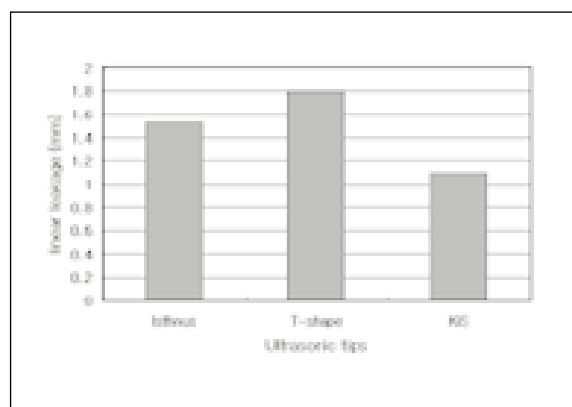


Fig. 2. Average linear leakage observed from the each experimental group.

perpendicular to the long axis of the tooth. Retrograde cavity was prepared in resected root-end to a depth of 3mm parallel to the long axis of the tooth with each ultrasonic tip (Fig. 3, 4 and 5). The retrograde cavities were judged to be completed when the gutta-percha was not seen on the wall and the cavity depth was at least 3mm measured with retrograde plugger. Cavity was then dried with air stream using Stropko irrigator (SybronEndo, Orange, CA). All retrograde cavities except six positive controls were filled with SuperEBA (Harry J. Bosworth, Skokie, IL) mixed according to manufacturer's instructions. All teeth were then stored at 37°C, 100% humidity for 72hrs. Three coats of nail varnish were applied to the external root surface except for the resected root surface before teeth were assembled in leakage model shown in Fig. 6. Two negative control teeth with no retrograde filling were covered with nail varnish on entire root surface. Teeth were suspended in an aqueous solution of 1% methylene blue (Sigma Chemical Co., St.Louis, MO) to a level 2mm from the root apex. After 2weeks, all specimens were removed from the vials, and the external surfaces of the roots were rinsed under tap water to remove excess dye. The teeth were then longitudinally grooved and split by prying with a chisel.

The amount of dye penetration of the retrograde fillings was measured using a stereomicroscope at $\times 6$ magnification. The maximum depth of penetration of dye from the resected root-end was evaluated with the aid of a calibrated eyepiece graticule. These data

were analyzed using ANOVA test to determine if there were statistically significant differences between the groups.

III. Results

Negative control demonstrated no dye leakage, while the positive controls showed dye penetration along the length of the retrograde fillings.

Linear leakage was 1.5 ± 1.4 mm in KaVo Isthmus group, 1.8 ± 1.2 mm in KaVo T-shape group, and 1.1 ± 0.7 mm in KiS tip group. Fig. 2 shows the amount of leakage for each experimental group. Fig. 7 through 9 are representative roots from each group with ultrasonic tip used.

The data revealed that the KiS tip group demonstrated less leakage than other groups, however, there were no statistically significant differences between the groups.

IV. Discussion

The results of this study demonstrated that the ultrasonic tips with which the retrograde cavity was prepared failed to influence the apical seal of SuperEBA root-end filling. However, it is noteworthy that there is difference in ease of use and ability of approaching surgical field among the ultrasonic tips. KaVo SONICflex retro Isthmus tip was designed to prepare isthmus for easier access even with complicated anatomical conditions. KaVo SONICflex retro T-shape claims that it gives better retention with T-shape retrograde cavity preparation. Fig. 10 shows both KaVo tips in high magnifications and its clinical application is shown as a diagram in Fig. 11 as well as radiographic view after retrograde filling in Fig. 12. Diamond coated KiS ultrasonic tips possess high cutting efficiency due to their increased shaft and provide better access to any anatomical situations with six tip design (Fig. 13). No.1 KiS tip was designed for anterior teeth with a tip angle of 80 degrees while No.2 KiS tip has greater diameter for larger anterior teeth. KiS No. 3 tip was fabricated with double angled 75 degree tip with good access to buccal roots of lower left or upper right molars. On the other hand, 110 degree No. 4 KiS tip gives you a

better approach to the lingual roots of the lower left or upper right posterior teeth. No. 5 and No.6 KiS tips are the other pair for opposite side teeth such as lower right or upper left molars. KiS tips also provide better visibility by strategically placed irrigation port (Fig. 14). Clinical ability of each ultrasonic tip such as accessibility or visibility cannot be evaluated in *in vitro* study, however, it can be judged by clinicians who use ultrasonic tips in everyday practice.

Ultrasonic and sonic instruments became available commercially from early 1990s by several clinicians^{3,6)}. These instruments have some advantages include: minimum bony reduction, less risk of perforation with parallel retrograde cavity, and time-saving technique^{2,4,12,16)}. Despite its frequent clinical use, not many clinical studies have been done to evaluate the performance in apical surgery. One of the clinical studies for evaluation of ultrasonic root-end preparation was done by Sumi et al.¹⁵⁾. They reported that the success rate of 157 root-end resected teeth was 92.4%. Rubinstein and Kim¹¹⁾ investigated the success rate of SuperEBA retrograde filling and surgical microscope in preparing root end with EIE ultrasonic instruments. At the completion of their study after 14 months, a 96.8% of success rate was reported. Especially there was positive correlation between the healing time and the small osteotomy. von Arx and their colleagues¹⁷⁾ executed clinical preliminary studies using new KaVo retrotips and what they found was the access with new instrument was found to be excellent in 80% of cases.

As we conclude from the data that there were no differences among the leakage level of retrograde fillings prepared with 3 ultrasonic tips, we inferred that their *in vivo* performance will be the same. However, there is no report regarding the clinical ability of KiS tips, therefore, our future research will be focused on determining the quality of the treatment modality for preparation of retrograde cavities

using KiS ultrasonic tips in apical surgery.

References

1. Bondra DL, Hartwell GR, MacPherson MG, Portell FR. Leakage *in vitro* with IRM, high copper amalgam, and EBA cement as retrofilling materials. *J Endodon* 1989;15:157-160.
2. Brent PD, et al. Evaluation of diamond-coated ultrasonic instruments for root-end preparation. *J Endodon* 1999; 25:672-675.
3. Carr GB. Advanced techniques and visual enhancement for endodontic surgery. *Endod Rep* 1992;7:6-9.
4. Chailertvanitkul P, et al. Polymicrobial coronal leakage of super-EBA root-end filling following two methods of root-end preparation. *Int Endo J* 1998; 31:348-352.
5. Dorn SO, Gartner AH. Retrograde filling materials: a retrospective success-failure study of amalgam, EBA, and IRM. *J Endodon* 1990;16:391-393.
6. Fong CD. A sonic instrument for retrograde preparation. *J Endodon* 1993; 19:374-5.
7. Ingle JI. *Endodontics*, 2nd ed. Philadelphia: Lea and Febiger, 1976.
8. King KT, Anderson RW, Pashley DH, Pantera EA. Longitudinal evaluation of the seal of endodontic retrofillings. *J Endodon* 1990;16:307-310.
9. O'Connor RP, et al. Leakage of amalgam and super EBA root-end fillings using two preparation techniques and surgical microscopy. *J Endodon* 1995;21:74-78.
10. Oynick J, Oynick T. A study of a new material for retrograde fillings. *J Endodon* 1978;4:203-206.
11. Rubinstein RA & Kim S. Short-term observation of the results of endodontic surgery with the use of a surgical operation microscope and super-EBA as root-end filling material. *J Endodon* 1999; 25:43-48.
12. Saunders WP, et al. Ultrasonic root-end preparation part 2. Microleakage of EBA root-end fillings. *Int Endo J* 1994; 27:325-329.
13. Sjogren U, Hagglund B, Sundqvist G, Wing K. Factors affecting the long-term results of endodontic treatment. *J Endodon* 1990;16:498-504.
14. Swartz DB, Skidmore AE, Griffin JA. Twenty years of endodontic success and failure. *J Endodon* 1983; 9:198-202.
15. Sumi Y, et al. Ultrasonic root-end preparation: clinical and radiographic evaluation of results. *JOMS* 1996; 54:590-593.
16. Vertucci FJ & Beatty RG. Apical leakage associated with retrofilling techniques: a dye study. *J Endodon* 1986;12:331-336.
17. von Arx T, Kurt B, Ilgenstein B, Hardt N. Preliminary results and analysis of a new set of sonic instruments for root-end cavity preparation. *Int Endo J* 1998; 31:32-38.

사진부도 설명

- Fig. 3. Retrograde cavity preparation with KaVo SONICflex retro Isthmus ultrasonic tip.
- Fig. 4. Retrograde cavity preparation with KaVo SONICflex retro T-shape ultrasonic tip.
- Fig. 5. Retrograde cavity preparation with ObturaSpartan KiS ultrasonic tip.
- Fig. 6. Dye leakage model for this experiment.
- Fig. 7. Linear leakage measured in the retrograde cavity prepared with KaVo Isthmus tip.
- Fig. 8. Linear leakage measured in the retrograde cavity prepared with KaVo T-shape tip.
- Fig. 9. Linear leakage measured in the retrograde cavity prepared with KiS tip.
- Fig. 10. High magnification view of both KaVo ultrasonic tips.
- Fig. 11. Shematic illustration of KaVo T-shape preparation.
- Fig. 12. Radiographic view of SuperEBA filling after KaVo T-shape preparation.
- Fig. 13. Six different configurations of KiS tips.
- Fig. 14. Irrigation port placed at the front of the tip for better efficiency.

사진부도 ①




Fig. 3.

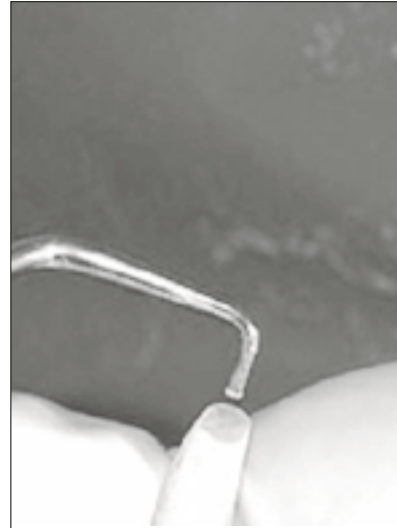


Fig. 4.



Fig. 5.



Fig. 6.




Fig. 7.




Fig. 8.

사진부도 ②

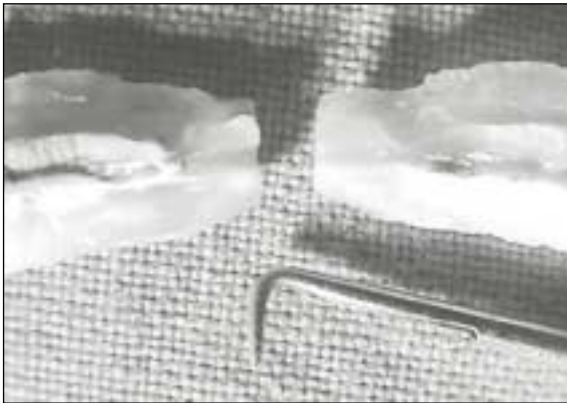

Fig. 9.




Fig. 10.

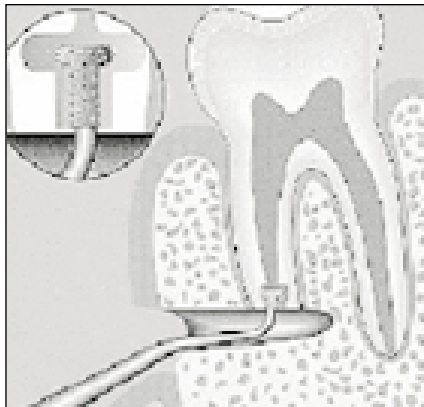


Fig. 11.

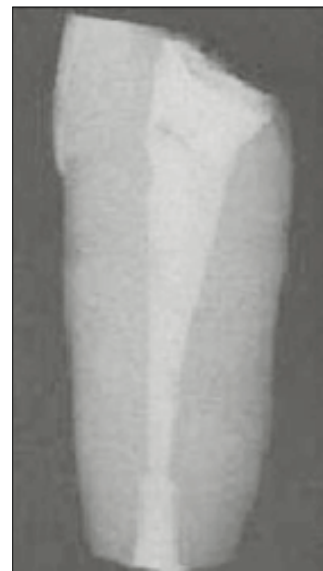

Fig. 12.




Fig. 13.

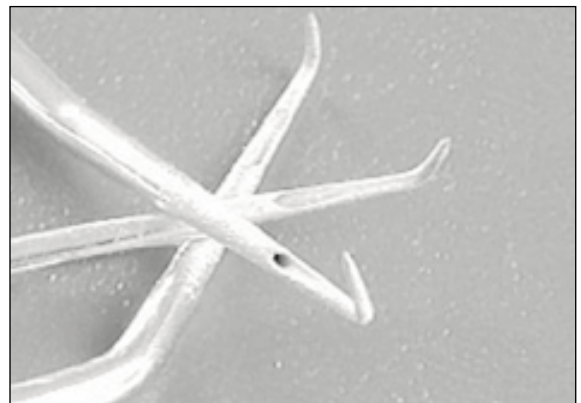


Fig. 14.