

## Interleukin-6 and Interleukin-10 in experimentally induced rat Pulpal inflammation

Seok-Woo Chang, D.D.S., Seung-Ho Baek, D.D.S., M.S.D., Ph.D.,  
Chul-Ho-Kim, D.D.S., M.S.D., Ph.D., Sung-Sam Lim, D.D.S., M.S.D., Ph.D.

Department of conservative dentistry, College of dentistry, Seoul National University

### 국문초록

### 실험적으로 유도된 백서의 치수염에서의 INTERLEUKIN-6와 INTERLEUKIN-10의 농도와 분포에 관한 연구

장석우 · 백승호 · 김철호 · 임성삼

서울대학교 치과대학 치과보존학교실

#### 연구목적

Cytokine은 유해 미생물에 대한 숙주의 방어기전으로서의 염증반응에서 숙주세포 상호간의 작용을 매개해 주는 역할을 하며, 인간의 치수조직에서도 그 존재가 확인된 바 있다. Interleukin-6와 Interleukin-10은 염증의 초기에 작용하는 cytokine으로 알려져 있으나, 치수 및 치근단 질환에서의 역할과 상호작용에 대해서는 잘 알려져 있지 않다. 본 연구에서는 치수염의 원인균으로 알려진 *Prevotella nigrescens*를 이용하여 백서의 치수염을 유도한 후 시간의 변화에 따른 Interleukin-6, Interleukin-10의 농도의 변화를 측정하여 이들의 치수염에서의 작용을 알아보는 것을 목적으로 한다.

#### 방 법

실험적으로 치수의 염증반응을 일으키기 위하여 치수염의 원인균으로 알려진 *Prevotella nigrescens*를 이용하였다. 실험동물의 하악절치의 incisal tip부분을 절단한 후(n=120), 치수강을 개방시켰다. 실험군에서는 *Prevotella nigrescens*를 멸균된 면구에 묻혀서 개방된 치수강 내에 접종하였으며, 대조군에서는 균을 접종하지 않고 멸균된 면구만을 개방된 치수강 내에 위치시켰다. 그 후 1, 2, 5일이 경과되었을 때 실험에 사용된 치아를 발치하여, 치수조직을 적출하였다. Amersham사의 ELISA kit를 사용하여 적출된 치수조직내의 Interleukin-6와 Interleukin-10의 양을 측정하였으며 그 결과를 Mann-Whitney rank sum test를 사용하여 통계학적 유의성을 검증하였다. 조직학적 검사를 위해서는 발치된 치아를 nitric acid를 사용하여 탈회시킨 후 헤마톡실린-에오신 염색을 시행한 후 관찰하였다.

#### 결 과

- 1) Interleukin-6의 농도는 군접종 후 1일, 2일, 5일 모두에서 실험군에서 대조군보다 높게 나타났으며, 군접종 1일째의 결과는 통계적 유의성이 있었다(P<0.05).
- 2) Interleukin-10의 농도는 군접종 후 1일, 2일, 5일 모두에서 실험군에서 대조군보다 높게 나타났으며, 군접종 1일째의 결과는 통계적 유의성이 있었다(P<0.05).
- 3) Interleukin-10/Interleukin-6 ratio는 실험군과 대조군 모두에서 1일보다 2일째의 결과에서 더 높은 값을 보였으며 대조군에서는 통계적 유의성을 보였다(P<0.05).
- 4) 조직학적 관찰결과 군접종 후 2일째의 조직표본에서는 림프구의 침윤과 부분적인 조직의 괴사 등 염증반응의 양상을 관찰할 수 있었으며, 군접종 5일째의 조직표본에서는 염증의 정도가 감소되는 양상을 확인할 수 있었다.

## I . Introduction

Dental pulp and periradicular tissues react to bacterial infections by recruiting a variety of immunocompetent cells to the dental pulp and periradicular tissues. Pulp studies have shown the presence of immunocompetent cells and cells that recognize foreign antigens<sup>1)</sup>. As a result of the interaction of microorganisms and their by-products, various mediators of inflammation, such as neuropeptides, vasoactive amines, kinins, complement component, and arachidonic acid metabolites, are released<sup>2)</sup>.

It was shown that cytokines play important roles and regulate the intensity and duration of the immune response against potentially pathogenic agents. The occurrence of interleukin(IL)-1 and IL-1 producing cells has been demonstrated in human inflamed pulps<sup>3)</sup>. The roles of IL-2 and IL-6 have also been studied in healthy and inflamed dental pulps<sup>4,5)</sup>.

In one study on periodontal disease, the amount of IL-6 and IL-10 were significantly higher in the inflamed gingival tissues than in the peripheral blood from the healthy subjects<sup>6)</sup>. IL-6 was detected in human pulps, periapical lesions<sup>5)</sup> and odontogenic cysts<sup>7)</sup>. And it has been shown that the production of IL-6 was stimulated by *Prevotella intermedia* lipopolysaccharide<sup>8)</sup>.

Interleukin-6 is produced by mononuclear phagocytes, vascular endothelial cells, fibroblasts, and other cells in response to IL-1 and TNF<sup>9)</sup>. One of the best described actions of IL-6 is on B lymphocytes. IL-6 serves as a growth factor for activated B lymphocytes late in the sequence of B cell differentiation. Activated B lymphocytes differentiate into plasma cells and produce antibody against antigens or infective microorganisms. IL-6 may serve as a cofactor of T lymphocytes and thymocytes activation. Activated T lymphocytes can produce cytokines including IL-10 that mediate inflammatory reactions. IL-6 also acts as a cofactor with other cytokines for the growth of early bone marrow hematopoietic stem cells.<sup>9)</sup> In previous studies of pulpal and periapical pathology, IL-6 is known to be one of pro-inflammatory cytokines<sup>10,11)</sup>.

Interleukin-10 is produced by the TH2 subset of CD4+ helper cells<sup>9,12)</sup>.

One of the major activities of IL-10 is to inhibit

cytokine ( i.e.. TNF $\alpha$ , IL-1, chemokine, and IL-12) production by macrophages. It inhibits the production of IFN- $\gamma$  which contribute to pathologic bone resorption in periapical lesion<sup>13)</sup>. And It also suppresses the production of IL-6 by T-lymphocytes<sup>14)</sup>. The effect of these actions is to inhibit T cell-mediated immune response. In addition to its inhibitory effects on macrophages, IL-10 has stimulatory actions on B lymphocytes.

Kakehashi et al. have shown that pathogenesis of pulpal and periapical lesion is closely related to microorganisms<sup>15)</sup>. In their study, dental pulps of conventional and germ-free rats were exposed to their own flora. Pulpal and periradicular lesions developed in conventional rats but failed to develop in germ-free rats.

Bae et al. have shown that the most commonly isolated bacteria from infections of endodontic origin are *Prevotella nigrescens*<sup>16)</sup>.

The purpose of this study was to determine IL-6 and IL-10 in rat pulpal inflammation experimentally induced by specific gram-negative bacteria (*Prevotella nigrescens*) and investigate their roles in the progress of pulpal inflammation.

## II . Materials and Methods

### 1. Experimental induction of Pulpal inflammation

To induce pulpal inflammation experimentally on mandibular incisors of rats, we used *Prevotella nigrescens*(ATCC 33563) cultured on columbia agar plates supplemented with hemin and menadione at 37°C, 85% N<sub>2</sub>, 10% H<sub>2</sub>, and 5% CO<sub>2</sub> anaerobic chamber.

Thirty adult male wistar rats, each weighing 250~300g were anesthetized intraperitoneally with 60 mg/kg of ketalar (Ketamine hydrochloride, Yuhan Co. Seoul). Sixty teeth were used in this experiment. The tips of lower incisors were cut off at the level of gingival margin to exclude the possibility of occlusal stress affecting the dental pulps. A hole was drilled in dentin with a round bur at 35,000 rpm without coolant to open pulp chambers. Coronal portions of the root canals were enlarged with K-files ranging from #15 to #25.

In *Prevotella nigrescens* groups, tiny sterile cotton pellet soaked with a bacterial colony on the agar plate was inserted into the prepared space in contact with pulp tissues. The cavities were sealed with temporary filling material (Cavition. G.C). In control groups, sterile cotton pellet without bacteria was inserted into the prepared space in contact with pulp tissues.

1, 2 and 5 days after pulpal irritation, mandibular incisors were extracted. Extracted teeth were stored in  $-70^{\circ}\text{C}$  liquid nitrogen tank.

## 2. Preparation of tissue samples and Protein assay

The extracted teeth were removed from the liquid nitrogen tank, and allowed to thaw for 10 minutes. After the teeth were cracked open, pulp tissues were carefully removed from the teeth. Half of the pulp tissue from one tooth was used for detection of IL-6 and the other half was used for IL-10. Pulp tissues were homogenized in buffer(0.1M potassium chloride, 0.02M TRIS; pH=7.6) in glass homogenizer and centrifuged(2000RPM,  $4^{\circ}\text{C}$ , 10min). Supernatants were collected.

The concentrations of protein in tissue sample were measured by protein assay kit.

The concentrations were measured in  $\mu\text{g}/\text{ml}$  tissue sample(BCA protein assay kit, Pierce, USA).

## 3. ELISA

The concentrations of IL-6 and IL-10 were measured using ELISA kits (Amersham Pharmacia Biotech Co. Japan). The concentrations were measured in  $\text{pg}/\text{ml}$  tissue sample.

## 4. Statistical Analysis

Results from ELISA were analyzed using Mann Whitney rank sum test and presented as P values. Values less than .05 were considered to be significant.

## 5. Histological Study

1, 2 and 5 days after pulpal irritation, rat mandibular incisors were extracted and hard tissues were decalcified with 5% nitric acid. The pulp tissues and surrounding hard tissues were longitudinally sectioned and stained by Hematoxylin and Eosin. The specimens were examined under light-microscope( $\times 400$ ).

# III . Results

## 1. ELISA

The mean concentrations of the cytokines were illustrated in table 1. Concentrations of IL-6 ranged

**Table 1.** Mean concentrations of IL-6 and IL-10

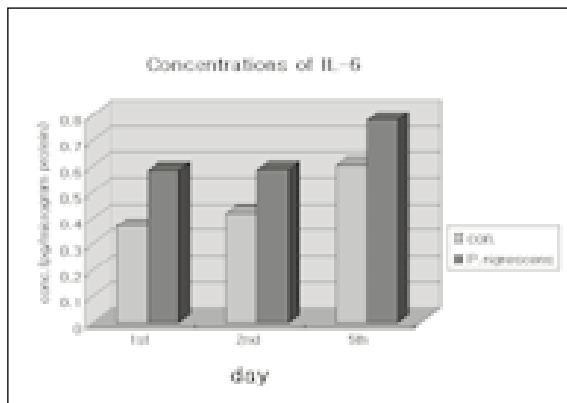
Concentrations		Mean $\pm$ S.D. ( $\text{pg}/\mu\text{g}$ protein)		
		1 st	2 nd	5 th
IL-6	Control (n=27)	$0.368 \pm 0.143$ *	$0.421 \pm 0.183$	$0.605 \pm 0.193$
	P. nigrescens(n=31)	$0.585 \pm 0.240$ *	$0.588 \pm 0.255$	$0.778 \pm 0.321$
IL-10	Control (n=26)	$0.033 \pm 0.012$ †	$0.067 \pm 0.013$	$0.055 \pm 0.027$
	P.nigrescens(n=24)	$0.066 \pm 0.022$ †	$0.072 \pm 0.021$	$0.069 \pm 0.020$

\* : statistically significant difference (  $p < 0.05$  ) between *Prevotella nigrescens* groups and Control groups on the 1st day of pulpal inflammation

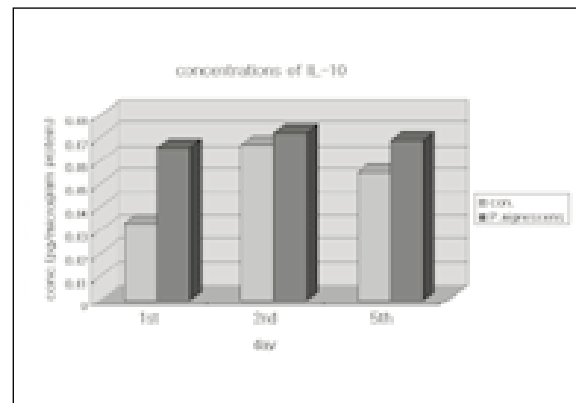
† : statistically significant difference (  $p < 0.05$  ) between *Prevotella nigrescens* groups and Control groups on the 1st day of pulpal inflammation

P.nigrescens : *Prevotella nigrescens* group

S.D. : Standard Deviation



**Fig. 1.** Mean concentrations of IL-6 in *Prevotella nigrescens* group and control group on 1st, 2nd and 5th day of pulpal irritation. Con : Control group  
P.nigrescens : *Prevotella nigrescens* group



**Fig. 2.** Mean concentrations of IL-10 in *Prevotella nigrescens* group and control group on 1st, 2nd, and 5th day of pulpal irritation. Con : Control group  
P.nigrescens : *Prevotella nigrescens* group

**Table 2.** IL-10 to IL-6 ratios

IL-10/IL-6	Mean±S.D	
	1 st (n=16)	2 nd (n=15)
Control	0.093±0.051*	0.174±0.047*
P. nigrescens	0.140±0.054	0.144±0.081

\* : statistically significant difference (  $p < 0.05$  ) between 1st day and 2nd day sample in the control groups.

P.nigrescens : *Prevotella nigrescens* group

S.D : standard deviation

from 0.585 to 0.778pg/ $\mu$ g protein in *Prevotella nigrescens* group and from 0.368 to 0.605pg/ $\mu$ g protein in the control group. Fig. 1 illustrates the concentrations of IL-6 in *Prevotella nigrescens* groups and control groups.

Concentrations of IL-10 ranged from 0.066 to 0.072 pg/ $\mu$ g protein in *Prevotella nigrescens* groups and from 0.033 to 0.067pg/ $\mu$ g protein in the control groups.

The concentrations of IL-6 and IL-10 in *Prevotella nigrescens* groups were higher than those in control groups on the 1st( $P < 0.05$ ), 2nd and 5th day of pulpal irritation. Fig. 2 illustrates the concentrations of IL-10 in *Prevotella nigrescens* groups and control groups.

The concentrations of interleukin-6 in all samples were higher than those of interleukin-10.

To examine the role of IL-6 and IL-10 in the devel-

opment of pulpal inflammation, IL-10 to IL-6 ratios were calculated on the 1st, 2nd day of pulpal irritation.

IL-10 to IL-6 ratios are shown in table 2.

IL-10 to IL-6 ratios were higher on the 2nd day compared to the 1st day in the control groups ( $P < 0.05$ ) and *Prevotella nigrescens* groups.

## 2. Histological study

The histological study showed signs of chronic inflammatory tissue. The dental pulp tissues irritated by *Prevotella nigrescens* showed intense infiltration of polymorphonuclear leukocytes 2 days after pulpal irritation in *Prevotella nigrescens* group (Fig. 4) and control group (Fig. 3). Pulpal inflammation decreased on the 5th day of pulpal irritation in the *Prevotella nigrescens* group and Control group (Fig. 5, 6).

## IV. Discussion

Pulp tissues in the control groups, irritated by thermal and mechanical stimulus but not exposed to bacteria, were also experimentally inflamed. We inoculated *Prevotella nigrescens* to examine the change of IL-6 and IL-10 production in response to the invading bacteria. The concentrations of IL-6 and IL-10 were higher in *Prevotella nigrescens*

group than those in the control groups on the 1st, 2nd and 5th day of pulpal irritation. These findings may suggest that IL-6 and IL-10 might be involved in developing pulpal inflammation stimulated by specific bacteria. Matsushima et al demonstrated that Gram-negative bacteria, such as *L. casei*, from carious lesions, might be involved in developing pulpitis through the stimulation of IL-6 production<sup>17</sup>.

The results of this study were comparable to the study of Barkhordar's<sup>5</sup>, which examined the level of interleukin-6 in inflamed human dental pulps and periapical lesion. In their study, the inflamed pulpal tissues exhibited significantly higher levels of IL-6 (mean =  $36 \pm 3.9$  pg/mg protein) compared to healthy pulp. (mean =  $0.01 \pm 0.02$  pg/mg protein).

In the study of Nakanishi<sup>18</sup>, differences between normal and inflamed pulp were found in the levels of IL-6 but the difference were not statistically significant.

One investigator<sup>19</sup>, examined the production of various cytokines including IL-6 and IL-10 in murine periapical inflammation. The production of both cytokines increased beginning on day 7 and increased to day 14. This results indicate that a cytokine network is activated in response to bacterial irritation and IL-6 and IL-10 played a role in the progress of periapical pathogenesis.

In this experiment, pulpal inflammation is induced instead of periapical inflammation. Histologic study demonstrated that pulpal inflammation is present on 2nd day and decreased on 5th day.

Another study<sup>20</sup> have shown that expression of IL-6 mRNA was significantly higher in diseased periodontal tissues compared to healthy controls. They also have shown the correlation between extent of tissue damage and bone destruction.

These results were comparable to our study and support the findings that IL-6 and IL-10 were produced and released to have a role in the process of pulpal inflammation.

There are a few studies on the role of IL-6 and IL-10 in pulpal inflammation.

But the the role of IL-6 and IL-10 in the development of pulpal and periapical pathogenesis were not clearly identified.

A study of Opal SM et al., have shown that IL-6 is

one of anti-inflammatory cytokine<sup>21</sup>. On the contrary, in the study of Panichi et al.<sup>10</sup>, IL-6 was known to be one of pro-inflammatory cytokines. IL-10 is known to be anti-inflammatory cytokine that suppresses the production of IL-6.

In one study it was suggested that IL-6 produced by dental pulp cells is involved in the metabolism of extracellular matrix and the destruction of dental pulp tissue<sup>17</sup>. Ishimi et al have shown that IL-6 induces bone resorption both alone and in concert with other bone-resorbing agents<sup>22</sup>. Although Lowik et al have shown that IL-6 may be a mediator in PTH-stimulated osteoclastic bone resorption<sup>23</sup>.

In this study, IL-10 to IL-6 ratio on the 2nd day were higher than that on the 1st day. At the early stage of pulpal inflammation, IL-6 was produced and it stimulated B lymphocyte to produce antibody and activate T lymphocyte to produce their own cytokines including IL-10. And in the advanced stage of pulpal inflammation, IL-10 was produced and inhibited the production of cytokines, including IL-1 and IL-6<sup>13</sup>.

These results suggest that IL-6 have a role in earlier stage than IL-10 in the process of pulpal inflammation. These results may help to understand the complex regulation of T-lymphocyte mediated cytokine production by IL-10.

Further studies are necessary to elucidate the roles of IL-6 and IL-10 in developing irreversible inflammation in the dental pulp.

## V. Conclusion

According to this study, we could summarize as follows:

1. The concentrations of interleukin-6 in *Prevotella nigrescens* groups were higher than those in the control groups on the 1st ( $P < 0.05$ ), 2nd and 5th day of pulpal irritation.
2. The concentrations of interleukin-10 in *Prevotella nigrescens* groups were higher than those in the control groups on the 1st ( $P < 0.05$ ), 2nd and 5th day of pulpal irritation.
3. IL-10 to IL-6 ratio (IL-10/IL-6) were higher on the 2nd day compared to 1st day in the control groups ( $P < 0.05$ ) and *Prevotella nigrescens* groups.

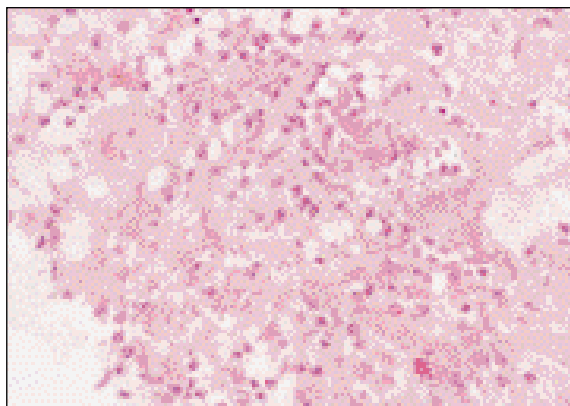
4. The concentrations of IL-6 were higher than IL-10 in all experimental groups and control groups.

These results suggest that *Prevotella nigrescens* may have a role in the progress of pulpal inflammation by stimulating the production of IL-6 and IL-10 and IL-6 may have a role in earlier stage than IL-10 in the development of pulpal inflammation.

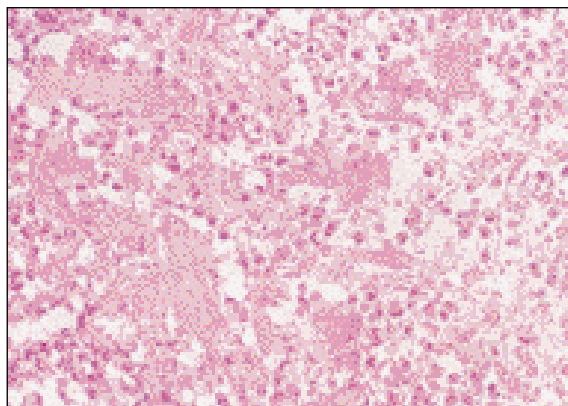
## References

1. Jontell M et al : Dendritic cells and macrophages expressing class II antigens in the normal cat incisor pulp. *J Dent Res* 67:1263, 1988.
2. Torabinejad M: Mediators of pulpal and periapical pathosis, *Calif Dent Assoc J* 14:21 1986.
3. D' Souza R, Brown LR, Newland JR, Levy BM, Lachman LB. Detection and characterization of interleukin-1 in human dental pulps. *Arch Oral Biol* 1989;34:307-13.
4. Cootauco C, Rauschenberger C, Bailey J. IL-2 concentrations and histological classifications of dental pulp [Abstract 149]. *J Dent Res* 1994;73:120.
5. Barkhordar RA, Hayashi C, Hussain MZ. Detection of interleukin-6 in human dental pulp and periapical lesions. *Endod Dent Trauma* 1999;15:26-27.
6. Aramaki M, Nagasawa T, Koseki T, Ishikawa I. Presence of activated B-1 cells in chronic inflamed gingival tissue. *J clin Immunol* 1998 Nov;18(6):421-9.
7. Meghji S, Qureshi W, Henderson B, Harris M. The role of endotoxin and cytokines in the pathogenesis of odontogenic cysts. *Arch Oral Biol* 1996 Jun;41(6):523-31.
8. Tokuda M, Sakuta T, Fushuku A, Torii M, Nagaoka S. Regulation of interleukin-6 expression in human dental pulp cell cultures stimulated with *Prevotella intermedia* lipopolysaccharide. *J Endod* 2001 Apr;27(4):273-277.
9. Abbas AK, cellular and molecular immunology. 2nd Edition. W.B. Saunders. 1994. p250.
10. Panichi V, Migliori M, De Pietro S, Taccola D, Andreini B, Metelli MR, Giovannini L, Palla R. The link of biocompatibility to cytokine production. *Kidney Int* 2000 Aug;58 Suppl 76:S96-103.
11. Cohen S, Pathways of the pulp. 1998, Mosby. P463, 469.
12. Lakkis FG, Baddoura FK, Cruet EN, Parekh KR, Fukunaga M, Munger KA. Anti-inflammatory lymphokine mRNA expression in antibody-induced glomerulonephritis. *Kidney int* 1996 Jan: 4991, 117-26.
13. Roitt I. Immunology 5th edi. 1998. Mosby international. p122.
14. Hempel L, Korholz D, Bonig H, Schneider M, Klein-Vehne A, Packeisen J, Mauz-Korholz C, Burdach S. Interleukin-10 directly inhibits the interleukin-6 production in T-cells. *Scand J Immunol* 1995 May;41(5):462-6.
15. Kakehashi S, Stanley HR, Fitzgerald RJ. The effects of surgical exposures of dental pulps in germfree and conventional laboratory rats. *J South Calif Dent Assoc*. 1966 Sep;34(9):449-51.
16. Bae KS, Baumgartner JC, Shearer TR, David LL. Occurrence of *Prevotella nigrescens* and *Prevotella intermedia* in Infections of endodontic Origin. *J Endod* 1997 oct: 23(10):620-623.
17. Matsushima K, Ohbayashi E, Takeuchi H, Hosoya S, Abiko Y, Yamazaki M. Stimulation of interleukin-6 production in human dental pulp cells by peptidoglycans from *Lactobacillus casei*. *J Endod*. 1998 Apr: 24(4):252-5.
18. Nakanishi T, Matsuo T, Ebisu S Quantitative analysis of immunoglobulins and inflammatory factors in human pulpal blood from exposed pulps. *J Endod* 1995 Mar: 21(3):131-6.
19. Kawashima N, Stashenko P. Expression of bone-resorptive and regulatory cytokines in murine periapical inflammation. *Archives of oral biology*. 44(1999), 55-66.
20. Prabhu A, Michalowicz BS, Mathur A. Detection of local and systemic cytokines in adult periodontitis. *J Periodontol* 1996 May;67(5):515-22.
21. Opal SM, De Palo VA, Anti-inflammatory cytokines. *Chest*. 2000 Apr;117(4):932-4.
22. Ishimi Y, Miyaura C, Jin CH, Akatsu T, Abe E, Nakamura Y, Yamaguchi A, Yoshiki S, Matsuda T, Hirano T Ishimi et al., IL-6 is produced by osteoblast and induces bone resorption. *J of Immunology*, 145, 3297-3303, 1990.

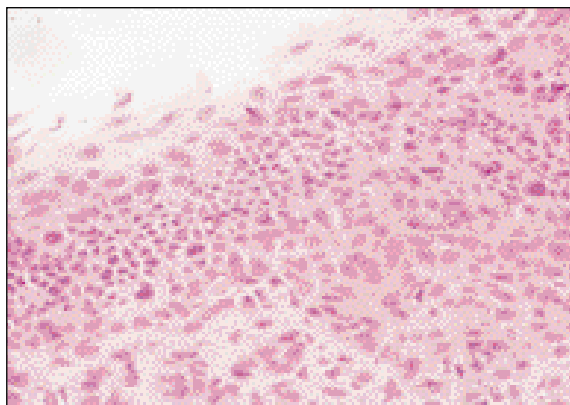
## Explanation of Figures



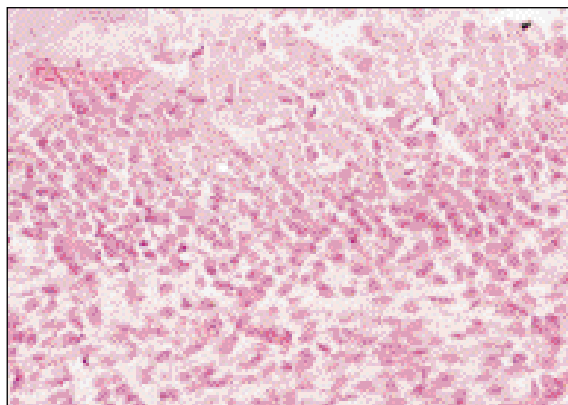
**Fig. 3.** Pulp tissues 2 days after Pulpal irritation, Control group ( H & E, x 400)



**Fig. 4.** Pulp tissues 2 days after Pulpal irritation, *Prevotella nigrescens* group ( H & E, x 400)



**Fig. 5.** Pulp tissues 5 days after Pulpal irritation, Control group ( H & E, x 400)



**Fig. 6.** Pulp tissues 5 days after Pulpal irritation, *Prevotella nigrescens* group ( H & E, x 400)