



A Case of Pranlukast-Induced Anaphylactic Shock

Sujeong Kim, Jong-Myung Lee*

Department of Internal Medicine, Kyungpook National University School of Medicine, Daegu, Korea

This is an Open Access article distributed under the terms of the Creative Commons Attribution Non-Commercial License (<http://creativecommons.org/licenses/by-nc/3.0/>) which permits unrestricted non-commercial use, distribution, and reproduction in any medium, provided the original work is properly cited.

Leukotriene receptor antagonists, which are generally considered safe with a few adverse drug reactions, are increasingly used in the treatment of various allergic diseases, including asthma and allergic rhinitis. Although a few anaphylactic reactions to montelukast have been reported worldwide, there is still a lack of reports about severe adverse drug reactions associated with pranlukast. Here, we report a case of severe hypersensitivity reaction associated with pranlukast. A 65-year-old woman developed anaphylactic shock that presented as generalized urticaria, angioedema, collapse, and loss of consciousness after receiving pranlukast. A positive response to oral challenge and skin prick testing with pranlukast was observed in the patient. In this case, it was demonstrated that pranlukast can induce anaphylaxis, possibly mediated by the IgE-dependent pathway.

Key Words: Pranlukast; leukotriene antagonists; anaphylaxis

INTRODUCTION

Leukotriene receptor antagonists (LTRAs) selectively block the binding of cysteinyl leukotrienes, which play a key role in the pathogenesis of various types of acute and chronic inflammatory disorders, to their receptors on target cells. LTRAs, such as montelukast, pranlukast, and zafirlukast, are mainly used for the treatment of asthma and allergic rhinitis. Their therapeutic applications have recently been extended to diverse diseases, including bronchiolitis, chronic obstructive pulmonary disease, chronic urticaria, atopic dermatitis, and cardiovascular diseases.¹⁻³

Generally, LTRAs are known to be safe and well-tolerable drugs with a few serious adverse reactions.⁴ However, type I hypersensitivity reactions presenting as urticaria, angioedema, and anaphylaxis have rarely been reported with montelukast.⁵⁻⁸ Pranlukast is the first LTRA to be developed and widely used in Japan.⁹ No clinically significant differences in adverse event profiles have been observed among pranlukast, zafirlukast, and montelukast. However, there has been insufficient evidence about pranlukast-induced anaphylactic reaction and cross-reactivity among LTRAs.¹⁰

Here, we report a patient who presented with anaphylactic shock after receiving pranlukast, which was confirmed by an oral challenge test. Skin prick tests with pranlukast and other LTRAs implied the possibility of IgE-mediated reaction and cross-reactivity with montelukast.

CASE REPORT

A 65-year-old woman was referred to our allergy clinic with a history suggestive of drug allergy. Approximately 4 months ago, she visited a private clinic because of a dry cough that lasted for a week. She was prescribed drugs, including pseudoephedrine, mefenamic acid, rebamipide, and teprenone. She discontinued her medications because she felt dizzy within 1 hour after receiving them. A few days later, she visited her daughter living in Japan and was prescribed new medications for her cough, including acetaminophen, pranlukast, procaterol, and metoclopramide. Approximately 3 hours after receiving these medications, she developed generalized urticaria with pruritus and lightheadedness, followed by loss of consciousness for a short time. Her systolic blood pressure decreased to approximately 40 mmHg; however, she recovered soon after emergency treatment at a local hospital. The patient had a 10-year history of mild intermittent allergic rhinitis, for which she did not take any medication. She underwent pituitary surgery for acromegaly 2 years ago and was on rosuvastatin for dyslipidemia for 2

Correspondence to: Jong-Myung Lee, MD, PhD, Department of Internal Medicine, Kyungpook National University School of Medicine, 130 Dongdeok-ro, Jung-gu, Daegu 41944, Korea.

Tel: +82-53-200-5505; Fax: +82-53-426-2046; E-mail: jomlee@knu.ac.kr

Received: June 13, 2015; Accepted: July 16, 2015

- This research was supported by Kyungpook National University Research Fund, 2012 and a grant from Ministry of Food and Drug Safety to operation of the regional pharmacovigilance center in 2015.
- There are no financial or other issues that might lead to conflict of interest.

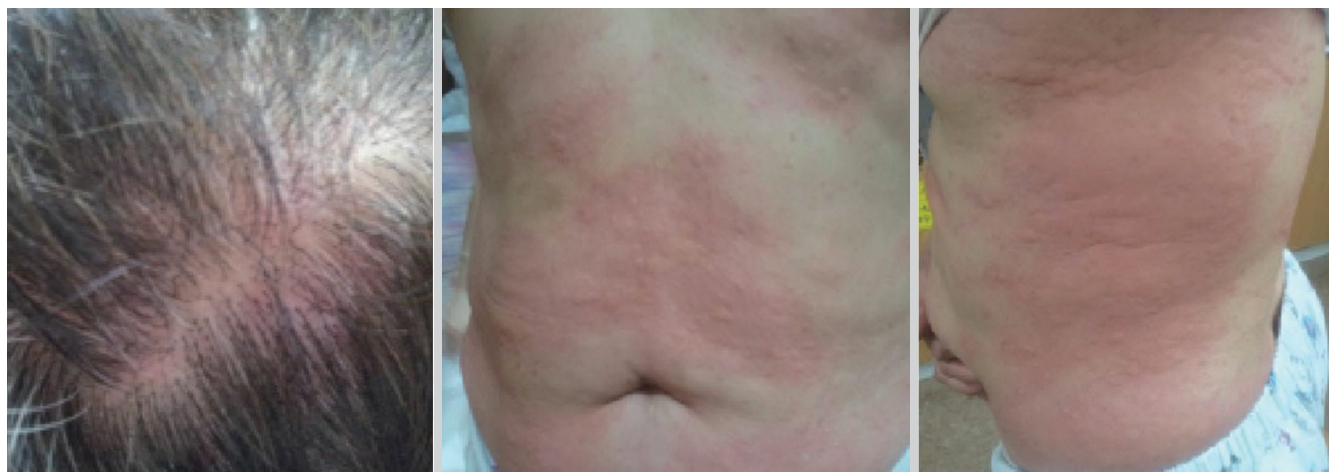

Fig. 1. Variable-sized hives involving the scalp and trunk.

years thereafter.

She was admitted to determine the exact medication that caused the anaphylactic reaction. On the first day of admission, oral challenge with acetaminophen was performed (300, 600, and 900 mg; doses were increased at 1-hour intervals), and there were no adverse reactions. On the second day, a negative response was also observed for the oral challenge test with procaterol (12.5, 25, and 50 mg at 1-hour intervals). The patient underwent an oral challenge test with pranlukast on the next day, and the first dose (56.25 mg) did not cause any reaction. After administration of the second dose (112.5 mg) of pranlukast, the patient complained that she felt hot. Two hours following the first dose of challenge, erythematous macules with itchiness developed on her scalp area. Thereafter, hives of variable sizes appeared on the abdomen and left flank, and spread gradually over the entire body (Fig. 1). She was intravenously treated with chlorpheniramine maleate (4 mg) and dexamethasone (5 mg). However, she experienced symptoms, such as dizziness, nausea, and weakness, within half an hour, with a blood pressure of 53/43 mmHg and a heart rate of 88 beats per minute. Intramuscular injection of epinephrine (0.5 mL of 1:1,000 epinephrine solution) was administered immediately, and she felt better, with the restoration of her blood pressure to 146/76 mmHg within 20 minutes. When the medication history of the patient was rechecked, she stated that this episode occurred following the first exposure to pranlukast, and a history of previous exposure to montelukast was unclear.

Four weeks after discharge, she underwent skin prick tests with pranlukast, montelukast, and zafirlukast to ascertain the mechanism underlying the pranlukast-induced reaction and cross-reactivity among LTRAs using the concentrations 1:1,000, 1:100, and 1:10 of pranlukast 11.25 mg/mL, montelukast 1 mg/mL, and zafirlukast 2 mg/mL, respectively. A positive skin test was defined as a wheal ≥ 3 mm in diameter, with surrounding flare that develops 20 minutes after skin testing. The patient re-

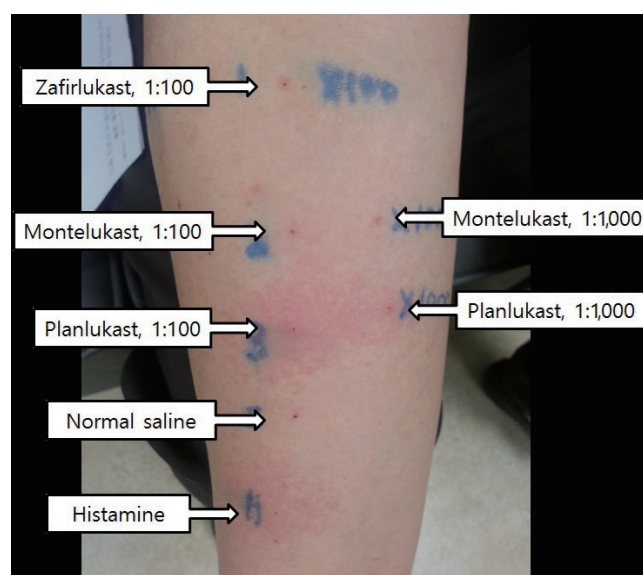


Fig. 2. The results of skin prick testing with pranlukast, montelukast, and zafirlukast.

vealed positive responses to 1:1,000 (wheal, 3×3 mm; flare, 10×10 mm) and 1:100 dilutions (wheal, 5×4 mm; flare, 30×25 mm) of pranlukast and 1:100 dilution (wheal, 3×3 mm; flare, 5×5 mm) of montelukast, but negative response to zafirlukast (Fig. 2). However, no positive reactions developed to 1:1,000, 1:100, and 1:10 dilutions of each LTRA in 4 healthy volunteers and 1 montelukast-tolerable asthmatic patient.

DISCUSSION

It is known that LTRAs have an excellent safety profile. Only a few patients have experienced adverse events during clinical trials with pranlukast, which were mostly non-serious gastrointestinal complications, such as nausea and diarrhea, or liver

function abnormalities.^{9,11} We could find only 2 cases suggestive of pranlukast-induced immediate-type hypersensitivity reactions in the literature.¹² Interestingly, both patients were diagnosed with aspirin-induced urticaria (AIU) and pranlukast-induced generalized urticaria, accompanied by angioedema and severe dizziness in 1 patient, within 1 hour after ingestion. This was contrary to the expectation that LTRAs may prevent the attacks in AIU. The authors assumed that signaling through leukotriene receptors by pranlukast might provoke the responses resembling immediate-type hypersensitivity in AIU patients.¹² In addition, there have been few reports of anaphylaxis cases related to montelukast.⁸ An asthmatic patient with type I hypersensitivity to montelukast was treated effectively by protracted oral desensitization.⁷ However, skin prick testing with LTRAs has not been previously attempted. Moreover, cross-reactivity among LTRAs is not currently known.

Using oral challenge with pranlukast, we confirmed that the drug was causally related with the anaphylactic reaction. We performed skin prick testing with 3 types of LTRAs to ascertain the mechanism underlying the anaphylactic reaction and the cross-reactivity among them. The patient and the control subjects were tested with sequentially increasing concentrations of each LTRA in this study because the concentrations of LTRAs for skin testing were not standardized. The positive result to pranlukast in this case suggested that the systemic reaction, induced by the drug, occurred in an IgE-dependent manner. In contrast to the negative reaction in the montelukast-tolerable asthmatic patient and healthy volunteers, a positive result at 1:100 dilution of montelukast in our patient implied the possible cross-reactivity between pranlukast and montelukast. However, we could not perform oral challenge with montelukast.

In conclusion, pranlukast could cause severe anaphylactic reactions with possible cross-reactivity with montelukast, and skin prick testing with LTRAs could be used as a helpful diag-

nostic tool in anaphylaxis to LTRAs.

REFERENCES

1. Riccioni G, Bucciarelli T, Mancini B, Di Ilio C, D'Orazio N. Antileukotriene drugs: clinical application, effectiveness and safety. *Curr Med Chem* 2007;14:1966-77.
2. Funk CD. Leukotriene modifiers as potential therapeutics for cardiovascular disease. *Nat Rev Drug Discov* 2005;4:664-72.
3. Kanaoka Y, Boyce JA. Cysteinyl leukotrienes and their receptors; emerging concepts. *Allergy Asthma Immunol Res* 2014;6:288-95.
4. García-Marcos L, Schuster A, Pérez-Yarza EG. Benefit-risk assessment of antileukotrienes in the management of asthma. *Drug Saf* 2003;26:483-518.
5. Calapai G, Casciaro M, Miroddi M, Calapai F, Navarra M, Gangemi S. Montelukast-induced adverse drug reactions: a review of case reports in the literature. *Pharmacology* 2014;94:60-70.
6. Minciullo PL, Saija A, Bonanno D, Ferlazzo E, Gangemi S. Montelukast-induced generalized urticaria. *Ann Pharmacother* 2004;38:999-1001.
7. Tayeb MM. Allergy to montelukast sodium treated effectively by protracted oral desensitization: first case report. *Glob Adv Res J Med Med Sci* 2013;2:120-4.
8. Gerard A, Harkisoon S. Singulair-induced anaphylaxis? *J Fam Pract* 2009;58:133-4.
9. Barnes NC, de Jong B, Miyamoto T. Worldwide clinical experience with the first marketed leukotriene receptor antagonist. *Chest* 1997;111:52S-60S.
10. Keam SJ, Lyseng-Williamson KA, Goa KL. Pranlukast: a review of its use in the management of asthma. *Drugs* 2003;63:991-1019.
11. The Japan Pharmaceutical Manufacturers Association. Japan Pharmaceutical Reference: Onon® Capsules 112.5 mg [Internet]. Tokyo: The Japan Pharmaceutical Manufacturers Association; 2010 [cited 2015 Jun 5]. Available from <http://www.e-search.ne.jp/~jpr/PDF/ONO04.PDF>.
12. Ohnishi-Inoue Y, Mitsuya K, Horio T. Aspirin-sensitive urticaria: provocation with a leukotriene receptor antagonist. *Br J Dermatol* 1998;138:483-5.