

# Huge Turret Exostosis of Metacarpus: A Case Report

Shin Taek Kang, Tae Hyung Kim, and Hyun Woo Kim\*

*Department of Orthopedic Surgery, Cheongju St. Mary's Hospital, Cheongju, \*Department of Orthopedic Surgery, The Catholic University of Korea College of Medicine, Seoul, Korea*

A turret exostosis was known a smooth, dome-shaped extracortical collection of subperiosteal bone beneath the extensor apparatus. In most cases, turret exostosis involve middle and distal phalanges compared with involving metacarpal cases have been rarely reported in the literature.

**Key words:** metacarpus, turret exostosis

A turret exostosis was first described by Wissinger et al.<sup>1)</sup> in 1966. A rare complication after trivial injuries to the dorsum of the proximal and middle phalanges of the fingers. As the lesion enlarges, the patient complains pain and a palpable mass, which may cause disruption in the extensor mechanism, resulting in the loss of finger flexion.<sup>2)</sup>

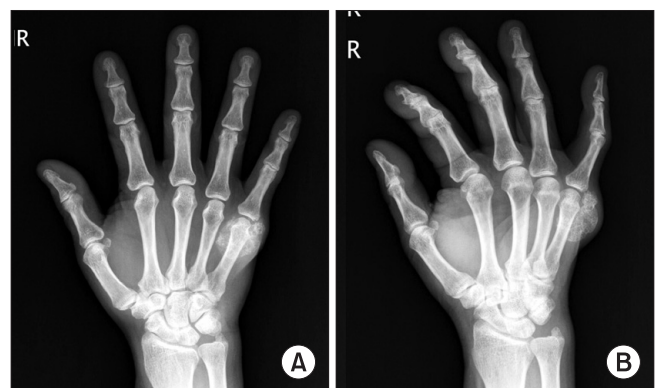
Almost all turret exostosis that reported involve middle and distal phalanx, but we experienced a peculiar turret exostosis involve metacarpus.

## Case Report

A seventy-five-year-old man presented with a palpable mass without pain of the right hand, which had been gradually enlarging over a ten-year period. On physical examination, a 3×3-cm non-tender mass was observed on the dorsoulnar aspect of the fifth metacarpal area. The mass was round shaped with irregular surface, firm and fixed with negative Tinel's sign. Flexion of the ring finger was limited. The initial hand radiographs demonstrated a large soft tissue mass with ossification from the fifth metacarpophalangeal (MCP) joint to mid-shaft of the fifth metacarpal bone (Fig. 1). A whole body bone scan revealed that the patient had an active heterotopic ossification lesion (Fig. 2A). We applied outpatient follow-up and

symptomatic treatment and observed progress. In plain radiography after 6 months, the size of the mass had not been changed, and whole body bone scan showed a decrease in contrast enhancement by over 50% compared to that in the previous scan (Fig. 2B).

The operation started with a skin incision of dorsal aspect and the mass was observed on the MCP joint, neck and shaft of the metacarpal bone. Intraoperative finding demonstrated a sessile type, white colored and round shaped hard mass sized at 3.5×2.5×2-cm. The mass consisted of bone, cartilage cap and capsulated fibrous fascia (Fig. 3). Histopathological finding was consistent with exostosis (Fig. 4). After one week of surgery, the patient had full range of motion of the little finger. At the time of final follow-up one years and six months after the excision, the patient maintained full range of motion of the little finger and the hand radiographs showed no evidence of recurrence of the turret exostosis (Fig. 5, 6).



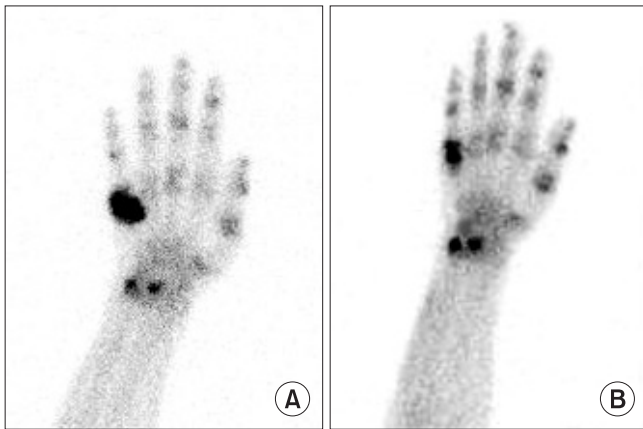
**Figure 1.** (A) Posteroanterior and (B) oblique radiographs of the hand show large soft tissue mass with ossification on the fifth metacarpal head to shaft area, reveal a mature turret exostosis.

**Received** October 22, 2012 **Revised** November 20, 2012 **Accepted** November 22, 2012

**Correspondence to:** Tae Hyung Kim

Department of Orthopedic Surgery, Cheongju St. Mary's Hospital, 589-5, Jujung-dong, Sangdang-gu, Cheongju 360-568, Korea

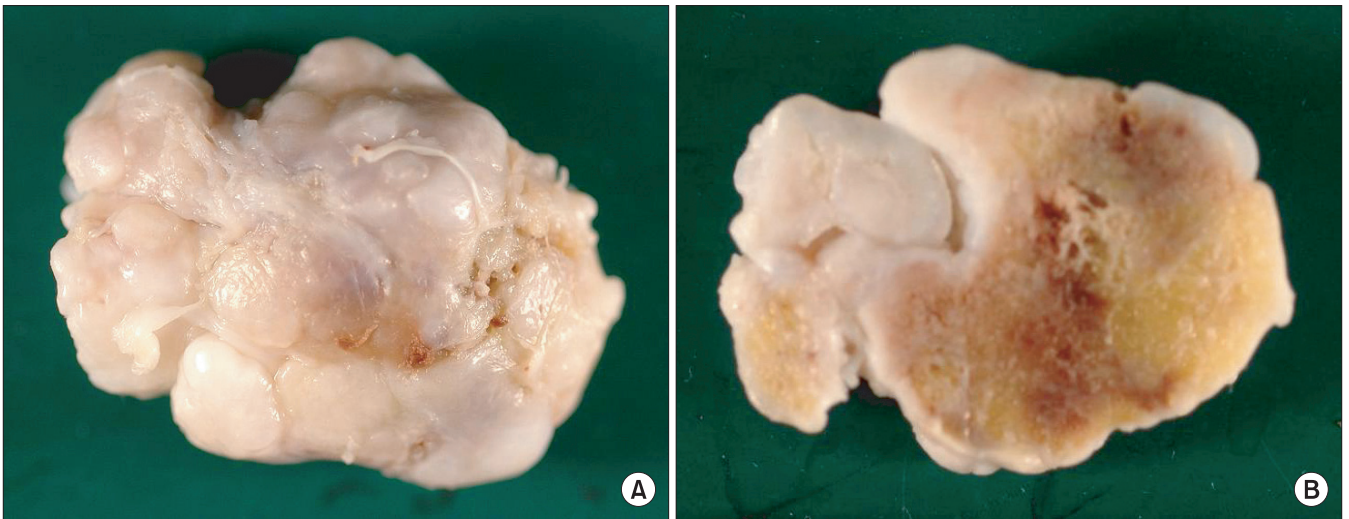
**TEL:** 82-43-219-8140 **FAX:** 82-43-219-8141 **E-mail:** goodoc-k@daum.net



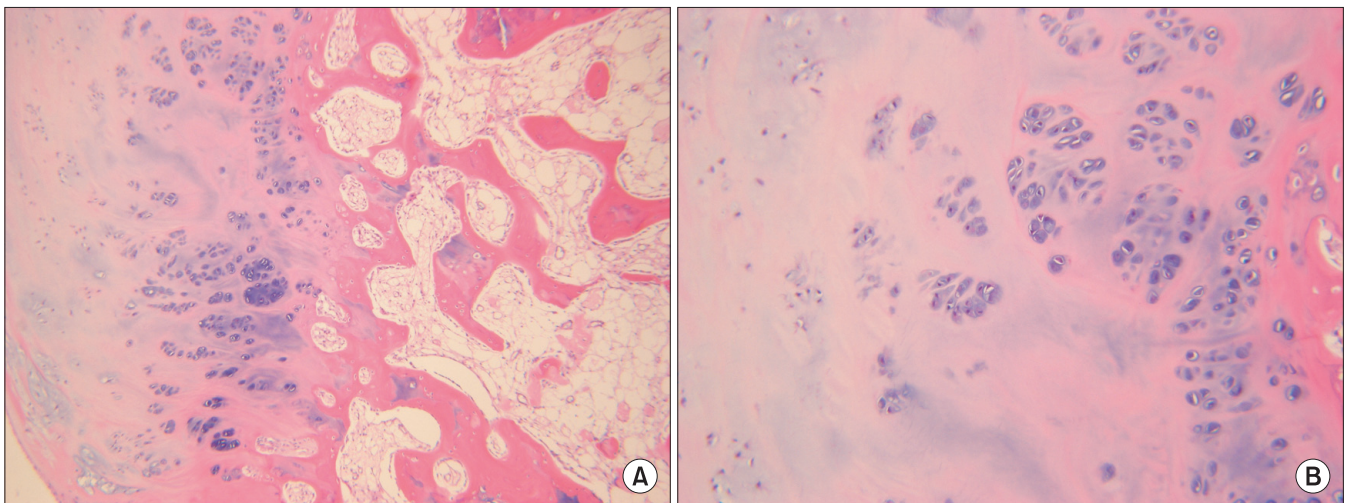
**Figure 2.** (A) Initial bone scan reveals an active heterotopic ossification lesion around the fifth metacarpal area and (B) six months follow up bone scan shows decreased hot uptake lesion of the fifth metacarpal area.

## Discussion

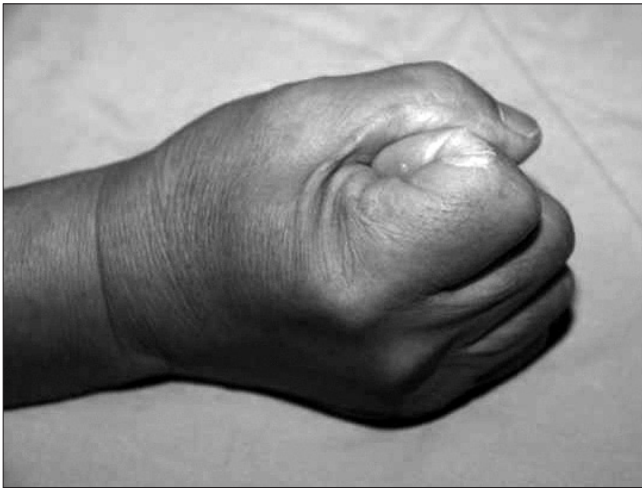A turret exostosis is a rare complication after trivial injuries to the dorsum of the proximal and middle phalanges of the fingers.<sup>1)</sup> The differential diagnosis includes benign lesions, such as osteochondroma, and malignant neoplasms, such as osteosarcoma and osteochondrosarcoma.<sup>2)</sup> Most frequently involved sites are the index and the little finger,<sup>3)</sup> but rarely involve the thumb,<sup>2)</sup> metacarpal,<sup>3)</sup> big toe<sup>3)</sup> and talus.<sup>4)</sup> To our knowledge, a turret exostosis involving the metacarpal has been reported one case in the hand and orthopaedic literature by Rubin et al.<sup>2)</sup> According to that report, the exostosis involving fifth metacarpal had recurred on one-year follow-up clinical and X-ray examination. In our case, turret exostosis of the fifth



**Figure 3.** (A) Excised mass and (B) horizontally cut.



**Figure 4.** Histopathologic examination definitely diagnosed as turret exostosis including mature bone, cartilage and fiber membrane. (A) H&E stain  $\times 100$ . (B)  $\times 200$ .



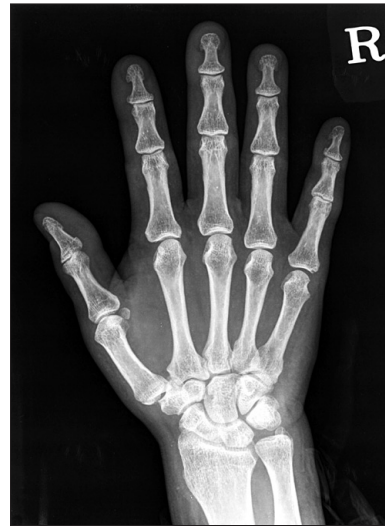**Figure 5.** Gross pictures after one year and six months from surgery demonstrate the fifth interphalangeal joint and the fifth MCP joint are capable of full flexion.

metacarpal, no evidence of recurrence was not found on clinical and X-ray follow-up after a year and six months after the surgery.

The treatment of choice for a turret exostosis is excision appropriately timed to the maturation of the lesion.<sup>3)</sup> Wissinger et al.<sup>1)</sup> recommended that excision should not be performed less than four to six months after the original injury. Premature excision and poor surgical technique may invite recurrence.<sup>1)</sup> At surgery, if sufficient time has elapsed from the original injury, the planes will be clearly defined between the lesion, the overlying periosteum and the underlying cortex.<sup>2)</sup>

We used bone scan study as a modality to set the time of operation for turret exostosis. Our case showed a marked decrease in the bone uptake of the lesion in bone scan performed after 6 months follow-up from the initial bone scan study. So surgical removal was performed and obtained satisfactory results without recurrence.

It seems that there is no established examination protocol so far. In order to set the time of operation, it seems helpful to perform



**Figure 6.** Radiographs of hand after one year and six months from surgery shows no definite evidence of recurrence.

bone scan after an injury on a finger or hand during the early period when a radiologically ectopic bone lesion develops. In general, if bone scan after 6 months from the injury shows the increase of lesion intake by over 50%, we may consider operation.

## References

1. Wissinger HA, McClain EJ, Boyes JH. Turret exostosis. Ossifying hematoma of the phalanges. *J Bone Joint Surg Am.* 1966;48:105-10.
2. Rubin JA, Steinberg DR. Turret exostosis of the metacarpal: a case report. *J Hand Surg Am.* 1996;21:296-8.
3. Kontogeorgakos VA, Lykissas MG, Mavrodontidis AN, et al. Turret exostosis of the hallux. *J Foot Ankle Surg.* 2007;46:130-2.
4. LeClere LE, Riccio AI, Helmers SW, Thompson KE. Turret exostosis of the talus. *Orthopedics.* 2010;33:517.

## 중수골의 거대 뚜렛 외골증: 증례 보고

강신타 • 김태형 • 김현우\*

청주성모병원 정형외과, \*가톨릭대학교 의과대학 정형외과학교실

뚜렛 외골증은 수부의 신전기전 아래 골막하 골이 매끈한 돔 형태로 피질 바깥으로 침착되는 것으로 대부분은 중위지골과 원위지골에 발생하는 것으로 알려져 있다. 이에 반해 거대한 뚜렛 외골증이 중수골에 생긴 매우 드문 증례를 경험하여 이를 보고하고자 한다.

**색인단어:** 중수골, 뚜렛 외골증

접수일 2012년 10월 22일 심사수정일 2012년 11월 20일 게재확정일 2012년 11월 22일

교신저자 김태형

청주시 상당구 주충동 589-5번지, 청주성모병원 정형외과

TEL 043-219-8140, FAX 043-219-8141, E-mail goodoc-k@daum.net