

Acute Compartment Syndrome after Non-Contact Peroneus Longus Muscle Rupture

Jarrad Merriman, MPH, Diego Villacis, MD, Curtis Kephart, MD,
Anthony Yi, BS, Russ Romano, ATC, George F. Rick Hatch III, MD

*Department of Orthopedic Surgery, Shoulder, Elbow and Knee Service, USC Keck Hospital,
University of Southern California Keck School of Medicine, Los Angeles, CA, USA*

This case demonstrates a rare variation in the pattern of injury and the presentation of acute lateral compartment syndrome of the leg. Although uncommon, lateral compartment syndrome of the leg after an ankle inversion leading to peroneus longus muscle rupture has been previously documented. This case was unusual because there was no overt ankle injury and the patient was able to continue physical activity, in spite of a significant rupture of the peroneus longus muscle that was determined later. This case highlights the necessary vigilance clinicians must maintain when assessing non-contact injuries in patients with possible compartment syndrome.

Keywords: *Compartment syndrome, Peroneus longus, Lateral compartment syndrome, Non-contact*

Compartment syndrome represents elevated pressure within a closed fascial space resulting in a decrease in capillary perfusion, which is necessary for tissue viability.¹⁾ In the lower extremities, acute compartment syndrome usually results from a direct trauma. Obvious injuries such as blunt trauma, fractures, and ankle sprains generate an elevated index of suspicion. However, the diagnosis becomes more difficult when the history is atypical, such as when there is an exertional etiology or pain without any distinct trauma. Consideration of this diagnosis in the absence of trauma is critical, as delayed treatment can result in the loss of motor and sensory functions, death of skeletal muscles, subsequent contracture, and even amputation.²⁾

The anterior compartment of the leg is more frequently associated with compartment syndrome; however, isolated involvement of the lateral section is also possible. A known etiology of lateral compartment syndrome is peroneus longus muscle rupture or avulsion, secondary

to a distinct acute rotational ankle injury.^{3,4)} After such injuries, the patient generally ceases activity immediately and presents to the clinician with a clear history of trauma. Although non-traumatic cases of lateral compartment syndrome have also been described, they are quite infrequent.^{5,6)} This article presents a case of non-contact, acute lateral compartment syndrome of the leg secondary to peroneus longus muscle rupture in a collegiate football player who continued athletic competition after sustaining the injury.

CASE REPORT

A 23-year-old male collegiate football player, who experienced a sharp pain in his left leg during practice, presented to an orthopaedic surgeon for evaluation 18 hours after the incident. The athlete was reportedly participating in cutting drills when he experienced a sharp, snapping pain in his left leg just distal to the fibular head. He reported no significant trauma nor was there any twisting or indirect injury. He confirmed working through the pain and continuing the drills. The pain worsened throughout practice, which prompted him to approach the athletic training staff. Ice, a compressive wrap, and nonsteroidal anti-inflammatory drugs (NSAIDs) were administered and the

Received January 26, 2014; Accepted June 10, 2014

Correspondence to: Anthony Yi, BS

Department of Orthopedic Surgery, University of Southern California Keck School of Medicine, 4040 Via Marisol Apt 125, Los Angeles, CA 90042, USA

Tel: +1-253-777-2332, Fax: +1-323-226-4051

E-mail: yi.anthony.m@gmail.com

Copyright © 2015 by The Korean Orthopaedic Association

This is an Open Access article distributed under the terms of the Creative Commons Attribution Non-Commercial License (<http://creativecommons.org/licenses/by-nc/4.0>) which permits unrestricted non-commercial use, distribution, and reproduction in any medium, provided the original work is properly cited.

Clinics in Orthopedic Surgery • pISSN 2005-291X eISSN 2005-4408

patient was advised to go home and elevate the extremity. Due to escalating pain through the night, he was brought to the local emergency department by a team trainer. An ultrasound revealed no evidence of deep venous thrombosis. After being prescribed a narcotic for the pain, he was discharged to go home. However, the pain continued throughout the night and he began having paresthesias in the superficial peroneal nerve distribution of his left foot. The trainer was contacted again the next morning and the patient was immediately brought to the orthopedic operating center for further evaluation.

Past medical and surgical histories of the patient were unremarkable. A review of systems was notable for extreme pain in the left leg, but otherwise negative for any clinical illness. He confirmed taking NSAIDs and the pain medication from the emergency department, but denied intake of any other medications, including supplements.

On examination, the patient appeared to be in significant distress. Visual inspection of his extremity revealed swelling over the lateral compartment, most notably approximately 5 cm distal to the fibular head. There was no ecchymosis or open wound. Palpation revealed a tense and firm lateral compartment. He held his foot in a plantarflexed and inverted position. There was no pain with the passive range of motion of his toes, as well as with passive dorsiflexion and plantarflexion of the ankle. However, he experienced pain with both passive eversion and inversion of his ankle, which he localized to his lateral compartment. The patient had gross numbness on the dorsum of his foot, including the first dorsal web space, which was

consistent with the superficial peroneal and deep peroneal nerve distributions. Sensation remained intact in the lateral, medial, and plantar aspect of his foot. Capillary refill was less than 2 seconds and palpable dorsalis pedis and posterior tibialis pulses were present. X-ray studies showed no evidence of a fracture.

He was immediately taken to the operating room for fasciotomy; this was approximately 19 hours postinjury. The preoperative diastolic blood pressure was measured as 86 mmHg. In the operating room, pressure was measured using a Stryker handheld compartment pressure monitor (Stryker, Mahwah, NJ, USA): the lateral compartment measured 139 mmHg (delta pressure = -53), the anterior compartment measured 89 mmHg (delta pressure = -3), the superficial posterior compartment measured 30 mmHg (delta pressure = 56), and the deep posterior compartment measured 48 mmHg (delta pressure = 38).

The patient underwent fasciotomies involving a release of the anterior and lateral compartments. A linear incision was made midway between the tibial crest and the fibula. The lateral compartment was then released, which exposed a large tear involving the proximal aspect of the peroneus longus muscle belly, which was believed to be the cause of this compartment syndrome (Fig. 1). Approximately 20% to 25% of the peroneal musculature was dark burgundy, friable, and unresponsive to electrocauterization. Nonviable tissue was debrided until bleeding commenced and responsive muscle was obtained (Fig. 2). A significant hematoma, which was present at the exit of the superficial peroneal nerve from the lateral compartment into the ante-

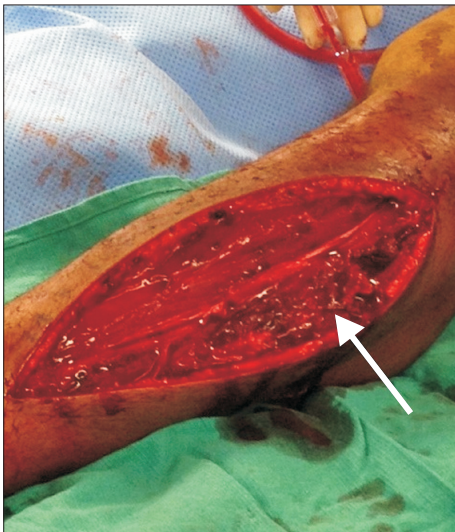


Fig. 1. Intraoperative photograph of the left leg showing the burgundy, torn peroneus longus muscle tissue, as indicated by the white arrow.

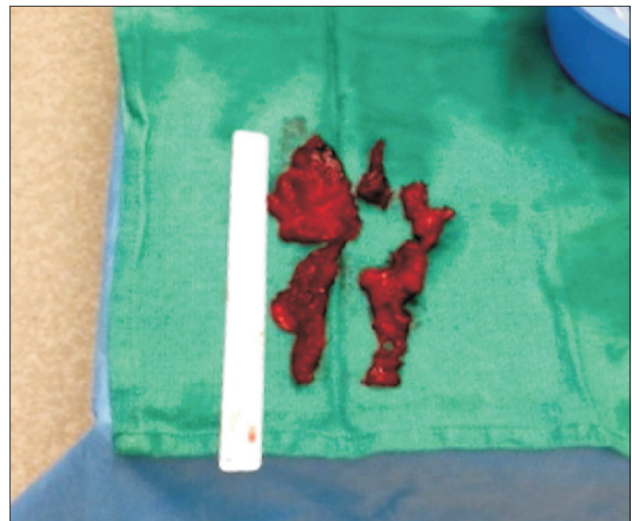

Fig. 2. Intraoperative photograph of the debrided peroneus longus muscle tissue.

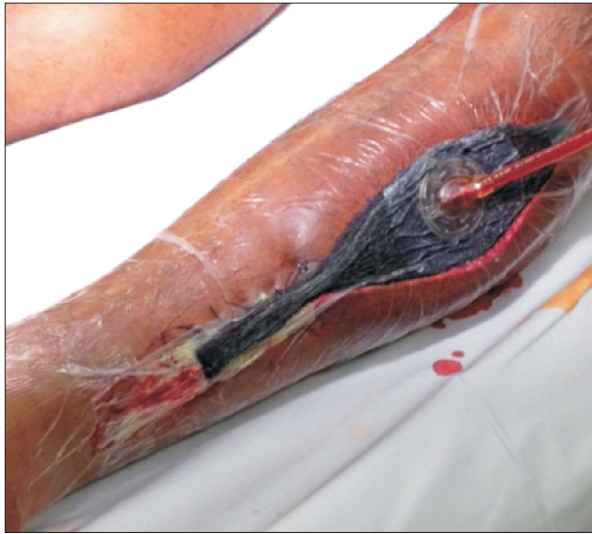

Fig. 3. Postoperative photograph of the left leg demonstrating closure with a vacuum-assisted closure device.

rior compartment, was removed. Next, an incision was made over the anterior compartment; it exposed viable musculature that was reactive to electrocautery; therefore, no debridement was performed. Vertical mattress stitches were used to distally close the skin and cover the peroneal nerve. Proximally, the incision was left open and a KCI V.A.C. Ultra Negative Pressure Wound Therapy System device (San Antonio, TX, USA) was applied with a pressure of 125 mmHg on “continuous” mode (Fig. 3).

Postoperatively, the ipsilateral foot was placed at 90° in a posterior splint to prevent contracture. The initial recovery was unremarkable with immediate improvement in pain. On postoperative day two, the patient was taken back to the operating room for repeat irrigation and debridement, removal of any nonviable muscle tissue, and partial closure of the wound. Minimal debridement was necessary and 75% of the wound was closed while the wound VAC device was applied to the remaining section. On postoperative day five, repeat irrigation, minimal debridement, and final closure of the wound were performed.

Initially, the patient was advised to bear weight as tolerated in a controlled ankle motion boot with eventual transition to crutches by 2 weeks postoperatively. During this time, he worked on ankle range of motion and conditioning using a stationary bike. By 3 weeks postoperatively, sensation had returned to the dorsum of his foot. From postoperative weeks three to eight, he began manual resistance training, and was transitioned to regular shoes. Eight weeks postoperatively, he was pain free with full range of ankle motion. He was cleared for complete athletic partici-

pation at 12 weeks after surgery.

DISCUSSION

Trauma, such as a contusion or crush injury to the soft tissue, is typically responsible for compartment syndrome. However, a variety of other causes have also been described.⁷⁾ Atypical presentations may result in a delay in diagnosis or treatment, thereby increasing the chances of adverse medical-legal ramifications.⁸⁾ Cases without a fracture result in a significantly greater delay in fasciotomy than those with a fracture.⁹⁾ Lower extremity compartment syndrome, isolated to the lateral and/or anterior compartment secondary to musculotendinous injury, have been reported in literature.^{3,4)} In nearly all reported cases, the presentation occurred after a reported ankle inversion injury during participation in a competitive sport.^{3,4,6)} In our patient, the proposed mechanism is an acute muscle tear with resultant hemorrhage, producing elevated pressure within the lateral and anterior compartments. However, comparable to another reported case in literature, our patient suffered this injury during non-contact exercise.⁴⁾ Also, the patient described his pain as originating just below his knee, which contrasts previous reports describing presentations more consistent with an ankle sprain. Despite this discrepancy in presentation, intraoperative findings demonstrated a rupture of the peroneus longus muscle belly and subsequent hematoma. This is consistent with the earlier proposed mechanism for resultant lateral and/or anterior compartment syndrome.

Peroneus longus tears are relatively uncommon injuries, often being the outcome of prolonged stress from persistent ankle instability, peroneal dislocation, or tendonitis.¹⁰⁾ Of note, the patient reported no correlated symptoms prior to injury. In addition, rupture typically occurs at the level of the tendon bone interface.¹⁰⁾ Previous reports of lateral compartment syndrome secondary to peroneus longus muscle rupture all describe tears at the musculotendinous junction.^{3,4)} Our patient suffered a more proximal rupture, which provides a likely explanation for the difference in clinical presentation.

The complications of unrecognized compartment syndrome can be devastating. Having a high index of suspicion and performing serial physical examinations are critical for prompt diagnosis. A patient with acute compartment syndrome rarely presents without a history of trauma. Our case, therefore, highlights a potentially missed diagnosis and lends support for the practice of maintaining a high index of suspicion for lateral compartment syndrome, even after seemingly innocuous injuries.

CONFLICT OF INTEREST

No potential conflict of interest relevant to this article was reported.

REFERENCES

1. Tiwari A, Haq AI, Myint F, Hamilton G. Acute compartment syndromes. *Br J Surg*. 2002;89(4):397-412.
2. Finkelstein JA, Hunter GA, Hu RW. Lower limb compartment syndrome: course after delayed fasciotomy. *J Trauma*. 1996;40(3):342-4.
3. Arciero RA, Shishido NS, Parr TJ. Acute anterolateral compartment syndrome secondary to rupture of the peroneus longus muscle. *Am J Sports Med*. 1984;12(5):366-7.
4. Slabaugh M, Oldham J, Krause J. Acute isolated lateral leg compartment syndrome following a peroneus longus muscle tear. *Orthopedics*. 2008;31(3):272.
5. Ashton LA, Jarman PG, Marel E. Peroneal compartment syndrome of non-traumatic origin: a case report. *J Orthop Surg (Hong Kong)*. 2001;9(2):67-9.
6. Rehman S, Joglekar SB. Acute isolated lateral compartment syndrome of the leg after a noncontact sports injury. *Orthopedics*. 2009;32(7):523.
7. Olson SA, Glasgow RR. Acute compartment syndrome in lower extremity musculoskeletal trauma. *J Am Acad Orthop Surg*. 2005;13(7):436-44.
8. Bhattacharyya T, Vrahas MS. The medical-legal aspects of compartment syndrome. *J Bone Joint Surg Am*. 2004;86(4):864-8.
9. Hope MJ, McQueen MM. Acute compartment syndrome in the absence of fracture. *J Orthop Trauma*. 2004;18(4):220-4.
10. Redfern D, Myerson M. The management of concomitant tears of the peroneus longus and brevis tendons. *Foot Ankle Int*. 2004;25(10):695-707.