

1

.

가

= Abstract =

A Case of Miliary Tuberculosis Associated with Multiple Intracranial Tuberculoma

Sun Yung Park, M.D., Jung Hyun Lee, M.D., Nak Gyun Chung, M.D.
Jin Tack Kim, M.D., Seung Yun Chung, M.D. and Jin Han Kang, M.D.

Department of Pediatrics, College of Medicine, The Catholic University of Korea

The incidence of tuberculosis has been decreased, and especially the incidence of severe complicated tuberculosis has been markedly decreased as the result of widely used BCG vaccines. But tuberculosis is still an important community acquired infectious disease in the world despite continued worldwide efforts to control the disease. Miliary tuberculosis, the most serious complicated tuberculosis, can be occurred by lymphohematogenous dissemination of tuberculosis, and intracranial tuberculoma with or without tuberculosis meningitis can be developed in case of miliary tuberculosis. In general, serious tuberculosis infections such as miliary tuberculosis and CNS tuberculosis are developed especially in young infants and children in cases of delayed diagnosis and treatment despite receiving BCG vaccination, and usually those patients have contact sources. Intracranial tuberculoma in children are usually found near infratentorial site at the base of cerebellum, and clinically symptoms and signs of increased intracranial pressure developed before treatment. Serial brain CT or MRI is a good non-invasive diagnostic modality of intracranial tuberculoma. Although surgical intervention was initially advocated as the mainstay of intracranial tuberculoma therapy, but many recent clinical studies indicate that intracranial tuberculoma can be cured with medical treatment alone. We experienced a case of 3 months old male patient, who was diagnosed as having miliary tuberculosis associated with multiple intracranial tuberculoma. He received BCG vaccination at 4 weeks after birth, and his father was confirmed as active pulmonary tuberculosis patient after this patient's admission. We report this case with a review of related literatures.

Key Words : Intracranial tuberculoma, Miliary tuberculosis

: , 가

Tel : 032)510-5522 Fax : 032)503-9724

E-mail : kjhan@olmh.cuk.ac.kr

가

5 : 1 25 1

BCG

가

가 450,000 100 : 34 3,180g

¹⁾ 가 : 가 6 B

가 10kg 가 1

가 : B

²⁾,

4 BCG
2 DTaP

(intrac-

ranial tuberculoma)

³⁾

: 6.7kg(25 50
, 59cm(10), 41cm(25 50
) 38.1 , 134 /
, 80 /

1.5cm 2cm

가 2

가

가 ⁴⁾

10

, :
3 12.1g/dL, 37.8%, 24,500/
mm³(64%, 30%, 6%),
623,000/mm³ Na 139
mEq/L, K 5.4mEq/L, FBS 94mg/dL, BUN 10.9mg/
dL, Cr 0.6mg/dL, Ca 9.3mg/dL, P 5.5mg/dL, Mg
2.0mg/dL , 10mm/hr, C-

: , 3 , 60.9mg/dL 가
: 10 , pH 7.45, PaCO₂ 42.5mmHg, PaO₂ 51.3mmHg

: 10 180mmH₂O 9mm³

2 7

1 가 ,

(
)
:
(Fig. 1A),
,
(Fig. 2A).
:
4L/
PaO₂ 71 50mmHg
2
, manitol

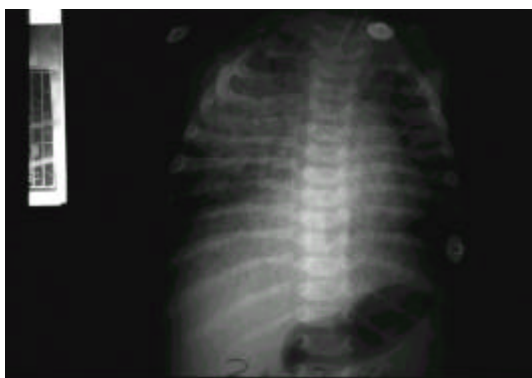

Fig. 1A. Disseminated multiple nodular or confluent opacities like snow flakes were scattered on both lung fields.

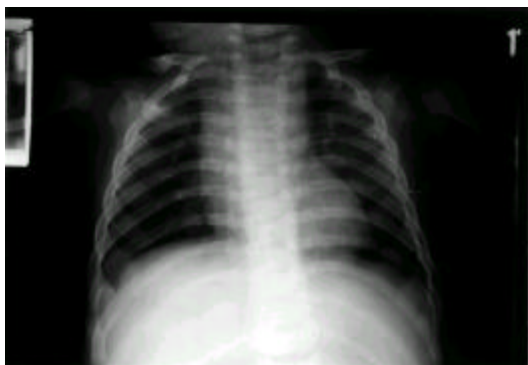

Fig. 1B. Follow up chest radiogram after clinical improvement. Miliary infiltrations were markedly regressed and disappeared on both lungs.

AFB
isoniazid,
rifampin, pyrazinamide, streptomycin
(prednisolon 1mg/kg/day)
(Fig. 3 가
가
가
가
가

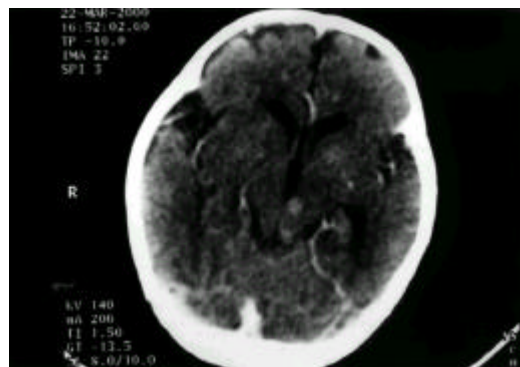


Fig. 2A. Small sized hyperdense nodules were scattered in left basal ganglia, left mid-brain and left frontoparietal region on brain CT, performed at admission.

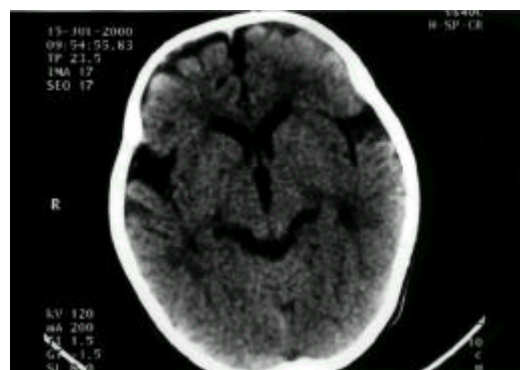

Fig. 2B. Follow up brain CT after clinical improvement. Markedly decreased size and extent of the enhancing nodules on posterior limb of right internal capsule, left portion of the mid-brain both supraventricular gray-white matter junction were seen.

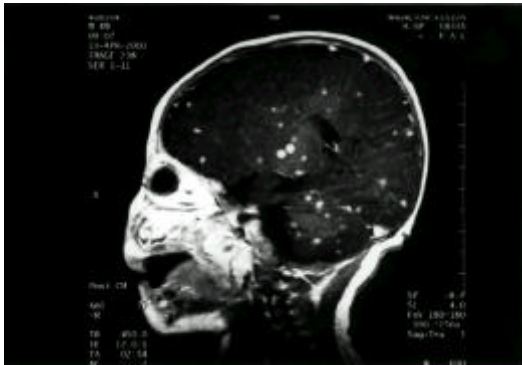

Fig. 3. Multiple enhanced nodular lesions were scattered at the area of gray-white matter junction, cerebellum, pons, medulla, upper cervical spine, mid-brain, thalamus, basal ganglia and internal capsule on sagittal view of MRI, done at the 14th hospital day.

. 7
10
. 12
가 가
가 , 14
(Fig. 3). 29
isoniazid rifampin 12 , pyrazina-
mide 2 streptomycin
1 2 (prednisolone)
(2 prednisolone 1mg/kg ,
2)
1
(Fig. 1B)
(Fig. 2B)

가
1/3
가
가

가 가
1, 5) . BCG

가
(lymphohe-
matogenous dissemination) 2

가
5) . , , , ,

2 6
가 .

2, 5)

가

3

가

6 8)

가 , 가

, BCG 가

가

2, 7, 8)

(Fig. 2A, Fig. 3)

0.2%

가 7, 8)

AFB

(, , ,)

가

가

1, 5) . , 가 1, 2, 5) . , 50% , isoniazid, rifampin, pyrazinamide, streptomycin prednisolon 2 isoniazid, rifampin 가 가 가 가 3 10 가 BCG 가 BCG 4 가 1 (Fig. 1A)

가

6
14

가

4) .

가

- 1) Jeffery RS and Flor Munoz : Tuberculosis. In : RE Behrman, RM Kliegman, HB Jenson eds Nelson 16th ed. Philadelphia, W.B. Saunders Co., 2000, p885-97.
- 2) . 1999;47:5-12.
- 3) Sakao S, Sasaki Y, Yamagishi F, Yagi T, Mizutani F, Tada Y. A case of miliary tuberculosis with multiple cerebral tuberculoma and spinal tuberculosis owing to total delay. *Kekkaku* 1998;73:519-23.
- 4) Garcia-Monco JC. Central nervous system tuberculosis. *Neurologic Clinics* 1999;17:737-59.
- 5) Jeffrey R. Starke and Margaret HD. Smith : Myocardial and pericardial tuberculosis. In : RD Feigin and JD Cherry eds. *Textbook of Pediatric Infectious Diseases*. 4th ed. W.B. Saunders

- Co., 1998, p1209-12.
- 6) Nair KP, Jayakumar PN, Taly AB, Arunodya GR, Swamy HS, Shanmugam V. CT in simple partial seizure in children: A clinical and computed tomography study. *Acta Neurologica Scandinavica* 1997;95:197-200.
 - 7) Natalie N, Lisa S, Pablo SG, Charles K, Susan W, Carrie RS, et al. Diagnosis of pediatric tuberculosis in the modern era. *Pediatr Infect Dis J* 1999;18:122-6.
 - 8) Mark N, Lobato, Kate C, Don W, et al. Tuberculosis in children and adolescents: California, 1985 to 1995. *Pediatr Infect Dis* 1998;17:107-29.
 - 9) Artico M, De Caro GM, Carloia S, Salvati M, D'Ambrosio I., and Delfini R. Advances in diagnosis, treatment and prognosis of intracranial tuberculomas in the last 50 years. Report of 21 cases. *Neurochirurgie* 1999;45:129-33.
 - 10) Farinha NJ, Razali KA, Holzel H, Morgan G, and Novelli VM. Tuberculosis of the central nervous system in children. *J Infect* 2000;4: 61-8.
 - 11) Afgany B and Lieberman JM. Paradoxical enlargement of development of intracranial tuberculoma during therapy. Case report and review. *Clin Infect Dis* 1994;19:1092-9.
 - 12) Lees A, Macleod A and Marshall. Cerebral tuberculoma developing during treatment of tuberculous meningitis. *Lancet* 1980;1:1208-11.
 - 13) Shepard WE, Field ML, James DH, et al. Transient appearance of intracranial tuberculoma during treatment of tuberculous meningitis. *Pediatr Infect Dis J* 1986;5:599-601.
 - 14) Teoh R, Humpries MJ and Sister Gabriel O'Mahony. Symptomatic intracranial tuberculoma developing during treatment of tuberculosis. *QJ Med* 1987;63:449-60.
 - 15) Kim MS, Kim KJ, Chung CK and Kim HJ. Intradural extramedullary tuberculoma of the spinal cord: A case report. *J Korean Med Sci* 2000;15:368-70.
 - 16) Casas GJ, Garcia JL, Rota ZL, Rodriguez MA. Neuro-tuberculosis: Solitary supratentorial tuberculoma and meningitis in a 5-year-old child. *Anales Espanoles De Pediatria* 1998;49:393-6.