

# The Effect of Splinting with Concomitant Root Planing : A Clinical and Digital Subtraction Radiographic Study

Ji-Young Lee, Seung-Bum Kye, Won-Kyoung Kim, Yong-Moo Lee, Young Ku,  
In-Chul Ryu, Sang-Mook Choi, Chong-Pyoung Chung, Soo-Boo Han

Department of Periodontology, College of Dentistry, Seoul National University

## I. Introduction

Tooth mobility is defined as movement of a tooth in a horizontal or vertical direction. All teeth have some degree of mobility which is related to the width of the periodontal ligament, root attachment area, elasticity of the alveolar process and function of the tooth,<sup>1</sup> but pathologic tooth mobility can be caused by periodontal disease, occlusal trauma, orthodontic movement, hyperfunction such as prosthodontic overloading,<sup>2</sup> and specifically advanced periodontal disease results in progressive tooth mobility, pathologic migration, and extrusion due to reduction in height of the supporting tissues.<sup>3</sup>

Excessive tooth mobility might be severe impairment to function and comfort of some patients, and might inhibit repair during periodontal therapy.<sup>3</sup> As a treatment to do decrease mobility, increased tooth mobility due to widening of the periodontal ligament could be treated by occlusal adjustment, increased tooth mobility due to reduced height of the supporting structures could be treated by splinting, and tooth mobility resulting from combination of a widened periodontal ligament and reduced height of the supporting structures, could be treated

by occlusal adjustment first, and if unsatisfactory splinting therapy is added.<sup>4</sup> Objectives of splinting for resolution of tooth mobility resulting from reduced height of the supporting structures are, to rest the affected structures by limiting the forces to which they can be subjected, to alter the direction of supplied forces, to stabilize proximal contacts, and to prevent supraeruption of teeth.<sup>2</sup>

Since their development in 1895, radiographs have become indispensable diagnostic tools in dental field. Radiographs are the most common non-invasive method to diagnose caries, periapical lesions, and to detect changes in alveolar bone,<sup>5</sup> and in periodontology radiographs serve as a permanent record of osseous morphology and can be used to assess bone loss resulting from periodontal disease. Radiographs are unique in that they not only allow for linear measurement of bone loss, but also may provide area and volume measurement of the osseous topography associated with the periodontal lesion.<sup>6</sup> Radiography is limited because it is a restricted 2-dimensional representation of 3-dimensional anatomy. As a result, many features of the anatomy are not apparent to the examiner during visual examination of the radiograph. This is due to

limitations imposed by the physics and geometry of radiography, as well as the examiner's perception of the radiographic image. The perception of the radiographic image may be the rate-limiting factor in conventional radiography, in that 30% to 60% of the mineral content of the bone must be lost in order to visualize changes on a radiographic image,<sup>7</sup> and mild destructive lesions in bone do not cause sufficient alteration in density to be detected.<sup>8-10</sup> Furthermore, when active periodontal destruction occurs during disease activity, the earliest phases of resorptive changes in a periodontal defect are obscured by a still-existing cortical plate,<sup>11-16</sup> therefore radiographic images tend to show less severe destruction than is actually present.<sup>17</sup>

It is difficult to standardise the alignment of films, subject and X-ray source, and even when methods to standardise are used, monitoring disease progression by examining pairs of intra-oral images with the naked eye may only reveal gross changes in alveolar bone.<sup>18</sup>

Recently computer aided analysis is becoming used to resolve the problems above mentioned and to detect early changes in mineralized tissue, and one of the most widely used methods is digital subtraction radiography. This method was introduced to dental diagnosis by Rüttiman et al, Webber et al, and Gröndahl et al, and has shown potential value in the diagnosis and monitoring of alveolar bone loss in periodontal diseases and in evaluating treatment.<sup>19-21</sup>

The rationale of digital subtraction radiography is based on the fact that unchanged anatomical structures cancel in the subtraction image, resulting in a less-complex background pattern, against which diagnostically-interesting tissue changes can be seen more easily.<sup>22</sup> Subtraction radiography greatly increases detection sensitivity by cancelling structured noise,<sup>23</sup> and Ortman et al demonstrated that

this method could detect a loss of bone mineral per unit area of 5%.<sup>24</sup> However, several problems arise that are unique to subtraction radiography. These include standardization of geometric, densitometric and registration procedures.<sup>25</sup> The interpretation of a digitized subtraction image is limited by the extent and character of structured noise in the image.<sup>26,21</sup> A factor which can contribute to structured noise in a subtraction image is a difference in film contrast and density. Rüttiman et al, showed that, within certain limits, it is possible to correct differences in film density and contrast by gamma-correcting algorithm.<sup>27</sup> Structured noise can be produced by inadequate alignment of radiographs with corresponding projection geometry also. To minimize occurrence of serial radiographs with discrepant geometries, fixation between x-ray source, object, and film is necessary. This can be achieved using a custom prepared stent and cephalostat,<sup>27-30</sup> and since 1980s, geometric reconstruction algorithms that use reference points as a basis for correction of geometric discrepancies have been introduced.<sup>31,32</sup>

Dunn et al,<sup>5,33</sup> have shown that mathematical technique using 4 reference points can be applied to digital images of radiographs to establish correspondence between pairs of images taken at different projection angles. Emago<sup>®</sup> software(The Oral Diagnostic System, Amsterdam, The Netherlands) is recently developed by them for mathematical correction of angulation differences.

Digital images may be acquired either indirectly by digitization of conventional radiographic film using a videocamera,<sup>22,34</sup> or directly by using a CCD detector(Charge-Coupled Device),<sup>35</sup> and recently the Digora<sup>®</sup> system(Soredex, Orion Corporation Ltd., Helsinki, Finland) has become available, which uses imaging plates to produce direct digital images by a process known as Photo Stimulable Phosphor Luminescence(PSPL).<sup>36</sup> In this study, Digora<sup>®</sup> system was

used for digital image acquisition and Windows-based Emago / Advanced version 3.2 software was used for image processing and radiographic assessment.

This study was performed to investigate the efficacy of splint therapy as an adjunct to root planing using a digital subtraction radiography.

## II. Materials and Methods

### 1. Study Design

To compare the efficacy of 2 treatment modalities, a randomized prospective parallel mouth design was employed in this study. The 2 experimental treatments were root planing with concomitant splinting as a test and root planing as a control. To minimize the potential impact of gingivitis on the outcome of therapy, prophylaxis for removing all supragingival plaque and calculus was done at initial screening visit. Two weeks after initial prophylaxis, baseline clinical and radiographical measurements were taken. Clinical outcomes were evaluated at the 3 months and at the 6 months visits, and radiographical outcomes were evaluated at the 6 months visit. (Figure 1) All participants gave informed consent.

### 2. Patients and Sites Selection

All patients suffering from moderate to advanced

periodontitis were recruited from the patient contingent of the Department of Periodontology of the Seoul National University Dental Hospital. Eleven patients (6 male, 5 female; age: 33-66 years) constituted the final subject population.

At baseline, patients were enrolled in the present study according to the following entry criteria: absence of systemic disease, no history of systemic medications (including antibiotics) and periodontal therapy in the previous 3 months, no known allergies, presence of moderate to advanced periodontitis, no loss of any of lower anterior 4 teeth, including anterior teeth with mobility of 2 or 3 degree, including anterior teeth with  $\geq 50\%$  alveolar bone loss evidenced by radiographs and  $\geq 6\text{mm}$  clinical attachment loss, no malalignment or crossbites, no history or obvious signs of severe parafunctional activities, no hormonal imbalance, menstrual disturbance, or pregnancy which can influence tooth mobility

#### 1) Clinical Procedure

At baseline, clinical examinations were performed, and root planing and occlusal adjustment were done on all test and control group patients. One month after root planing, lower anterior teeth were splinted with wire and resin for test group patients. Subjects were recalled in monthly professional tooth cleansing, and were also instructed proper home care with 0.1% chlorhexidine gluconate solution for oral gargle.

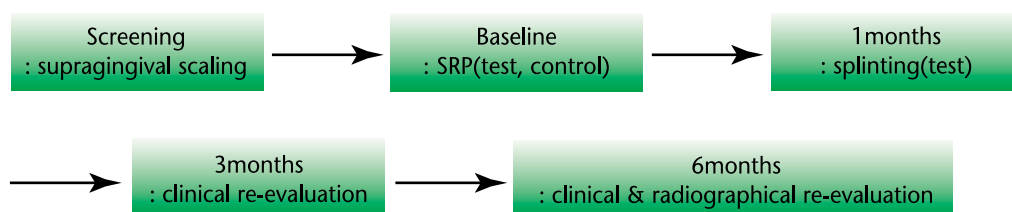


Figure 1. Experimental Procedure

## 2) Clinical Assessment

At baseline, 3 and 6 months after initial treatment, assessment of periodontal status was performed, by one examiner, with the following sequence : gingival condition(gingival index, GI, Löe & Silness, 1963)<sup>37</sup>; oral hygiene status(plaque index, PII, Silness & Löe, 1964)<sup>38</sup>; position of gingival margin recession(REC, was measured as the distance from the cemento-enamel junction or the margin of a filling to the free gingival margin and was measured to the nearest millimeter using calibrated periodontal probe at 6 sites per tooth.); probing pocket depth(PPD, was measured from the free gingival margin to the base of the periodontal pocket using a pressure sensitive electronic Florida probe at 6 sites per tooth.); clinical attachment level(CAL, values from REC + PPD); clinical attachment gain(CAG, differences between baseline, 3 and 6 months clinical attachment level values); bleeding on probing(BOP, assessed at a force of 0,3 N with Florida probe, recorded as presence(1) or absence(0) within 30 seconds.); tooth mobility(measured with Periotest<sup>®</sup> (Siemens AG, Bensheim, Germany) and measured by method according to Lindhe <sup>39</sup>)

The tooth with the largest CAL value at baseline was used for further comparison and statistical analysis.

## 3) Radiographic Procedure

### Conventional radiographic image acquisition

Radiographic examination was carried out at baseline and 6 months after initial treatment. Periapical radiographs were taken using paralleled technique and occlusal bite record(Impregum, ESPE, Germany) attached to the bite-block. The biteblocks were saved and re-used for the postoperative radiographic examination 6 month later.

No. 2 Kodak Ektaspeed films(Eastman Kodak Co, Rochester, NY) were used and Heliodont X-ray unit(Siemens Co., Germany) operating at 70kVp and 0,13 sec. was used for radiographic exposure. The radiographs were processed in a PERIOMAT automatic processor.(D?RR TECHNIK, Germany). The radiographs were scanned using Adobe Photoshop version 5.0 program.

### Digital radiographic image acquisition and digital image processing

Digital images were taken using Digora<sup>®</sup> imaging system(Soredex Co., Finland). Heliodont X-ray unit(Siemens Co., Germany) operating at 70kVp and 0,13 sec was used for radiographic exposure and impression was made on a separate bite block using an impression material(Impregum, ESPE, Germany).

Obtained images were processed on the Emago<sup>®</sup> Advanced version 3,2 software(The Oral Diagnostic System, Amsterdam, The Netherlands).

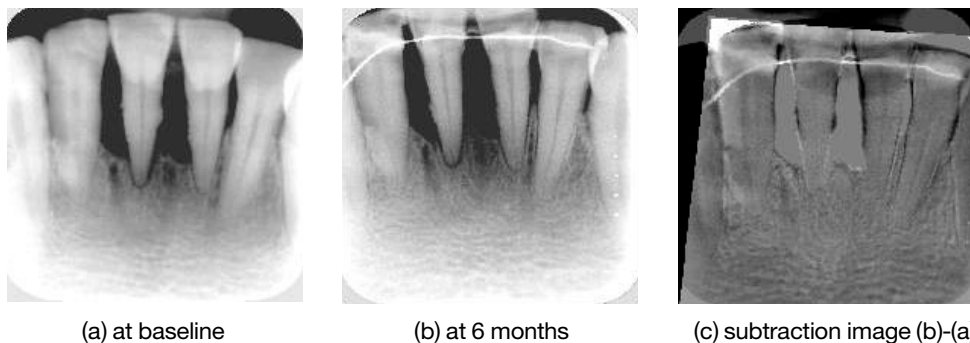


Figure 2. Example of digital subtraction radiography

The preoperative images of each tooth was used as the reference image. Four points (2 CEJ's of target tooth and adjacent tooth, 2 apices of target tooth and adjacent tooth) were marked with a mouse in the reference image. Each second image was reconstructed via the same four points and subtracted according to its reference image by the geometric standardization software (Figure 2).

#### 4) Radiographic Assessment

##### **Conventional radiographic assessment**

The tooth length and marginal bone level were measured on the scanned radiographs. ximo-incisal angle was used as reference point for the measurements of tooth length while the bone levels were measured from the most coronally positioned level of the bone subadjacent to the tooth surface to a line through the apex of the tooth and perpendicular to its longitudinal axis. The measurement of tooth length was to assess the reproducibility with regard to tooth enlargement between the preoperative and postoperative radiographs. Using measuring device, the tooth length and the bone level were measured. The bone gain or loss at 6 months post-operatively was

calculated mathematically. The measurements were repeated 3 times and the means were used.

##### **Digital radiographic assessment**

After reconstruction, if bone gain or loss was observed, area of bone formation or resorption was estimated and expressed in pixels. All areas were measured 3 times, and the means were used. The measurements were converted to mm's on the basis of the size of a pixel.

#### 5) Statistical Analysis

The results were analyzed with SPSS version 7.5 software. Baseline values in the 2 treatment groups

were compared using the Mann-Whitney test for all clinical measurements. The Wilcoxon signed rank test was applied in order to evaluate clinical and radiographic changes between the 2 treatment groups as well as within the groups. P values  $\leq 0.05$  were considered significant.

The non-parametric Mann-Whitney and Wilcoxon tests were preferred to their parametric equivalents (the unpaired and paired *t*-tests, respectively) because the small size of the samples made it difficult to check the assumption of normal distributions.

Kendall's correlation analysis was used to evaluate the relationship between the clinical and two radiographic measurements at the 6-months examination.

### **III. Results**

#### **1. Clinical Results**

##### **1) Baseline description**

Baseline characteristics of test and control tooth are shown in Table 1. The selected tooth presented with clinical attachment levels of  $7.53 \pm 2.16$  mm in the test group and  $7.72 \pm 1.49$  mm in the control group.

No significant difference in baseline characteristics was observed comparing the test with the control group (Table 1, Figure 3).

##### **2) Plaque index (PI)**

The mean clinical recordings at baseline, 3 and 6 months are presented in Table 2.

At 3 and 6 months PI scores remained low or improved with respect to the values detected at baseline, indicating that the monthly monitoring and recall was effective in further improving patient compliance and plaque control. There was signifi-

Table 1. Baseline Characteristics(mm)

	RP	RP + splint	P
PI	0,93(0,42)	0,89(0,33)	0,792
GI	0,73(0,30)	0,86(0,33)	0,662
PPD	4,09(0,37)	4,14(0,93)	0,662
REC	3,63(1,86)	3,39(2,03)	0,792
CAL	7,72(1,49)	7,53(2,16)	1,000
BOP	0,80(0,45)	1,00(0,00)	0,662
Mob(Periotest)	30,40(12,90)	31,17(12,97)	0,931
Mob(Miller)	2,20(0,45)	2,33(0,52)	0,792

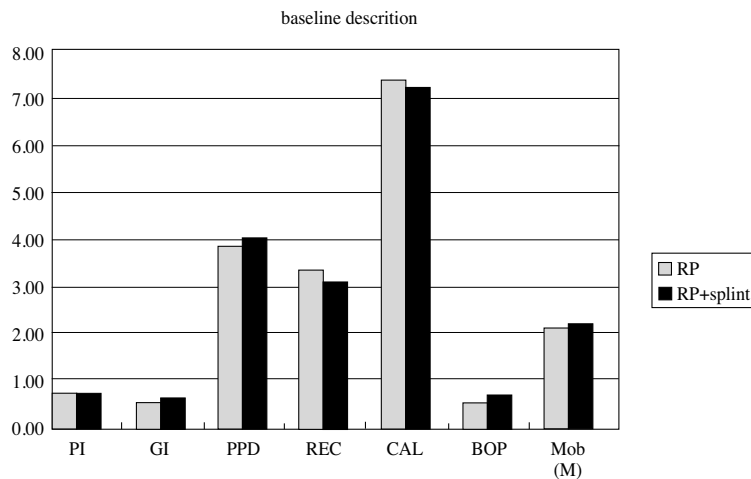


Figure 3. Baseline Characteristics

cant difference from baseline to 6 months for the control group( $p < 0.05$ ) but at 6 months there was no statistically significant difference between the test and the control group. ( $p > 0.05$ ).

Specifically, at 3 and 6 months PI scores were higher in test group indicating difficulty in controlling plaque with splinting(Table 2, Figure 4).

### 3) Gingival index(GI)

At 3 and 6 months GI scores decreased for both test and control group indicating that the monthly monitoring and recall was effective in further improving infection control, but there was no signifi-

cant change within the group( $p > 0.05$ ) and there was no statistically significant difference between the test and the control group( $p > 0.05$ )(Table 2, Figure 5).

### 4) Probing pocket depth(PPD)

In test group, the mean initial PPD of 4.13mm changed to 3.52mm at 3 months and 3.17mm at 6 months, respectively. The changes in PPD were statistically significant after 3 and 6 months( $p < 0.05$ ). After 3 and 6 months, the mean 0.61mm and additional 0.35mm reduction in PPD was due to gain in CAL(0.07mm, 0.02mm,  $p > 0.05$ ) and recession(Table

Table 2. Comparison of clinical Measurements between the test and the control group

	RP			RP+splint		
	Baseline	3months	6months	baseline	3months	6months
RI	0.93(0.45)	0.63(0.42)	0.50(0.17)*	0.89(0.33)	0.72(0.36)	0.63(0.42)
GI	0.73(0.30)	0.63(0.14)	0.50(0.48)	0.86(0.52)	0.58(0.44)	0.56(0.33)
PPD	4.09(0.37)	3.86(0.37)*	3.45(0.81)*	4.13(0.93)	3.52(0.97)*	3.17(0.74)*
REC	3.63(1.86)	3.77(1.74)	4.10(2.11)	3.39(2.03)	3.95(2.19)*	4.28(1.93)*
CAL	7.72(1.49)	7.62(1.39)	7.56(2.18)	7.53(2.16)	7.46(2.12)	7.44(1.99)
BOP	0.80(0.45)	0.40(0.55)	0.40(0.52)	1.00(0.00)	0.33(0.52)*	0.33(0.47)*
Mob(Periotest)	30.40(12.90)	-	25.80(9.42)	31.17(12.97)	-	26.67(8.60)
Mob(Miller)	2.20(0.45)	-	1.80(0.41)	2.33(0.52)	-	1.93(0.37)

\*Wilcoxon signed rank test( $P < 0.05$ ), values of standard deviation in parenthesis

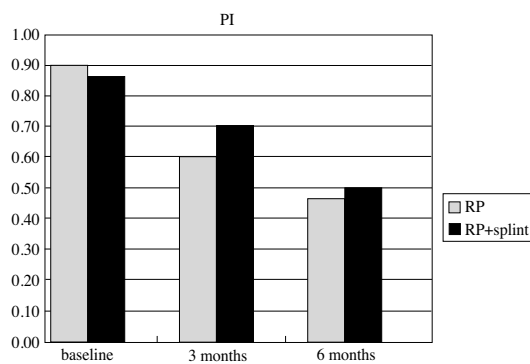


Figure 4. Plaque Index

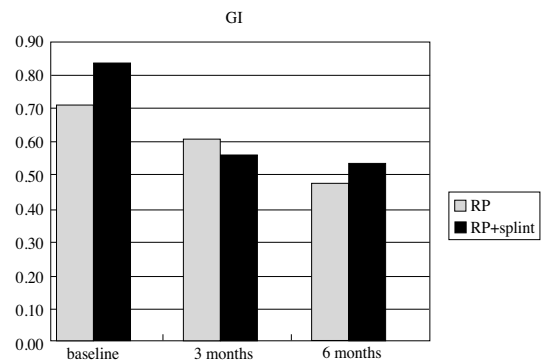


Figure 5. Gingival Index

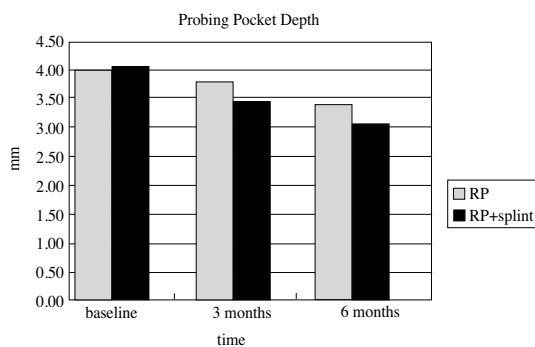


Figure 6. Probing Pocket Depth

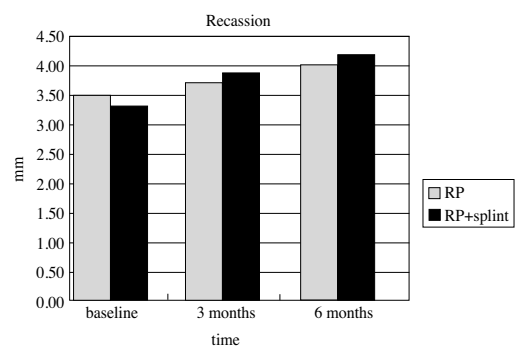


Figure 7. Gingival Recession

2, Figure 6).

The mean initial PPD of the control group was 4.09mm. The mean residual PPD was 3.86mm at 3

months and 3.45mm at 6 months, respectively. The change in PPD was statistically significant after 3 and 6 months( $p < 0.05$ ). After 3 and 6 months, the mean

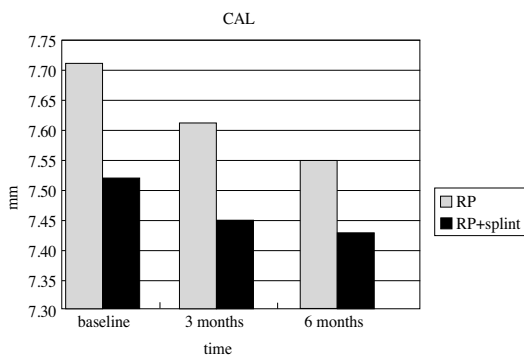


Figure 8. Clinical Attachment Level

0.23mm and additional 0.41mm reduction in PPD was due to gain in CAL(0.10mm, 0.06mm,  $p>0.05$ ) and recession(Table 2, Figure 6).

#### 5) Gingival recession(REC)

At baseline, mean REC was 3.39mm for the test group and 3.63mm for the control group, respectively. The mean REC at 3 and 6 months was 3.95mm and 4.28mm for the test group and 3.77mm and 4.10mm for the control group, respectively.

There was no significant difference within the group nor between the groups( $p>0.05$ )(Table 2, Figure 7).

#### 6) Clinical attachment level(CAL)

At baseline, mean CAL was 7.53mm for the test group and 7.72mm for the control group. The mean CAL at 3 and 6 months were 7.46mm and 7.44mm for the test group and 7.62mm and 7.56mm for the control group. There were no significant differences within the group nor between the groups( $p>0.05$ )(Table 2, Figure 8).

At 3 months, CAL gains were 0.07mm for the test group and 0.10mm for the control group, and at 6 months CAL gains were 0.02mm for the test group and 0.06mm for the control group(Table 2, Figure

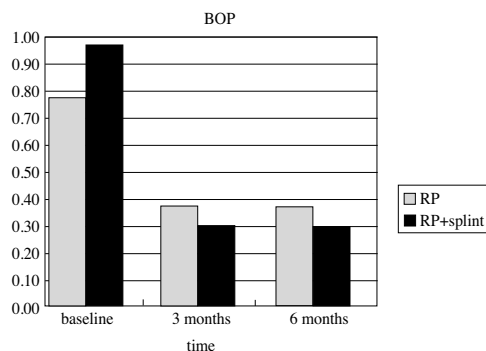


Figure 9. Bleeding on Probing

8).

There was no significant difference within the group nor between the groups( $p>0.05$ ).

#### 7) Bleeding on probing(BOP)

At the baseline, all gingival units in test group and 80% of gingival units in control group bled on probing. 3 months later 40% gingival units in control group and 33% gingival units in test group bled on probing. There was significant decrease of bleeding, both of the test and the control group( $p<0.05$ ), but there was no significant difference between the groups( $p>0.05$ ). There was no difference between and 6 month neither for the test nor for the control group( $p>0.05$ )(Table 2, Figure 9).

## 2. Mobility

At baseline, mean mobility values were 31.17 for the test group and 30.40 for the control group when measured by Periotest<sup>®</sup>. The mean mobility values at 6 months were 26.67 for the test group and 25.80 for the control group without significant decrease of mobility in both groups( $p>0.05$ ), and there was also no significant difference between the groups ( $p>0.05$ )(Table 2, Figure 10).

At baseline, mean mobility indices measured by



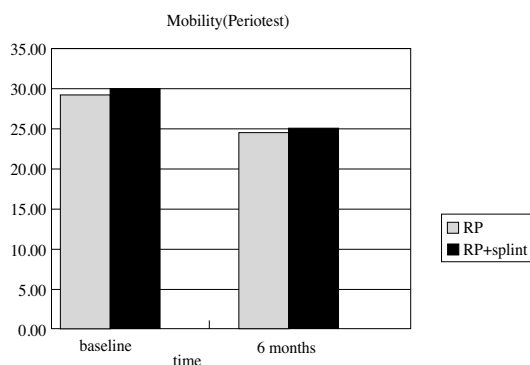


Figure 10. Mobility(by Periotest)

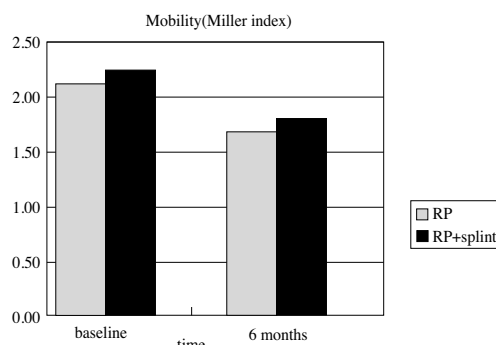


Figure 11. Mobility(by Miller Index)

Lindhe's method were 2.33 for the test group and 2.20 for the control group. The mean mobility indices at 6 months were 1.93 for the test group and 1.80 for the control group. There were no significant differences within the group nor between the groups( $p>0.05$ )(Table 2, Figure 11).

### 3. Radiographic Results

The radiographic recording was reproducible with regard to tooth enlargement as no significant differences were observed between tooth lengths on the conventional radiographs taken at baseline and at 6 months( $p>0.05$ )(Table 3).

The clinical measurements indicated a gain of attachment in 64% of all teeth with 50% of test group teeth and 80% of control group teeth and indicated a loss of attachment in 36% with 50% of test group teeth and 20% control group teeth after 6

months. Bone gain was recorded in 55% of all treated teeth with 33% of test group teeth and 80% of control group teeth, bone loss was recorded in 45% of the treated teeth with 67% of test group teeth and 20% of control group teeth after 6 months by conventional radiography. Digital subtraction radiography revealed bone gain in 19% of all treated teeth with 17% of test group and 20% of control group, bone loss in 19% with 33% of test group, unchanged bone in 62% with 50% of test group and 80% of control group after 6 months(Table 4). The relationship between the clinical and the radiographic assessments at the 6-months is shown in Table 2. 5 of the 10 teeth demonstrating bone gain as assessed by conventional radiographs did also demonstrate a clinical gain of attachment, (Table 4) The correlation between the clinical and conventional radiographic assessments was low( $r=0.11$ ,  $p=0.64$ ).

The correlation between the clinical and digital

Table 3. Comparison of tooth length(TL) measurements in order to evaluate the reproducibility of the radiographic recordings

	TL(baseline)	TL(6months)
mean	20,51mm	20,32mm
min	17,20mm	17,30mm
max	24,20mm	24,00mm

**Table 4. Relationship between clinical attachments and assessment of bone changes on conventional radiographs and subtraction images at the 6 months**

		RP clinical			RP+splint clinical			total clinical		
		AG	UC	AL	AG	UC	AL	AG	UC	AL
conventional radiograph	BG	4	-	-	1	-	1	5	-	1
	UC	-	-	-	-	-	-	-	-	-
	BL	-	-	1	2	-	2	2	-	3
digital subtraction image	BG	1	-	-	1	-	1	2	-	1
	UC	3	-	1	2	-	-	5	-	1
	BL	-	-	-	-	-	2	-	-	2

\*CR ; conventional radiograph, DSR ; digital subtraction radiograph

\*AG ; attachment gain, UC ; unchanged, AL ; attachment loss,

BG ; bone gain, BL ; bone loss

**Table 5. Clinical attachments and radiographic bone changes at 6 months(mean in mm)**

	mean gain(RP/RP+splint)	mean loss(RP/RP+splint)
clinical attachment level	0.26(0.23/0.31)	0.13(0.1/0.14)
bone changes on CR	0.22(0.15/0.35)	0.17(0.14/0.17)
bone changes on DSR	0.88(0.74/1.03)	0.62(-/0.62)

subtraction assessments was higher( $r=0.26$ ,  $p=0.32$ ).

For the teeth exhibiting a gain of clinical attachment, the mean gain was 0.26mm at the 6 months examination. The mean bone gain for the teeth exhibiting bone gain on conventional radiographs was 0.22mm and the mean bone gain for the teeth exhibiting bone gain on digital subtraction images was 0.88mm(Table 5).

## IV. Discussion

In this study, there were changes in clinical parameters at 3 and 6 months, with significant changes in PPD, REC, BOP with no significant differences between two groups(Table 2). At 3 and 6 months, PI scores remained low or improved with respect to the values detected at baseline. Especially, at 3 and 6 months PI scores were higher in test group indicating difficulty in controlling plaque with splint-

ing(Table 2). To facilitate adequate access for cleansing, a splint must be placed open gingival embrasures and must be properly contoured with no overhanging margins. All surfaces must be smooth to minimize plaque retention. A splint that meets these criteria does not interfere with effective oral hygiene practices, preserves gingival tissues, and helps maintain caries - free tooth structures.<sup>40</sup> In the present study, in test group, many crowded teeth were included in the splint, therefore it was much more difficult to control plaque. Manual plaque control devices, such as floss, knitting yarn, interdental brush, and mechanical plaque control devices, such as powered tooth brush, powered interdental brush would aid in plaque control.<sup>41</sup>

In this study, in an attempt to control or standardize the factor of inflammation, regular prophylaxis, supervision of oral hygiene were carried out during the monitoring period. At 3 and 6 months, GI scores

decreased for both test and control group with no significant change within the group nor significant difference between the groups (Table 2). These findings are in agreement with the results of the previous study.<sup>42</sup> In that study, it was shown that although some gingival inflammation persisted, it was similar around both splinted and unsplinted teeth and that regular 1-month prophylaxes could reduce but could not control sulcular inflammation completely in periodontally involved cases.<sup>42</sup>

It's possible that marginal adaptation difficulties of composite resin as a part of A splint combined with ineffective plaque control could exacerbate gingival inflammation adjacent to this material, thus increasing periodontal disease risk in susceptible individuals and some authors reported that composite resins are linked to higher gingival crevicular fluid accumulation which is a sensitive indicator quantifying gingival inflammation than that found adjacent to enamel or glass ionomer cement restoration.<sup>41,42</sup>

In test group, the PPD reduction measured at 3 months was 0.51mm and additional probing depth reduction measured at 6 months was 0.35mm. In control group, the PPD reduction measured at 3 months was 0.23mm and additional probing depth reduction measured 6 months was 0.41mm (Table 2). These findings are in general agreement with findings previously reported from studies evaluating the effects of non-surgical therapy.<sup>43,44</sup> In measuring probing pocket depth, the intraexaminer variability was minimized by using a pressure-calibrated (constant force) Florida probe.

BOP has been commonly used as a diagnostic criterion for periodontal disease.<sup>45</sup> In the present study, there was significant decrease of bleeding, both of the test and the control group, but there was no significant difference between the groups (Table 2) and these findings are in agreement with the previous study which showed that the number of

bleeding surfaces 17 weeks after treatment was similar for the splinted and unsplinted groups of teeth with significant reduction compared with those of before treatment<sup>42</sup>. As above mentioned, the GI score which is also indicator of gingival inflammation was also markedly reduced after treatment for both groups, and this decrease in gingival inflammation following treatment was in agreement with findings previously reported.<sup>42</sup>

The tooth mobility was markedly reduced 6 months after treatment for both groups without significant differences within the group nor between the groups ( $p > 0.05$ ).

The effect of splinting on tooth mobility has controversy, but it seems to be generally accepted that splinting has no additive effect on the reduction of tooth mobility.

Studies investigating mobility posterior teeth found that the stabilizing effects of a splint are transient and that after scaling and root planing, occlusal adjustment, and oral hygiene education, there was no significant difference in mobility between splinted and nonsplinted teeth, and that more mobile teeth received no significant benefit from splinting when compared with less mobile teeth.<sup>46,47</sup>

Renggli and Mühlemann (1970)<sup>48</sup> reported that increased tooth mobility in occlusal trauma decreases greatly to 18-28% soon after removal of occlusal interferences by grinding and there is only little evidence that mere splinting of teeth exerts a similar biological effect on the periodontal ligament.

Renggli et al (1971)<sup>49</sup> also reported that tooth mobilities with splints removed, measured after 6 months of splinting, did not differ significantly from the mobilities measured prior to splint placement.

Rateitschak (1963)<sup>50</sup> noted after 24 months a 14% decrease in tooth mobility after curettage and occlusal adjustment.

In this study, it was shown that the clinical gain of

attachment was accompanied by the formation of new alveolar bone to a varying extent.

The mean clinical attachment gain after 6 months was 0.26mm and mean clinical attachment loss after 6 months was 0.13mm.

The mean bone gain on conventional radiograph after 6 months was 0.22mm and mean bone loss after 6 months was 0.17mm.

And the mean bone gain on digital subtraction radiograph after 6 months was 0.88mm with 0.74mm for control group and 1.03mm for test group, and mean bone loss after 6 months was 0.62mm with 0.62mm for test group (Table 5).

In the present study, at 6 months after treatment bone gain was recorded in 55% of all treated teeth and bone loss was recorded in 45% of the treated teeth by conventional radiography. Digital subtraction radiography revealed bone gain in 19% of all treated teeth and bone loss in 19%, unchanged bone in 62% (Table 4).

According to these results, information from the conventional radiograph was very different from that from the digital subtraction radiograph, this seems to be due to difficulty in determining boundaries between "changed" and "unchanged" bone. Actually, assessment of digital subtraction radiograph revealed unchanged bone in 62%, but assessment of conventional radiograph revealed no evidence of unchanged bone. The previous study reported that in analysis of conventional radiograph, unchanged appearance was defined as changes smaller than 0.9mm which means that 1-mm limit for a clinically significant change was chosen.<sup>55</sup> And subtraction images not only reflect changes in alveolar bone height but also bone fill of the defect, the longer observation period, for example, 12 months would get more agreement between the information from the conventional radiograph and that from digital subtraction radiograph, this was evidenced in

the previous study.<sup>51</sup>

According to Kendall's correlation analysis indicating the relationship between the clinical and the radiographic assessments at the 6-months, the correlation between the clinical and conventional radiographic assessments was low ( $r=0.11$ ,  $p=0.64$ ) and the correlation between the clinical and digital subtraction assessments was higher ( $r=0.26$ ,  $p=0.32$ ), thus bone changes after treatment correlated better with the clinical measurements of attachment gain when assessed by digital subtraction radiograph than when assessed by conventional radiograph. This finding is in agreement with the results of other studies showing a poor relationship between conventional radiographic assessments and clinical measurements<sup>52-54</sup> and a good relationship between digital subtraction radiographic assessment and clinical measurements.<sup>55</sup>

Emago program used in the present study automates the mathematical reconstruction which corrects for the differences in exposure angles, and subtraction procedures. Of particular importance in oral imaging is the change in density or contrast that may occur in serial radiographic images. Density and contrast changes caused by fluctuations in the line voltage, exposure settings of film or processing may lead to variations in the overall density and contrast of the image. As the assessment of alveolar bone gain or loss is made by subtracting the gray levels of two images to isolate changes that have occurred, subtraction methods require that the film pairs have nearly identical density and contrast.<sup>22</sup> The matching of the density and contrast of the two films commonly is done by employing a contrast correction algorithm in computer program.<sup>21,56</sup>

Dunn et al (1992)<sup>5</sup> reported that invariants on a radiographic image can be used to describe the relationship of pairs of images with angular disparity of up to  $32^\circ$ . In a subsequent study, it was shown that

this registration procedure could be used to establish correspondence between pairs of clinical images taken at different projection angles using four featuring points.<sup>33</sup>

Validation research for subtraction radiography also examined how small a lesion could be detected with a high degree of diagnostic accuracy. The minimal thickness of bone that may be detected under optimal conditions (no geometric or contrast distortion) was found to be 0.12mm.<sup>57</sup> This study also examined the effect of variations in projection geometry. When the angulation was misaligned by 3°, the minimal thickness of cortical bone that could be detected was 0.35mm to 0.42mm.

The mandibular anterior teeth used in the present study are the longest surviving teeth of the periodontium.<sup>58,59</sup> Thus if teeth present with 50% to 70% bone loss, one can be confident that with proper stabilization including splinting therapy and periodontal maintenance, survival of the teeth is possible.

Nyman et al demonstrated long-term stability and maintenance of splinted dentitions that had greater than 50% attachment loss of each abutment tooth. Although Ante's law was not satisfied, in the absence of inflammation, severely periodontally compromised dentitions could be maintained for extended periods of time, in some cases more than 20 years.<sup>60,61</sup>

Although the effect of splinting is controversial, the use of the temporary splinting is indicated in the following circumstances: where mobility of the teeth exists, so that physiologic rest can be effected, where mobility exists to such a degree that effective periodontal treatment and procedures cannot otherwise be executed properly, as a diagnostic aid to evaluate the prognosis before instituting extensive permanent splinting, to improve the psychological morale of the patient with mobile teeth.<sup>62,63</sup>

Besides the above mentioned indications, splinting has some advantages, for example, facilitation of occlusal adjustment, prevention of food impaction by stabilization of proximal contacts, facilitation of healing of diseased supporting tissue, enhancement of postsurgical healing, and so on.<sup>64</sup>

The term "A-splint" used in the present study was apparently popularized by Berliner and Kessler<sup>65</sup> and has evolved into dental terminology as an easy way to describe the wire-reinforced acrylic resin-amalgam splint. More recently the term "A-splint" has come to include any splint that ties teeth together with acid-etched composite materials; usually there is wire reinforcing included.<sup>64</sup>

Ideally an "A-splint" should have the following characteristics: provide adequate stabilization for the mobile teeth; have adequate retention; require removal of as little tooth structures possible; be able to be completed in a comparatively short time; not interfere with the patient's ability to practice good oral hygiene, be esthetic.<sup>65</sup>

However, "A-splint" has some common problems, and these are overcontouring in an effort to make the splint strong enough to resist fracture, esthetic problem, wire stability, arch stability, caries due to the possible percolation of acrylic resin.<sup>64,65</sup> Overcontouring can be avoided by finishing "A-splint" with the same principles as cast restorations and placement of an interproximal brush should be allowed. To improve wire stability double strands of wire, twisted strands of wire, cast bars, modified matrix bands, and prefabricated bars were suggested and the most versatile option is the 13- or 15-gauge half-round wire. To get arch stability, one must gain support in two or more planes.<sup>64,66</sup> If the A-splint includes a curve, then all the splinted teeth will appear less mobile. This usually requires including the canines in a posterior splint. Including crossarch splinting increases the multiplane curve

and thus creates even more stabilization, i.e. reduced mobility. To reduce caries problem, stannous fluoride can be applied to the preparations, and caries incidence maybe related to the retention of the acrylic to the teeth, thus the vertical and horizontal wires for increasing retention may decrease the caries susceptibility.<sup>65</sup>

Recently innovative technique employing a bondable, ribbon-splinting material for reinforcing dental resins or fiber-reinforced composite resin has developed.<sup>73</sup> By combining the chemical adhesive and esthetic characteristics of composite resin with the strength enhancement of a plasma-treated, high-modulus, splints can resist the load -bearing forces of occlusion and mastication. These fracture-resistant restorations are more durable than most adhesive-composite resin alternative splinting materials of the past.

Although the effect of splinting has controversy, the general trend seems to be that unless final splinting is indicated, temporary splinting during periodontal treatment should be avoided and that a decision to splint, for reasons of mobility, should usually be reserved until initial therapy has been completed but that there are many other factors such as patient discomfort from loose or missing teeth which may, of course, dictate otherwise.<sup>67,68</sup>

In the present study, it can be surmised that the splinting has no additive effect on the periodontal treatment, but a more definite, well-controlled study with the larger sample size is needed to clarify this finding.

## V. Conclusion

The aim of this study was to compare the effects of root planing only with those of root planing with concomitant splinting clinically and radiographically, to compare information from digital subtraction and

from conventional radiography with clinical recordings for the assessment of bone changes, finally to investigate the efficacy of splinting therapy and it can be concluded that,

1. There were changes in clinical parameters at 3 months, with significant changes in PPD, REC, BOP ( $p < 0.05$ ) with no significant differences between two groups ( $p > 0.05$ ).
2. There were also changes in clinical parameters at 6 months, with significant changes in PPD, REC, BOP, PI, ( $p < 0.05$ ) with no significant differences between two groups ( $p > 0.05$ ).
3. Kendall's correlation analysis shows that the correlation between the clinical and the CR assessments low and did not differ significantly from zero ( $r = 0.110$ ,  $p = 0.639$ ) and that there was higher correlation between the clinical and the DSR assessments ( $r = 0.257$ ,  $p = 0.315$ ) indicating that bone changes following periodontal treatment correlated better with the clinical measurements of attachment gain when assessed by DSR than when assessed by CR.

According to these results, we surmised that splinting has no additive effect on Root Planing in periodontal treatment.

## VI. References

1. Lemmerman K. Rationale for stabilization, *J Periodontol* 1976; 47: 405-411
2. Ferencz JL. Splinting. *Dent Clin North Am* 1987; 31: 383-393
3. Fleszar TJ, Knowles JW, Morrison EC, Burgett FG, Nissle RR, Ramfjord SP. Tooth mobility and periodontal therapy. *J Clin Periodontol* 1980; 7: 495-505
4. Nyman S, Lindhe J. Persistent tooth hypermobili-

- ty following completion of periodontal treatment. *J Clin Periodontol* 1976; 3: 81-93
5. Dunn SM, Van der Stelt PF. Recognizing invariant geometric structure in dental radiographs. *Dentomaxillo Radiol* 1992; 21: 142-147
6. Reddy MS. Radiographic methods in the evaluation of periodontal therapy. *J Periodontol* 1992; 63: 1078-1084
7. Proceedings of the workshop on quantitative evaluation of periodontal diseases by physical measurement techniques. *J Dent Res* 1979; 58: 547-551
8. Ainamo J, Tammisäo E. Comparison of radiographic and clinical signs of early periodontal disease. *Scand J Dent Res* 1973; 81: 548-552
9. Akiyoshi M, Mori K. Marginal periodontitis : a histological study of the incipient stage. *J Periodontol* 1967; 38: 42-52
10. Benveniste R, Bixler D, Conneally PM. Periodontal diseases in diabetics. *J Periodontol* 1967; 38: 271-279
11. Bender IB, Seltzer S. Roentgenographic and direct observation of experimental lesions in bone. I. *J Am Dent Assoc* 1961; 62: 152-160
12. Bender IB, Seltzer S. Roentgenographic and direct observation of experimental lesions in bone. II. *J Am Dent Assoc* 1961; 62: 708-716
13. Ramadan AE, Mitchell DF. A roentgenographic study of experimental bone destruction. *Oral Surg Oral Med Oral Pathol* 1962; 15: 934-942
14. Paul V, Trott JR. A radiological study of experimentally produced lesions in bone. *Dent Practitioner* 1966; 16: 254-258
15. Schwartz SF, Foster JK. Roentgenographic interpretation of experimentally produced lesions in bone. *Oral Surg Oral Med Oral Pathol* 1971; 32: 606-612
16. Socransky SS, Haffajee AD, Goodson JM, Lindhe J. New concepts of destructive periodontal disease. *J Clin Periodontol* 1984; 11: 21-32
17. Theilaid J. An evaluation of the reliability of radiographs in the measurement of bone loss in periodontal disease. *J Periodontol* 1960; 31: 143-153
18. Rawlinson A, Ellwood RP, Davies RM. An in-vitro evaluation of a dental subtraction radiography system using bone chips on dried human mandibles. *J Clin Periodontol* 1999; 26: 138-142
19. Rütteman UE, Okano T, Gröndahl HG, Gröndahl K, Webber RL. Exposure geometry and film contrast differences as bases for incomplete cancellation of interdental structures in dental subtraction radiography. *Proc SPIE* 1981; 314: 372-377
20. Webber RL, Rütteman UE, Gröndahl HG. X-ray image subtraction as a basis for the assessment of periodontal changes. *J Periodontol Res* 1982; 17: 509-511
21. Webber RL, Gröndahl HG, Gröndahl K. A digital subtraction technique for dental radiography. *Oral Surg Oral Med Oral Pathol* 1983; 55: 96-102
22. Reddy MS, Jeffcoat MK. Digital subtraction radiography. *Dent Clin North Am* 1993; 37: 553-565
23. Bragger U. Digital imaging in periodontal radiography. *J Clin Periodontol* 1988; 15: 551-557
24. Ortman LF, Dunford R, McHenry K, Hausmann E. Subtraction radiography and computer assisted densitometric analyses of standard radiographs. A comparison with <sup>125</sup>I absorptiometry. *J Periodont Res* 1985; 20: 644-651
25. Socransky SS, Gordon G, Goodson JM. Development of automated registration algorithms for subtraction radiography. *J Clin Periodontol* 1994; 21: 540-543
26. Gröndahl HG, Gröndahl K. Subtraction radiography for the diagnosis of periodontal lesions. *Oral Surg Oral Med Oral Pathol* 1983; 55: 208-213
27. Rüttemann UE, Webber R, Schimide E. A robust

- digital method for film contract correction in subtraction radiography. *J Periodont Res* 1985; 21: 486-495
28. McHenry K, Hausmann E, Wikesjo, Dunford R, Christersson L. Methodological aspects and quantitative adjuncts to computerized subtraction radiography. *J Periodont Res* 1987; 22: 125-132
  29. Jeffcoat MK, Reddy MS, Webber RL, Ruttimann UE. Extraoral control of geometry for digital subtraction radiography. *J Periodont Res* 1987; 22: 396-402
  30. Socransky SS, Duckworth JE, Goodson JM. A method for geometric and densitometric standardization of intraoral radiographs. *J Periodontol* 1983; 12: 435-440
  31. Ruttimann UE, Webber RL, Groenhuis RAJ. Computer correction of projective distortion in dental radiographs. *J Dent Res* 1984; 63: 1032-1036
  32. Wenzel A. Effect of manual compared with reference point superimposition on image quality in digital subtraction radiography. *Dentomaxillofac Radio* 1989; 18: 145-150
  33. Dunn SM, Van der Stelt PF, Ponce A, Fenesy K. A comparison of two registration techniques for digital subtraction radiography. *Dentomaxillofac Radio* 1993; 22: 77-80
  34. Webber RL, Gröndahl HG, Gröndahl K. Influence of variations in projection geometry on the detectability of periodontal bone lesions. *J Clin Periodontol* 1984; 11: 411-420
  35. Furkart J, Dove B. Direct digital radiography for the detection of periodontal bone lesions. *Oral Surg Oral Med Oral Pathol* 1992; 74: 652-660
  36. Wenzel A, Gröndahl HG. Direct digital radiography in the dental office. *Int Dent J* 1995; 45: 27-34
  37. Loe H, Silness J. Periodontal disease in pregnancy I. Prevalence and severity. *Acta Odontol Scand* 1963; 21: 533-551
  38. Loe H, Silness J. Periodontal disease in pregnancy II. Correlation between oral hygiene and periodontal disease. *Acta Odontol Scand* 1964; 22: 121-135
  39. Lindhe J. Textbook of Clinical Periodontology. Munksgaard, Copenhagen 1983a; pp 303-304. 1983b; p 394
  40. Oikarinen K. Tooth splinting : A review of the literature and consideration of the versatility of a wire-composite splint. *Endod Dent Traumatol* 1990; 6: 237-250
  41. Serio FG, Strassler HE. The effect of polishing pastes on composite resin surfaces; A SEM study. *J Periodontol* 1988; 59: 837-840
  42. Sjöström S, vanDijken JWK. The effect of glass ionomer cement and composite resin fillings on marginal gingiva. *J Clin Periodontol* 1991; 18: 200-203
  43. Goodson JM, Hogan PE. Clinical responses following periodontal treatment by local delivery. *J Periodontol* 1985; 56: 81-87
  44. Caton J, Polson A. Maintenance of healed periodontal pockets after a single episode of root planing. *J Periodontol* 1982; 53: 420-424
  45. Lang NP, Joss A, Orsanic T. Bleeding on probing : A predictor for progression on periodontal disease? *J Clin Periodontol* 1986; 13: 590-596
  46. Kegel W, Selipsky H. The effect of splinting on tooth mobility. I. During initial therapy. *J Clin Periodontol* 1979; 6: 45-58
  47. Renggli HH, Schweitzer H. Splinting of teeth with removable bridges-biologic effects. *J Clin Periodontol* 1974; 1: 43-46
  48. Renggli HH, Muhlemann HR. Tooth mobility, marginal periodontitis and malocclusion. *Parodontologie* 1970; 24: 39-48
  49. Renggli HH. Splinting of teeth-an objective



- assessment. *Helvetica Odontologica Acta* 1970; 15: 129-131
50. Rateitschak KH. The therapeutic effect of local treatment on periodontal disease assessed upon evaluation of different diagnostic criteria. 1. Changes in tooth mobility. *J Periodontol* 1963; 34: 540-544
51. Wenzel A, Warrer K, Karring T. Digital subtraction radiography in assessing bone changes in periodontal defects following guided tissue regeneration. *J Clin Periodontol* 1992; 19: 208-213
52. Kelly GH, Cain RJ, Knowles JW, Nissle RP, Burgett FG, Ramfjord SP. Radiographs in clinical periodontal trials. *J Periodontol* 1975; 46: 381-386
53. Isidor F, & Karring T. Long term effect of surgical and non-surgical periodontal treatment. A 5-year clinical study. *J Periodont Res* 1986; 21: 462-472
54. Renvert S, Badersten A, Nilveus R, & Egelberg J. Healing after treatment of periodontal intraosseous defects I. Comparative study of Clinical Method. *J Clin Periodontol* 1981; 8: 387-399
55. Hausmann E, Christersson L, Dunford R. Usefulness of subtraction radiography in the evaluation of periodontal therapy. *J Periodontol* 1985; 56: special issue, 4-8
56. Ohki M, Okaono T, Yamada N. A contrast-correction method for digital subtraction radiography. *J Periodont Res* 1988; 23: 277-280
57. Rudolph DJ, White SC, Mankovich NJ. Influence of geometric distortion and exposure parameters on sensitivity of digital subtraction radiography. *Oral Surg Oral Med Oral Pathol* 1987; 64: 631-637
58. Nyman SR, Lang NP. Tooth mobility and the biological rationale for splinting teeth. *Periodontol* 2000 1994; 4: 15-22
59. Nyman S, Lindhe J, Lundgren D. The role of occlusion for the stability of fixed bridges in patients with reduced periodontal tissue support. *J Clin Periodontol* 1975; 2: 53-66
60. Hirschfeld L, Wasserman B. A Long term survey of tooth loss in 600 treated periodontal patients. *J Periodontol* 1978; 49: 225-237
61. Pollack RP. An analysis of periodontal therapy for the 65-year-old and older patient. *Gerodontology* 1986; 2: 135-137
62. Marvin S, Jack L, Thaller J. Temporary splinting for multiple mobile teeth. *Amer Dent Assoc* 1956; 53: 429-433
63. Howard L, Lawrence A, Weinberg. An evaluation of periodontal splinting. *J Am Dent Assoc* 1961; 63: 49-54
64. Curtis M, Becker, David A, Kaiser, Wayne B, Kaldahl. The Evolution of Temporary Fixed Splints-The A-Splint *Int J Periodont Rest Dent* 1998; 18: 277-285
65. Kessler M, Mattheew K. A Variation of the A splint. *J Periodontol* 1970; 41: 268-271
66. Howard E, Strassler, Alireza Haeri, Jerrold P, Gultz. New-generation Bonded Reinforcing Materials for Anterior Periodontal Tooth Stabilization and Splinting. *Dent Clin North Am* 1999; 43: 105-126
67. Waerhaug J. Justification for splinting in periodontal therapy. *J Prosthetic Dent* 1969; 22: 201-208
68. Selipsky, H. Osseous surgery-How much need we compromise? *Dent Clin North Am* 1976; 20: 79-106

## 치근활택술과 스프린트 병행처치의 효과에 관한 연구 : 디지털 공제 촬영술을 이용한 임상적 연구

이지영, 계승범, 김원정, 이용무, 구영, 류인철, 정종평, 최상묵, 한수부

서울대학교 치과대학 치주과학 교실

스프린트는 치주치료에서 부가적 처치법으로 널리 사용되고 있으며, 한편, 디지털 공제 촬영술은 기존방사선촬영술의 한계점을 극복하기 위해 개발된 새로운 방법이다. 이번 연구에서는 치근활택술 단독시행시와 스프린트 병행처치시의 효과를 임상적, 방사선학적으로 비교하였다. 중증도의 성인성 치주염을 가진 20명의 환자를 대상으로 하되 10명은 치근활택술 단독으로, 나머지 10명은 스프린트 병행처치로 처치하였다.

임상적, 방사선학적인 평가는 처치전, 처치후 6개월에 행하고, 임상적 평가의 경우 3개월에 추가로 실시하였다. 이번 연구에서 사용된 임상지수로는 치태지수, 치은지수, 치은퇴축, 치주낭깊이, 임상부착수준, 임상부착증가, 탐침시출혈, 치아동요도 등이며, 방사선학적 평가는 기존 방사선촬영술에 의한 방법과 디지털 공제 촬영술에 의한 방법으로 행하였다. 디지털 공제 촬영술에 의한 평가시, 영상은 Digora 프로그램에 의해 획득하고 Emago 프로그램으로 처리하여 다음과 같은 결론을 얻었다.

1. 처치후 3개월에 치태지수, 치은지수, 치은퇴축, 치주낭깊이, 임상적부착수준, 탐침시출혈 등의 임상지수들이 변했으며, 특히 이러한 변화는 치주낭깊이, 치은퇴축, 탐침시출혈에서 유의성이 있었다. ( $p<0.05$ ) 그러나 두 군간 차이는 인정되지 않았다. ( $p>0.05$ )
2. 처치후 6개월에도 치태지수, 치은지수, 치은퇴축, 치주낭깊이, 임상적부착수준, 탐침시출혈, 치아동요도 등의 임상지수들이 변했으며, 특히 이러한 변화는 치주낭깊이, 치은퇴축, 탐침시출혈, 치태지수, 치아동요도에서 유의성이 있었다. ( $p<0.05$ ) 그러나 두 군간 차이는 인정되지 않았다. ( $p>0.05$ )
3. 켄달 상관분석시, 임상적 평가와 기존 방사선 촬영술에 의한 평가사이의 관련성은 낮았으며 거의 0에 가까운 수치를 보였으며 ( $r=0.110, p=0.639$ ) 임상적 평가와 디지털 공제 방사선 촬영술에 의한 평가사이에서 약간 높은 관련성을 보였다. ( $r=0.257, p=0.315$ ) 즉 치주치료후의 골변화는 디지털 공제 방사선 촬영술에 의한 평가시 기존 방사선 사진보다 임상적 부착 증가와 더욱 긴밀한 관련성을 보여준다.

이상의 결과로 볼 때, 스프린팅 처치는 치주 치료에 있어 치근활택술에 부가적 효과를 제공하지 못한다.

