

## Idiopathic Spinal Cord Herniation as a Treatable Cause of Progressive Brown-Sequard Syndrome

Jeong-Min Kim, M.D., Se Ho Oh, M.D., Ki-Jeong Kim, M.D.<sup>a</sup>,  
Seong-Ho Park, M.D., Kyung Seok Park, M.D.

Departments of Neurology and <sup>a</sup>Neurosurgery, College of Medicine, Seoul National University, Seoul, Korea

Idiopathic spinal cord herniation is a rare spinal cord disorder caused by spinal cord prolapse through a dural defect. It is a curable disease, so early detection is of particular importance. We report a 38-year-old woman with Brown-Sequard syndrome which was caused by the thoracic spinal cord herniation. Her weakness was almost completely resolved after surgical management, which emphasizes the importance of early diagnosis and surgical management in this rare disease entity.

*J Clin Neurol* 3(4):204-207, 2007

**Key Words :** Idiopathic spinal cord herniation, Brown-Sequard syndrome, Treatment, Surgery

Idiopathic spinal cord herniation (ISCH) is defined as the prolapse of the spinal cord through its dural sleeve, usually at the thoracic level, resulting various neurological manifestations.<sup>1</sup> Since it was initially described in 1974,<sup>2</sup> about 80 cases have been reported.<sup>3</sup> It is a rare disease, but early diagnosis is particularly important since it is potentially curable by surgical management. We report a woman who presented with Brown-Sequard syndrome, which was caused by ISCH. After surgical management her symptoms recovered significantly.

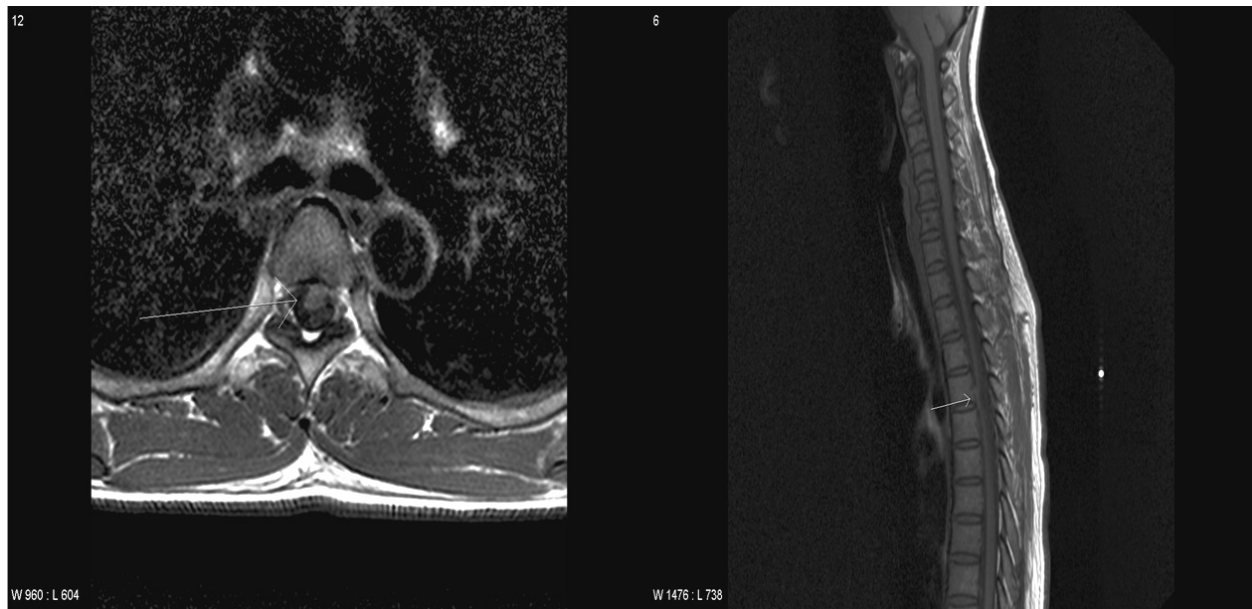
### CASE REPORT

A 38-year-old woman visited our hospital complaining of progressive hypesthesia in the right lower limb and weakness in the left lower limb. She had noticed decreased sensation in the right lower limb 3 years

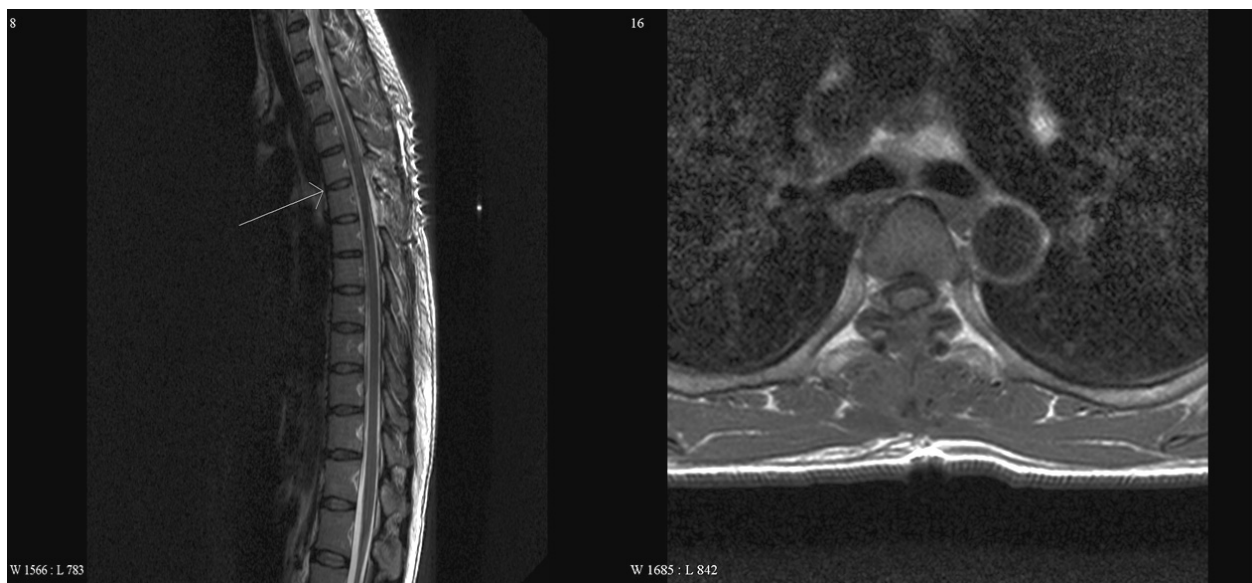previously when she took a hot bath, and had felt motor weakness in the left lower limb on walking or climbing 3 months previously. These symptoms progressed slowly so she visited our hospital. She denied difficulty in urination or defecation. She had no trauma, surgery history, or previous medical history such as diabetes, hypertension, tuberculosis, or hepatitis.

On neurological examination, she was alert and well-oriented. Cranial nerve examination revealed no abnormality. On motor power examination, both upper extremities were intact, but her left lower extremity showed weakness measured grade IV+ on the Medical Research Council (MRC) scale. Her left knee and ankle jerks were increased as grade 3+ compared with the right side, but Babinski reflex was not present. Sensory examination disclosed a decreased sensation in her right side for pinprick and temperature below the 5<sup>th</sup> thoracic dermatome, but her position, vibration, and tactile sensations were

Received : August 9, 2007 / Accepted : November 29, 2007 / Address for correspondence : Kyung Seok Park, M.D., Ph.D.  
Department of Neurology, Seoul National University Bundang Hospital, 300 Gumi-dong, Bundang-gu, Seongnam-si, Gyeonggi-do, 463-707, Korea  
Tel: +82-31-787-7469, Fax: +82-31-718-9327, E-mail: pks1126@chol.com



**Figure 1.** Initial cervicothoracic spine MRI showing anterior displacement of spinal cord at the level of the T4-5 disc (arrows).



**Figure 2.** Spine MRI performed 3 days after surgery showing restored spinal cord contour at the level of the T4-5 disc (arrow).

symmetric and intact on both sides. Anal tone was preserved. Cerebellar function test was unremarkable. She showed a mild limping gait in the left side, and her neck was supple.

With an impression of a lesion involving the cervicothoracic hemi-spinal cord, we performed imaging studies. Thoracic spinal X-ray series were unremarkable. Thoracic spinal MRI with enhancement revealed

anterior displacement of the spinal cord at the level of the T4-5 intervertebral disc (Fig. 1). There was no mass lesion or congenital abnormality involving the spinal cord or column. With an impression of spinal cord herniation, surgical management was performed. During the operation, ovoid shaped ventral dural defect was confirmed in the left paracentral area and spinal cord was herniated through it. After restoring

the herniated spinal cord, the dural defect was patched with a synthetic dural substitute. Postoperative spinal MRI showed a revised dural alignment and spinal cord contour without unusual finding (Fig. 2). She was discharged without postoperative complications, and her weakness and hypesthesia were almost completely resolved at the 6-month follow-up.

## DISCUSSION

Our patient had ISCH which manifested as Brown-Sequard syndrome. The absence of the position and vibration sensation impairments suggested that the posterior column of the spinal cord was not involved, but the other findings were consistent with typical Brown-Sequard syndrome. She had no history of trauma, and spinal MRI revealed no combined structural abnormalities that could potentially induce a dural tear. She was recovered significantly after appropriate surgical management.

The most common clinical presentation of ISCH is Brown-Sequard syndrome, but spastic paraparesis and monoparesis have also been reported depending on the extent of the involved spinal cord.<sup>4</sup> The thoracic segment is most commonly affected. Since the symptoms are commonly progressive and the outcome is usually good after surgical management,<sup>3</sup> an early diagnosis is of particular importance. The symptoms can also evolve in a stepwise manner.<sup>3</sup> The pathogenesis has not been clearly established yet, and there have been several hypotheses to explain the nature of dural defect. An intradural arachnoid cyst or herniated disc may increase pressure and dural erosion, resulting dural tear and cord herniation.<sup>4</sup> However, contrast myelographic studies did not show a block or evidence of raised pressure.<sup>1</sup> Some authors postulated the presence of a congenital structural anomaly, such as duplicated dura mater or disturbance of dural texture.<sup>4</sup> Pulsation of cerebrospinal fluid (CSF) caused by cardiac or respiratory intrathoracic pressure fluctuation may cause adhesion and dural leak, causing dural defect.<sup>4</sup> The diagnosis in a suspected patient is now easy with MRI, which

shows ventral displacement of the spinal cord. Spinal cord may show atrophic change with decreased size and rarely signal changes. Postoperative MRI is performed to confirm realignment of the spinal cord and signal recovery. Somatosensory evoked potential and myelo-CT have been used as additional diagnostic procedures. The surgery is generally approached via a posterior laminectomy, although in some cases an anterior approach is adopted.<sup>3</sup> The aim of surgery is to replace the herniated spinal cord and repair the dural defect to avoid relapse. The prognosis is generally good for early surgical treatment, but treatment delay can prevent recovery in some patients.<sup>3</sup> Since the surgical management deals with dural alignment, CSF leakage or collection may happen, causing positional headache or the formation of a CSF collection sac. No definitive prognostic factor has been proposed, but initial paraparesis appears to be related to a poor response to surgical treatment.<sup>3</sup>

To date, there have been two case reports of ISCH in Korea.<sup>5,6</sup> The first<sup>5</sup> was a 42-year-old man with a 2-year history of Brown-Sequard syndrome, in whom the neurological deficits recovered slowly over 9 months following surgical management. The other patient<sup>6</sup> was a 55-year-old woman who also presented with a 3-month history of Brown-Sequard syndrome. No surgical management was performed, and hence a definite diagnosis could not be confirmed in that case. The motor weakness gradually recovered, but the sensory deficit was not changed. There was no combined structural abnormality such as arachnoid cyst or duplicated dura that could be regarded as a potential cause of spinal cord herniation in either case. In our patient, weakness and hypesthesia were significantly improved after surgical management, which emphasizes the importance of early diagnosis and surgical intervention. Further studies are needed to disclose the underlying pathomechanism and prognostic factors of ISCH.

In conclusion, since ISCH is treatable, it should always be included in the potential causes of myelopathy especially when a patient presents with Brown-Sequard syndrome.

## REFERENCES

1. Massicotte EM, Montanera W, Ross Fleming JF, Tucker WS, Willinsky R, TerBrugge K, et al. Idiopathic spinal cord herniation: report of eight cases and review of the literature. *Spine* 2002;27:233-241.
2. Wortzman G, Tasjer RR, Rewcastle NB, Richardson JC, Pearson FG. Spontaneous incarcerated herniation of the spinal cord into a vertebral body: a unique cause of paraplegia. Case report. *J Neurosurg* 1974;41:631-635.
3. Maira G, Denaro L, Doglietto F, Mangiola A, Colosimo C. Idiopathic spinal cord herniation: diagnostic, surgical, and follow-up data obtained in five cases. *J Neurosurg Spine* 2006;4:10-19.
4. Ellger T, Schul C, Heindel W, Evers S, Ringelstein EB. Idiopathic spinal cord herniation causing progressive Brown-Sequard syndrome. *Clin Neurol Neurosurg* 2006; 108:388-391.
5. Kim YJ, Kim YS, Kim JH, Joong HO, Ko YY, Oh SH, et al. Spontaneous thoracic spinal cord herniation. *J Korean Neurosurg Soc* 2001;30:1237-1240.
6. Heo SH, Kim JH, Ahn TB, Kim EJ, Park KC, Yoon SS, et al. A case suggesting spontaneous spinal cord herniation presented as Brown-Sequard syndrome. *J Korean Neurol Assoc* 2007;25:133-135.