

CASE REPORT

A Case of Cutaneous Horn Originating from Keratoacanthoma

Jung Hoon Yang, M.D., Dae Hyun Kim, M.D., Jong Suk Lee, M.D., Moon Kyun Cho, M.D., Sang Hoon Lee, M.D., Sung Yul Lee, M.D., Hyun Deuk Cho, M.D.¹

Departments of Dermatology and ¹Pathology, Soonchunhyang University College of Medicine, Cheonan, Korea

Cutaneous horn is the clinical description of a hyperproliferation of compact keratin in response to a wide array of underlying benign and malignant pathologic changes. We report here on a case of cutaneous horn that originated from keratoacanthoma in a 76-year-old woman. Grossly, a 2.5 × 0.7 cm sized yellow-white colored scaly fungating mass from an erythematous nodule was observed on the right temporal area. Histopathologically, it was reported as keratoacanthoma with cutaneous horn. The lesion was totally excised after the diagnosis. (*Ann Dermatol* 23(1) 89~91, 2011)

-Keywords-

Cutaneous horn, Keratoacanthoma

INTRODUCTION

A cutaneous horn (cornu cutaneum) is a relatively rare epidermal tumor that generally appears as a conical projection of hyperkeratotic epidermis. It is named after horns of other animal species because of its gross resemblance. In dermatology, "horn" is the clinical term for a circumscribed, conical, markedly hyperkeratotic lesion in which the height of the keratotic mass amounts to at least half of its largest diameter¹. Cutaneous horns may arise from any part of the body, and 30% arise from the face and scalp². They are thought to result from underlying benign, premalignant or malignant pathologic lesion.

Received November 2, 2009, Revised April 26, 2010, Accepted for publication April 28, 2010

Corresponding author: Sung Yul Lee, M.D., Department of Dermatology, Soonchunhyang University College of Medicine, 23-20 Bongmyung-dong, Cheonan 330-721, Korea. Tel: 82-41-570-2270, Fax: 82-41-578-2270, E-mail: dermsung@schmc.ac.kr

We report here on a case of a cutaneous horn originating from keratoacanthoma in a 76-year-old Korean woman.

CASE REPORT

A 76-year-old female patient presented with a club-shaped fungating mass growing from her right temple area. She had recognized a small erythematous exophytic mass 3 years previously, and the mass remained unchanged until 3 months prior to this visit. Since then it had grown rapidly, but there was no associated pain, pruritus or bleeding.

On physical examination, she had a 3 × 3 cm area of an erythematous patch with a central 1 × 1 cm sized hypertrophic nodule on her right temple. A yellowish-white colored cylindrical horn with a base diameter of 0.7 cm and a height of 2.7 cm arose from the central nodule (Fig.

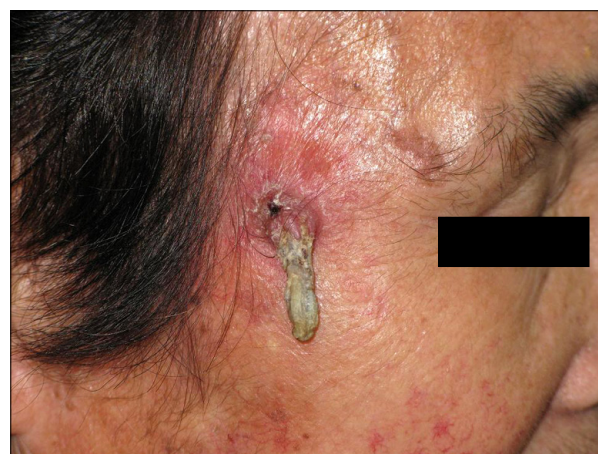

Fig. 1. A 3 × 3 cm sized erythematous patch with a central 1 × 1 cm sized hypertrophic nodule on the right temple. A yellowish-white colored cylindrical horn with a base diameter of 0.7 cm and a height of 2.7 cm arose from the central nodule.

1). The patient had no other specific findings. A central crater-like keratin plug surround by epidermis was found on the histologic findings. The lesion was well demarcated from the dermis and it has an eosinophilic glassy appearance as a consequence of keratinization. Exceedingly thick hyperkeratosis and parakeratosis were observed above the epidermis. An infiltration of inflammatory cells was seen in the dermis (Fig. 2, 3). Based on the clinical and pathologic findings, we diagnosed this lesion as a cutaneous horn originating from keratoacanthoma, and the lesion was totally excised. Up to the present date, she is in good physical health without recurrence.

DISCUSSION

Cutaneous horn is a clinical term denoting distinctive, highly confined, protruding firm projections on the skin surface. Many old medical texts in the Middle Ages described cutaneous horn as a marker of a witch³.

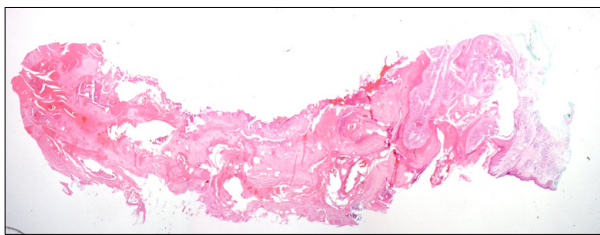


Fig. 2. Lesion of the cutaneous horn. This was a 2.7×0.7 cm sized hyperkeratotic mass with focal keratin pearl (H&E, ×10).

Cutaneous horns are of various shapes and they range from 2~60 mm in size. The color is usually skin-colored or erythematous and it may present as white when finely scaled. Cutaneous horn can be related to many underlying diseases, including actinic keratosis, verruca vulgaris, seborrheic keratosis, trichilemmoma, squamous cell carcinoma and melanoma^{4,5}. On rare occasion it can be accompanied with keratoacanthoma. One such case has been previously reported in Korea⁶. Generally, one-half of cutaneous horns arise from benign lesions and 16% to 20% arise from definitely malignant lesions, but most of them arise from actinic keratosis^{2,5}. In Korea, about 80% of such cases arise from benign lesions, and mostly from viral warts. Fifteen percent of the cases arise from premalignant lesion and 5% arise from malignant lesion⁷. Cutaneous horns rising from premalignant or malignant lesions signify the importance of a thorough histological examination.

The pathogenesis of cutaneous horn is not yet clear. It is thought continuous stimulus may affect the formation of a cutaneous horn. Old age and abundant blood vessels at the base are also associated with cutaneous horn^{4,8}.

The diagnosis of cutaneous horn can be clinically settled when the height of the keratotic mass amounts to at least half of its largest diameter¹.

The treatment and prognosis of cutaneous horn entirely depend on its base lesion, and for the most part cutaneous horn is totally excised for cosmetic reasons.

Keratoacanthoma is a relative common epithelial tumor. It grows rapidly and reaches a maximum size around 10 to 12 weeks after which it forms a crateriform ulcer⁹. It

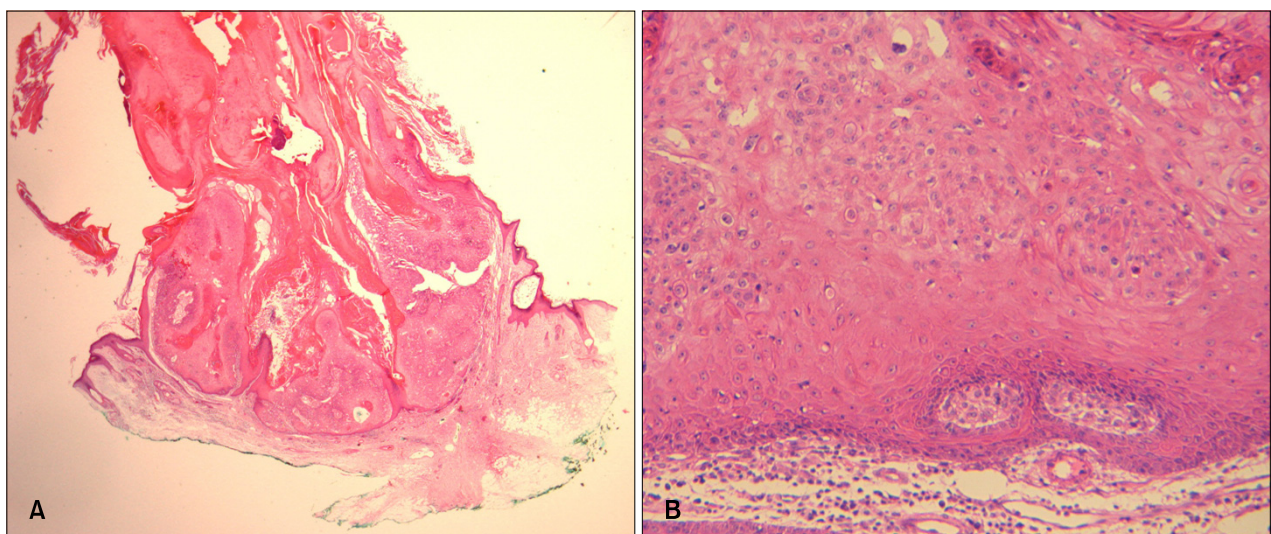


Fig. 3. Lesion of keratoacanthoma. (A) Note the central hyperkeratotic plug with surrounding epidermis. (B) The lesion is well demarcated and it does not extend downward. In the center, an eosinophilic glassy appearance is seen as a consequence of keratinization (A: H&E, ×40, B: H&E, ×100).

generally originates as a solitary lesion and it usually forms on the face, forearm and dorsum of the hand, which are the most sun-exposed areas. Demographically, it occurs 2 to 3 times more often in men and its incidence peaks at the ages of 50 to 69 years old¹⁰.

This lesion starts with rapidly enlarging firm erythematous papules with smooth surfaces. In the mature stage, the central keratotic core is formed and then falls off naturally after which a crateriform ulcer occurs. The crateriform ulcer disappears spontaneously leaving a flat hypopigmented scar. Pathologically, the mature lesion exhibits epithelial proliferation with atypical keratinocytes and mitoses, along with a central keratotic plug.

Keratoacanthoma usually heals spontaneously leaving a scar, but rapidly growing lesions can cause wide destruction of tissue. For example, a case was presented in which a giant keratoacanthoma destroyed a patient's entire nose¹¹. Since there can be such consequences, complete surgical excision is recommended for most cases. Imiquimod has been reported to be effective in some cases¹².

Our patient had a typically shaped cutaneous horn and on the histologic findings, the base of the horn showed the characteristic histologic features of keratoacanthoma. Clinically, most case of keratoacanthoma regresses spontaneously within one year. But like our patient, a few cases have been reported to remain without regression even one year after occurrence¹³⁻¹⁵. Such cases in which the base is keratoacanthoma are rare, and only 1 such case was previously reported in Korea by Hwang et al.⁶. So, we report here on an unusual case of a cutaneous horn that originated from the keratoacanthoma of a 76-year-old female patient.

REFERENCES

1. Bart RS, Andrade R, Kopf AW. Cutaneous horns. A clinical and histopathologic study. *Acta Derm Venereol* 1968;48: 507-515.
2. Yu RC, Pryce DW, Macfarlane AW, Stewart TW. A histopathological study of 643 cutaneous horns. *Br J Dermatol* 1991;124:449-452.
3. Gould GM, Pyle WL. Anomalies and curiosities in medicine. 1st ed. Philadelphia: W.B. Saunders, 1897:225.
4. Bart RS. Cutaneous horns. In: Andrade R, Gumport SL, Popkin GL, Rees TD, editors. *Cancer of the skin: biology-diagnosis-management*. 1st ed. Philadelphia: Saunders, 1976:557-572.
5. Schosser RH, Hodge SJ, Gaba CR, Owen LG. Cutaneous horns: a histopathologic study. *South Med J* 1979;72:1129-1131.
6. Hwang JY, Jeon HD, Lee SY, Lee JS, Chung H, Whang KU. Cutaneous horn arising from keratoacanthoma. *Korean J Dermatol* 1998;36:959-961.
7. Kim YJ, Oh ST, Kang H, Park CJ, Park YM, Cho SH, et al. Clinicopathologic study of cutaneous horns. *Korean J Dermatol* 2005;43:359-365.
8. Taylor JA. Penile horn. *Trans Am Assoc Genitourin Surg* 1945;37:101-108.
9. Koh HK, Bhawan J. Tumor of the skin. In: Moschella SL, Hurley HJ, editors. *Dermatology*. 3rd ed. Philadelphia: WB Saunders, 1992:1728-1729.
10. Kingman J, Callen JP. Keratoacanthoma. A clinical study. *Arch Dermatol* 1984;120:736-740.
11. Rapaport J. Giant keratoacanthoma of the nose. *Arch Dermatol* 1975;111:73-75.
12. Ko NY, Park JH, Son SW, Kim IH. Treatment of keratoacanthoma with 5% imiquimod cream. *Ann Dermatol* 2006; 18:14-17.
13. Schwartz RA. Keratoacanthoma. *J Am Acad Dermatol* 1994; 30:1-19.
14. Griffiths RW. Keratoacanthoma observed. *Br J Plast Surg* 2004;57:485-501.
15. Jasnoch V, Ernst K, Hundeiker M. Rare keratoacanthoma variants. *Hautarzt* 1995;46:244-249.