

Lichen Striatus in a Girl: Successful Treatment with Pimecrolimus

Sang-Young Park, M.D.¹, Seung-Hun Lee, M.D.¹, Tae-Jin Yoon, M.D.^{1,2}

¹Department of Dermatology and ²Institute of Health Science,
School of Medicine, Gyeongsang National University, Jinju, Korea

Lichen striatus (LS) is a self-resolving condition, which may occasionally need treatment for significant pruritus, a persistent course or cosmetic problems. The options for treatment have usually been topical or intralesional corticosteroids, salicylic acid, coal tar, or more recently, topical tacrolimus and pimecrolimus.

We report a case of LS successfully treated with pimecrolimus in a 15-year-old girl. (Ann Dermatol (Seoul) 19(4) 157~159, 2007)

Key Words: Lichen striatus, Pimecrolimus

INTRODUCTION

Lichen striatus (LS) is an uncommon disorder that manifests as continuous or interrupted erythematous papules showing a unilateral pattern and linearity corresponding to Blaschko lines. LS mainly occur in children from 5 to 15 years of age. The eruption is usually asymptomatic and spontaneously recovers within 3-6 months in most cases, but often leaves hypopigmentation especially in dark-skinned patients¹. Although the etiology of LS has not been exactly determined, it has been reported that LS is a T-cell mediated inflammatory skin disease associated with autoimmune response to mutated keratinocytic cloning^{2,3}. Pimecrolimus is an ascomycin derivative, which is a new class of immunomodulating macrolactams. The acting mechanism of pimecrolimus is the blockage of T-cell activation^{4,5}.

We, herein, report a case of a 15-year-old girl with lichen striatus who was successfully treated with topical pimecrolimus.

CASE REPORT

A 15-year-old girl presented with a 2-month history of an itchy eruption with a linear arrangement from the dorsolateral side of the left foot to the posterior aspect of the left thigh. She had no relevant medical history or laboratory tests. The lesion was a band-like, interrupted, slightly-erythematous plaque, which extended the entire length of the left leg along the lines of Blaschko (Fig. 1A). A skin biopsy was taken from papules with erythema on the left calf area. Histopathologic findings showed a focal, band-like lymphocytic infiltration in the papillary dermis and reticular dermis around the deep follicles and sweat glands (Fig. 2A). Focal parakeratosis, relatively irregular acanthosis, mild intercellular edema with exocytosis, and scattered dyskeratotic cells were observed in the epidermis (Fig. 2B). The linear eruption was diagnosed as lichen striatus based on both clinical and histological features.

The pruritus had been moderate and unresponsive to antihistamines. Because of the possibility of steroid atrophy, the patient was instructed to apply 1% pimecrolimus cream (Elidel[®], Novartis Pharma, Basel, Switzerland) once daily. The pruritus began to improve after 1 week and completely disappeared within 3 weeks (Fig. 1B). She had no complaints of any burning sensation during the treatment period. There has been no recurrence for 11 months.

Received March 4, 2007

Accepted for publication May 18, 2007

Reprint request to: Tae Jin Yoon, M.D., Department of Dermatology, Gyeongsang National University, 90 Chilam-dong, Jinju, Gyeongnam 660-702, Korea. Tel: 82-55-750-8183, Fax: 82-55-758-8106, Cell: 016-9705-9533, E-mail: yoontj@gnu.ac.kr

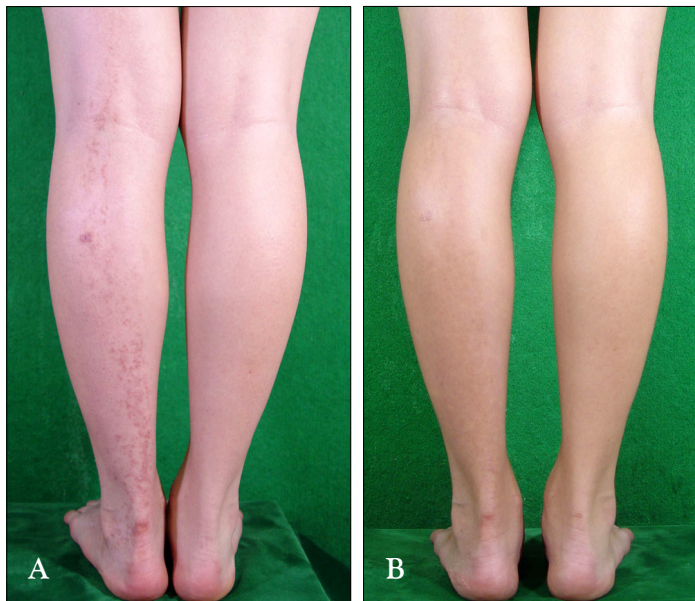


Fig. 1. (A) Clinical appearance of the patient with lichen striatus at presentation. (B) Clearance of the lesions after 3 weeks of treatment with topical pimecrolimus.

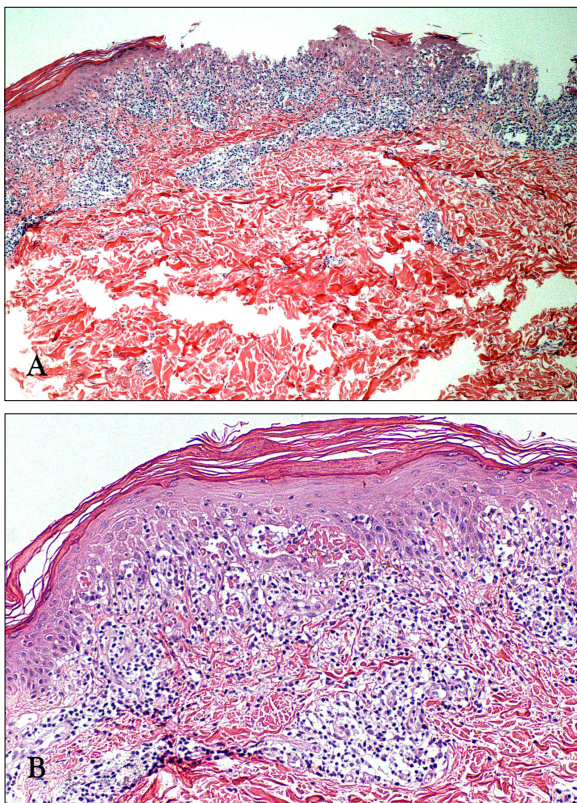


Fig. 2. (A) Diffuse inflammatory cell infiltration in the epidermis and focal lymphocytic infiltration in the dermis (H&E, $\times 40$). (B) Focal parakeratosis, relatively irregular acanthosis, mild intercellular edema with exocytosis, and scattered dyskeratotic cells were observed in the epidermis (H&E, $\times 100$).

DISCUSSION

Lichen striatus (LS) occurs at any age, and presents most often (above 50% of cases) in children aged between 5 and 15 years. At first, small, pink, lichenoid, and discrete papules appear and coalesce rapidly, and then extend to form a dull red, slightly-scaly, linear band between 2 mm to 2 cm in width^{1,6}. The lesions, usually linear and unilateral, develop most commonly on the arms and legs, or on the neck, but may also develop on the trunk⁷. The linearity has been shown to correspond to Blaschko lines. The histological features are diverse and some are nonspecific, but it has recently been reported that one of the remarkable features of LS is the presence of an inflammatory infiltrate in the reticular dermis around hair follicles and eccrine glands².

Lichen striatus (LS) is a self-resolving condition, which may occasionally need treatment for significant pruritus, a persistent course or cosmetic problems. The options for treatment usually include topical or intralesional corticosteroids, salicylic acid or coal tar. Although the cause of LS is uncertain, it has been reported that LS is a T-cell mediated inflammatory skin disease associated with autoimmune response to mutated keratinocytic cloning^{2,3}. Accordingly, topical tacrolimus⁷ and pimecrolimus⁴ have been highlighted as the new treatment for LS. The effects of these treatments have recently been

reported in the Korean literature.

Pimecrolimus, an ascomycin derivative, is one of the new classes of immuno-modulating macrolactams and is being developed for the special treatment of inflammatory skin diseases. The acting mechanism of pimecrolimus is the blockage of T-cell activation. It may specifically inhibit the synthesis of inflammatory cytokines such as Th1- and Th2-type cytokines. Thus, it prevents the local activation of T-lymphocytes and both immune and inflammatory response⁵. The eruption is usually asymptomatic and recovers spontaneously within 3-6 months in most cases, but often leaves hypopigmentation especially in dark-skinned patients¹. In our case, complications of hypopigmentation or residual lesions were not nearly observed.

In our experience, 1% pimecrolimus cream is a beneficial and efficacious treatment option for lichen striatus in children because it carries no risk for skin atrophy compared with topical corticosteroid application.

REFERENCES

1. Reed RJ, Meek T, Ichinose H. Lichen striatus: a model for the histologic spectrum of lichenoid reactions. *J Cutan Pathol* 1975;2:1-18.
2. Gianotti R, Restano L, Grimalt R, Berti E, Alsessi E, Caputo R. Lichen striatus – a chameleon: an histopathological and immunohistological study of forty-one cases. *J Cutan Pathol* 1995;22:18-22.
3. Zhang Y, McNutt NS. Lichen striatus. Histological, immunohistochemical, and ultrastructural study of 37 cases. *J Cutan Pathol* 2001;28:65-71.
4. Kus S, Ince U. Lichen striatus in an adult patient treated with pimecrolimus. *J Eur Acad Dermatol Venereol* 2006;20:360-361.
5. Gupta AK, Chow M. Pimecrolimus: a review. *J Eur Acad Dermatol Venereol* 2003;17:493-503.
6. Toda K, Okamoto H, Horio T. Lichen striaus. *Int J Dermatol* 1986;25:584-585.
7. Fujimoto N, Tajima S, Ishibashi A. Facial lichen striatus: successful treatment with tacrolimus ointment. *Br J Dermatol* 2003;148:587-590.