

The Treatment of Cutaneous T-cell Lymphoma with Triple Combination of Interferon alfa, Retinoid, and Photochemotherapy

Jeong Deuk Lee, M.D., Ji Sun Lee, M.D., Sang Hyun Cho, M.D., Chi Hwa Han, M.D.*

Departments of Dermatology & Internal Medicine, College of Medicine,
The Catholic University of Korea, Seoul, Korea*

Cutaneous T-cell lymphoma(CTCL) is a rare cutaneous malignant disease and is typically a disease of older adults. There is no optimal treatment for CTCL, which ranges from topical steroid to systemic chemotherapy. Hence until curative therapy is found, therapies that keep CTCL in check and prevent progression to more advanced lymphoma may be desirable alternatives and may preserve quality of life. Herein we report our experience in treating a stage IIB CTCL patient with triple combination of interferon alfa, oral retinoid, and psoralen plus UVA(PUVA) therapy. (*Ann Dermatol* 16(1) 39~41, 2004)

Key Words: Cutaneous T cell lymphoma, Interferon alfa, PUVA, Retinoid

INTRODUCTION

Cutaneous T-cell lymphoma (CTCL) is a cutaneous malignant disease, which typically occurs in older adults. There are a few principles that help guide therapy strategies. Although excellent long-term results have been reported with the localized therapy of localized disease, more widespread disease requires total skin or systemic therapy. We report a case of cutaneous T-cell lymphoma which was treated with triple combination of interferon alfa, oral retinoid, and psoralen plus UVA (PUVA) therapy in order to achieve increased remission rate.

CASE REPORT

A 73-year-old man presented with multiple,

erythematous papules and nodules on the face (Fig. 1). Multiple erythematous papules clustered to form confluent plaque on the temple area and was scattered over the nose and cheeks. Histopathological examination of both a nodule on the temple and a papule on the cheek showed a dense and diffuse lymphocytic infiltrate without epidermotrophism that extended deeply into the dermis, with focal penetration into the subcutaneous fat (Fig. 2). The infiltrate was composed of sheets of cells with hyperchromatic nuclei, prominent nucleoli, and

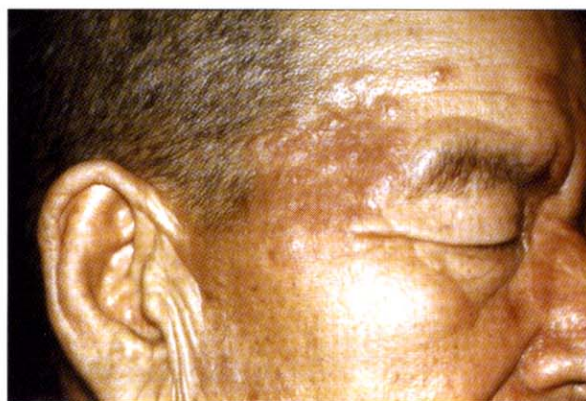

Fig. 1. Multiple erythematous papules and nodules on the temporal area.

Received September 5, 2003

Accepted for publication January 6, 2004

Reprint request to: Sang Hyun Cho, M.D., Department of Dermatology, Our Lady of Mercy Hospital, The Catholic University of Korea, #665 Bupyung-dong, Bupyung-gu, Incheon 403-720, Korea
Tel. 82-32-510-5528, Fax: 82-32-510-5827
E-mail. drchosh@hotmail.com

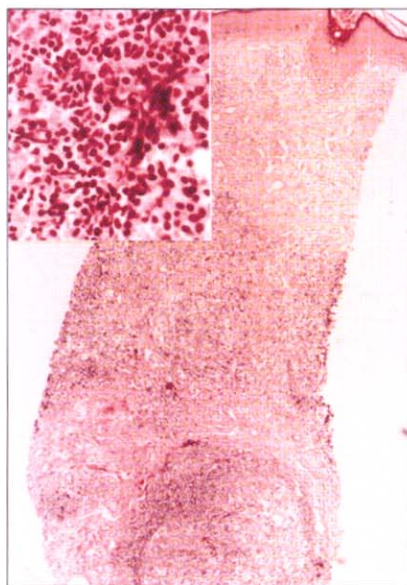


Fig. 2. Histopathological finding from the temporal area showed a dense and diffuse lymphocytic infiltrate that extended deeply into the dermis, with focal penetration into the subcutaneous fat (H&E, $\times 40$). Dense infiltrate mainly composed of small to medium sized atypical lymphocytes (inset, H&E, $\times 200$).

frequent mitotic figures. Immunohistochemical stains demonstrated that these lymphocytes were positive for the CD3, CD4, and CD45RO antigens. A work-up that included peripheral blood smears, and whole-body computed tomographic scans did not show any evidence of involvement of peripheral blood or internal organs. Cutaneous T-cell lymphoma stage IIB was diagnosed and the triple combination therapy of interferon alfa, oral etretinate, and psoralen plus UVA (PUVA) therapy was initiated. Our patient was started on a regimen of 30 mg/day of oral etretinate with 3 times-weekly course of PUVA therapy and 3 million U of interferon alfa administered subcutaneously 3 times per week. After 10 weeks of this treatment, marked regression of the nodular lesions on the face and the absence of the development of new lesions was observed (Fig. 3). And histopathological examination at this point showed the reduction of atypical lymphocytic infiltrates despite residual tumor. Thereafter our patient received maintenance therapy with interferon alfa and oral etretinate. This treatment is well tolerated without severe side effects and the disease did not recur for 4 months

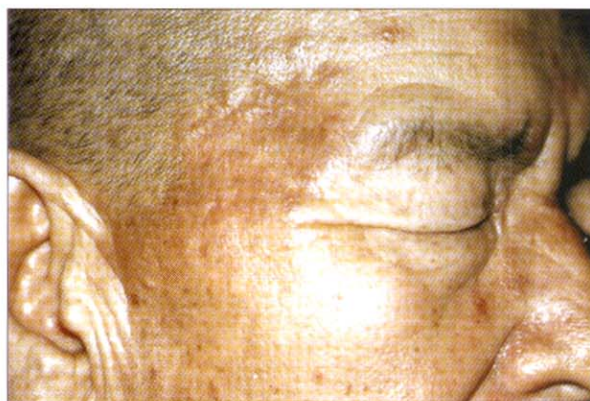

Fig. 3. Partial remission of papular eruptions and nodular lesions of the temporal area at 10 weeks after triple combined therapy.

of follow-up period.

DISCUSSION

Cutaneous T-cell lymphoma (CTCL) is a rare cutaneous malignant disease and is typically disease of older adults, with a median age at diagnosis 55 years¹. Prevalence also rises sharply with advancing age². The course of the disease is usually indolent, progressing through various phases over many years. There is no optimal treatment for CTCL, which ranges from topical steroid to systemic chemotherapy. Hence until curative therapy is found, therapies that keep CTCL in check and prevent progression to more advanced lymphoma may be desirable alternatives and may preserve quality of life. Because the median survival of patients with more advanced disease (stage III to IV) is relatively short, they should receive a more intensive regimen. However, interferon alfa in combination with PUVA or retinoids can be repeated to be effective for advanced or refractory CTCL³. Combined interferon and PUVA therapy has achieved remission with high response rates⁴. Interferon alfa and systemic retinoid combination therapy has also shown activity in CTCL⁵. The previous study showed that the response rate was 65% in patients with stage I to II disease and 27% in patients with stage III to IV disease⁵. Most of these responses were partial remissions with only 11% complete remissions. To increase remission rate and considering the old age

of our patient, we initiated a combined modality program using interferon alfa, etretinate, and PUVA therapy. Overall, side effects including flu-like symptoms and desquamation of the skin were mild to moderate in our patient. Partial remission refers to a 50% or greater decrease in the sum of the products of diameters of all measured lesions lasting at least 4 weeks. After 10 weeks treatment, our patient achieved partial remission with tolerable side effects. Thereafter our patient received maintenance therapy with interferon alfa and oral etretinate and the disease did not recur for 4 months of follow-up period. Because of the poor response of patients with advanced disease to a variety of regimens, this triple combination may be a reasonable therapeutic alternative that is worth investigating further for persistent multifocal skin-restricted CTCL of advanced stage. We report our experience in treating stage IIB CTCL patient with triple combination of interferon alfa, oral retinoid, and PUVA therapy.

REFERENCES

1. Dalton JA, Yag-Howard C, Messina JL, Glass LF: Cutaneous T-cell lymphoma. *Int J Dermatol* 1997; 36:801-809.
2. Weinstock MA, Reynes JF: The changing survival of patients with mycosis fungoides. *Cancer* 1999; 85:208-212.
3. Kim-James HY, Heffernan MP: The diagnosis, evaluation, and treatment of cutaneous T-cell lymphoma. *Curr Prob Dermatol* 2001;13: 301-340.
4. Kuzel TM, Roenigk HH Jr, Samuelson E, et al: Effectiveness of interferon alfa-2a combined with phototherapy for mycosis fungoides and the Sezary syndrome. *J Clin Oncol* 1995;13:257-263.
5. Duvic M, Lemak NA, Redman JR, et al: Combined modality therapy for cutaneous T-cell lymphoma. *J Am Acad Dermatol* 1996;34:1022-1029.