

Atypical Dermatoglyphics in Trisomy 18 (Edwards Syndrome)

Duck Taik Shim, M.D., Young Keun Kim, M.D., Kyu Uang Whang, M.D.,
Young Lip Park, M.D., Hyun Jung M.D.

*Department of Dermatology, Soonchunhyang University College of Medicine
Seoul, Korea*

A 19 month old girl with trisomy 18 is described. She showed loose folds of skin about the neck, a prominent occiput, a simian crease on both palms, epicanthal folds, acrocephaly, micrognathia, and unusual dermatologic features including total alopecia and no finger prints on either hands.

Because of the simian crease on both palms, dermatoglyphics of both hands and total alopecia, a skin biopsy from the scalp and a chromosomal study were established at age 19-months, and an absence of hair follicles was observed, while peripheral blood lymphocytes demonstrated 47, XX, +18.

To our knowledge, this would be the first recorded report on the dermatoglyphic pattern of Edwards syndrome in a Korean journal of dermatology. (*Ann Dermatol* 5:(1) 30-33, 1993)

Key Words: Dermatoglyphics, total alopecia, trisomy 18

Trisomy 18 was recognized in 1960 nearly simultaneously by Edwards et al.,¹ Patau et al.,² and Smith et al.³ The incidence has been estimated at 0.3 in 1,000 newborns with a female to male ratio of 3:1.⁴ Usually typical facies of this syndrome consist of micrognathia, a small triangular mouth, a short upper lip, a high arched or cleft palate, a prominent occiput⁵, and flexion deformities of the fingers with the second finger overlapping the third and occasionally the fifth finger overlapping the fourth. There are redundant cervical skin folds not unlike those seen with neck "webbing".^{6,7,8} A simian crease is often noted. From the time of the original description, many additional case reports have been published.

We have had the opportunity to observe a girl with trisomy 18 who had unusual dermatologic features of no finger prints on either hands and total alopecia.

The authors proposed to develop a better understanding of the natural history, clinical pattern, family history, associated diseases, and dermatologic manifestations of Edwards syndrome in children.

REPORT OF A CASE

The proband, now aged 19 months, was the only child of a 27 year old mother and 32 year old father who were healthy, intelligent and unrelated. Neither parent had been exposed to x-ray radiation, and both were in good health at the presumed time of conception. There are no known anomalies in the family, which includes 4 aunts and uncles. Intrauterine growth was poor and fetal movements were reduced. Following normal spontaneous vaginal delivery at 40 weeks, she weighed 2.8 Kg, and her height and head circumference were not recorded. A few abnormalities, which included total alopecia and micrognathia, were noted at birth and the diagnosis of trisomy E was established at 19 months by cytogenetic study. Chromosome study on

Received May 8, 1992

Accepted for publication June 16, 1992

Reprint request to: Duck Taik Shim, M.D. Soonchunhyang University Hospital, 657 Hannam-Dong, Yongsan-Ku, Seoul, Korea

peripheral lymphocytes was 47, XX, +18. Karyotypes showing the 'E' group of the case are presented (Fig. 1). Physical examination at visit revealed total alopecia, micrognathia, epicanthal fold, redundant neck skin, acrocephaly, prominent occiput (Fig. 2), simian crease (Fig. 3), and no finger prints on either hands (Fig. 4). A biopsy specimen from the scalp disclosed an absence of hair follicles. Investigations giving normal results included routine hematology and urinalysis. Serum values for total protein, electrophoretic pattern, gamma globulin, sodium, potassium, car-

bon dioxide capacity, chloride, calcium, phosphorus, and alkaline phosphatase were also normal. No cardiac abnormality was detected.

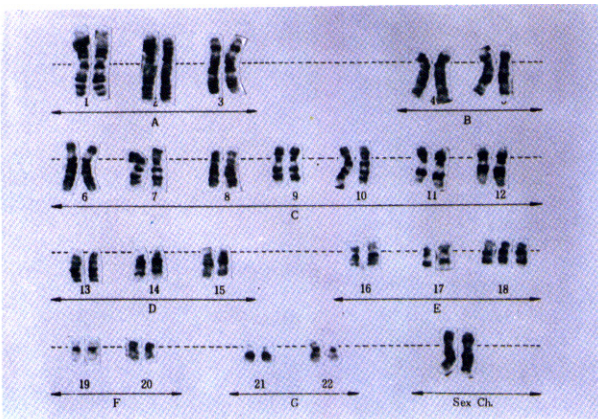


Fig. 1. Karyotype of the patient showing trisomy 18.

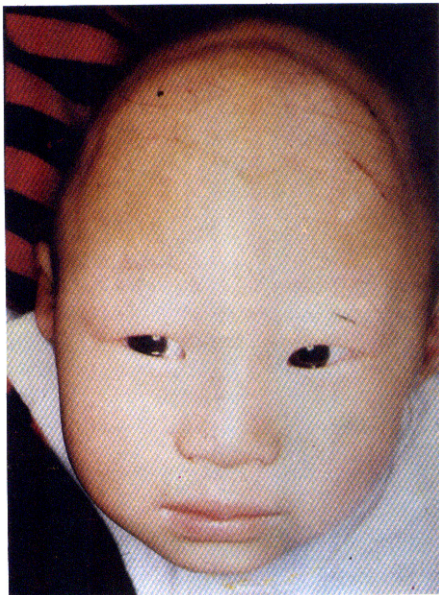

Fig. 2. Note the total alopecia, micrognathia, and epicanthal fold.

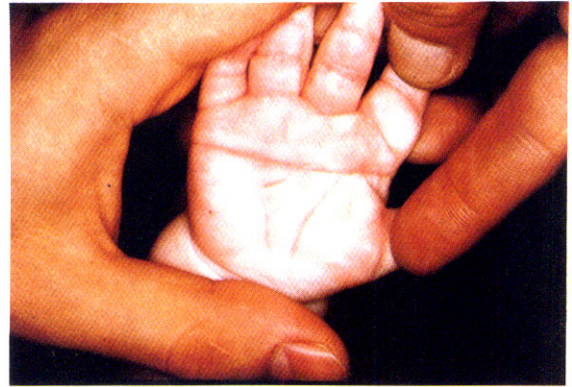

Fig. 3. Simian crease.

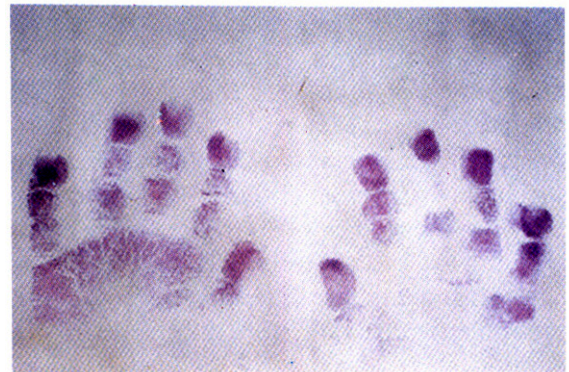

Fig. 4. A dermatoglyphics on both hands.

DISCUSSION

Since Tijio and Levan established the normal human chromosome number as 46, numerous abnormalities of the human chromosome complement have been described. The first of these anomalies was described in 1959 by Lejeune et al., who found that in mongolism there was an extra chromosome in group 21-22 (also known as the G group).

In 1960, Edwards et al. published the first case report of trisomy 18. At present over 100 accounts of this autosomal abnormality have been pub-

lished. Only brief mention has been made of trisomy 18 in the dermatologic literature. Trisomy 18 is the association of multiple congenital anomalies with an extra chromosome of the E group^{8,9}. The most characteristic clinical features are in the hands and feet. Deformity of the hands is manifested by finger flexion, adduction of the first digit, and the second digit overlying the third. The foot deformities consist of "rocker-bottom" feet and malformed digits. But such deformities were not revealed in our case. Other prominent clinical features include mental and growth retardation, microcephaly, micrognathia, low set ears, skeletal deformities of the thoracic cage, prominent occiput, and congenital heart disease. Dermatoglyphic analysis is complicated by the flexion deformities of the hands and dermal ridge hypoplasia which is more severe in trisomy 18. Trisomy 18 is characterized by a high frequency of simple arches on both fingers and toes. Other helpful features include radial loops on the thumbs, single flexion creases of the little finger, a transverse palmar (simian) lines, and, less commonly, hallucal arches and missing digital triradii. The absence of arches of the big toe and the presence of non-arch pattern on all fingers is strong evidence against a diagnosis of trisomy 18.¹⁰ Dermatoglyphic findings in our case are similar to those previously reported¹¹ including simian creases and non-arch pattern on the fingers. It is of interest that our case had no finger prints on either hands, but normal dermatoglyphics on the soles, and that the eyebrows and scalp hair were almost absent and fine.

Most patients with trisomy 18 die within the first 3 months of life, and approximately 10% of patients survive the first year like our case⁴. However, cases of advanced survival beyond 10 years of age have been observed¹²⁻¹⁹. Crippa et al suggest that long survival in patients diagnosed with trisomy 18 is associated with mosaicism.

The syndrome has been of sporadic occurrence. Its frequency increases with advancing maternal age²⁰.

Clues that might suggest trisomy 18 are atypical dermatoglyphics, simian crease, micrognathia, and prominent occiput. Confirmation of clinical, radiographic, and dermatoglyphic diagnosis should be made by a study of the patient's

karyotype.

Factors which are likely to have contributed to total alopecia and no finger prints in this child are not illuminated. Whatever the explanation, this child illustrates the point that a baby with trisomy 18 may have total alopecia and atypical dermatoglyphics, an observation of relevance for those involved in counselling the parents of an affected newborn infant.

We have lately seen in an infant with proved trisomy 18 what may prove to be a new clinical sign involving the hair and dermatoglyphics.

REFERENCES

1. Edwards JH, Harnden KG, Cameron AH, Crosse VM, Wolff LH: A new trisomic syndrome. *Lancet* 1:787-789, 1960
2. Patau K, Therman E, Smith DW, Inhorn SL: Multiple congenital anomalies caused by an extra autosome. *Lancet* 1:790-793, 1960
3. Smith DW, Patau K, Therman E, Inhorn SL: A new autosomal trisomy syndrome: Multiple congenital anomalies caused by an extra chromosome. *J Pediatr* 57:338-345, 1960
4. Smith DW: *Recognizable patterns of human malformation. Third edition.* Philadelphia, WB Saunders, 1982.
5. Crawford M. d'A.: Multiple Congenital anomalies associated with an extra autosome. *Lancet* 2:22-24, July 1, 1961.
6. Finley WH, Finley SC, and Carte ET.: 17-18 Trisomy syndrome: Review and report of a case. *Am. J. Dis. Child.* 106:591-596, December 1963.
7. Levkoff A, Mather G, and Eisenstein RP: A case of trisomy 16-18 syndrome: Speculation on the pathogenesis of chromosome-induced malformations. *Am. J. Dis. Child.* 107:300-303, March 1964.
8. Smith DW, Patu J, Therman E, and Inhorn SL: A new autosomal trisomy syndrome: Multiple congenital anomalies caused by an extra chromosome. *J. Pediatr.* 57:338-345, September 1960.
9. Singleton EB, Rosenberg HS, and Yang SJ: The radiographic manifestations of chromosomal abnormalities. *Radiol. Clin. North America* 2:281-295, August 1964.
10. Hodes ME, Cole J, Palmer CG, and Reed T: Clinical experience with trisomies 18 and 13. *Journal of Medical Genetics*, 15:48-60, 1978
11. Hecht F, Bryant JS, Motulsky AG, et al: The No. 18 (E) trisomy syndrome. *J Pediatr* 63:605-621, 1963
12. Bass HN, Fox M, Wulfsberg E, Sparkes RS, Crandall BF: Trisomy-18 mosaicism: Clues to the diagnosis. *Clin Genet* 22:343-346, 1985
13. Bensen JT, Steele MW: Brief clinical report: A mildly retarded woman with 46, XX/47, XX, +18 mosaicism. *Am J Med Genet* 22:343-346, 1985

14. Geiser CF: Long survival in a male with 18-trisomy syndrome and Wilms'tumor: *A subsequent report. Pediatrics* 51:153, 1973
15. Geiser CF, Schindler AM: *Long survival in a male with 18-trisomy syndrome and Wilms' tumor. Pediatrics* 44:111-116, 1969
16. Hook EB, Lehrke R, Roesner A, Yunis JJ: *Trisomy 18 in a 15-year-old female. Lancet* 2:910-911, 1965
17. Ray S, Ries MD, Bowen JR: *Arthrokadydysis in Trisomy 18. J Pediatr Orthop* 6:100-102, 1986
18. Surana RB, Bain HW, Conen PE: 18-trisomy in a 15-year-old girl. *Am J Dis Child* 123:75-77, 1972
19. Weber WW, Mamunes P, Day R, Miller P: *Trisomy 17-18 (E): Studies in longterm survival with a report of two autopsied cases. Pediatrics* 34:533-541, 1964
20. Smith DW, Patau K, Therman E, Inhorn SL: *The No.18 trisomy syndrome. J Pediatr* 60:513-527, 1962