

Clinical Comparison of 3D Endoscopic Sinonasal Surgery Between 'Insect Eye' 3D and 'Twin Lens' 3D Endoscopes

Sang Yeob Seong, MD^{1,2}, Sang Chul Park, MD¹, Hyo Jin Chung, MD¹,
Hyung-Ju Cho, MD, PhD^{1,3}, Joo-Heon Yoon, MD, PhD^{1,3,4} and Chang-Hoon Kim, MD, PhD^{1,3}

¹Department of Otorhinolaryngology, Yonsei University College of Medicine, Seoul; and ²Yonsei Well ENT Clinic, Seoul; and

³The Airway Mucus Institute, Seoul; ⁴Research Center for Natural Human Defense System, Yonsei University College of Medicine, Seoul, Korea

Background and Objectives: Three-dimensional (3D) imaging is gaining popularity and has been partially used in robotic surgery but not in sinonasal surgery owing to technical problems. This is not only the first pilot study to evaluate the usefulness of newly-developed 'twin lens' HD-3D endoscope (Machida), but also the first clinical study to compare this instrument with the pre-existing 'insect eye' 3D endoscope (Visionsense).

Materials and Method: A total of 45 surgeries for cerebrospinal fluid leakage, angiofibroma, or sinonasal malignancy were performed using a 3D endoscope between November 2011 and October 2013 ('insect eye' Visionsense VSII 3D: 29 cases, 'twin lens' Machida HD-3D: 16 cases).

Results: Depth perception and recognition of anatomical structures were all excellent in the two 3D methods. The 'twin lens' HD-3D endoscope provided better image resolution and naturalness of color and showed less unfavorable phenomena such as image blurring and blackout than the 'insect eye' 3D endoscope.

Conclusion: If the technical limitations are solved, the 3D endoscope will be used as a substitute and a standard tool in endoscopic sinonasal surgery rather than as supplement to the two-dimensional (2D) endoscope in the near future.

KEY WORDS: Three-dimensional image · Endoscope · Sinusitis · Paranasal sinus neoplasms.

INTRODUCTION

The first endoscopic sinus surgery was introduced by Messerklinger and Wigand in the 1970's.^{1,2)} Endoscopic sinonasal surgery can have excellent access to the depth of the paranasal sinuses with minimal morbidity and without external scar. As the development of endoscopic system enabled high definition and better view, the area is being expanded up to the skull base in recent year.³⁻⁶⁾ The image which conventional two-dimensional (2D) endoscope implements on the display monitor has problems with the perception of distance or space, i.e., the lack of depth.^{7,8)} This

monocular vision could only indirectly predict the depth with clues given by the relative size, color, movement and tactile sense, which can cause the mismatch between actual anatomic location and the depth perception on display. Whereas human eyes are the binocular vision, can recognize the minute differences in the visual cortex, and enable stereoscopic vision by processing the differences.⁹⁾

In order to realize this binocular vision, the endoscope was made of twin lens, and already three-dimensional (3D) imaging technique is widely being used in the laparoscopic surgery or the robotic surgery, and its usefulness has been reported.¹⁰⁻¹²⁾ However, there were many techni-

Received: March 29, 2016 / Revised: August 1, 2016 / Accepted: August 31, 2016

Address for correspondence: Chang-Hoon Kim, MD, PhD, Department of Otorhinolaryngology, Yonsei University College of Medicine, 50 Yonsei-ro, Seodaemun-gu, Seoul 03722, Korea

Tel: +82-2-2228-3609, Fax: +82-2-393-0580, E-mail: entman@yuhs.ac

cal difficulties in endonasal surgery because 3D technology should be implemented in the endoscope with small diameter. A few years ago, 3D endoscope with 4mm diameter using the arthropod eye mechanism ('insect eye' technique) was developed. Its area is gradually being expanded to the skull base and sinonasal surgery, and some studies on the usefulness of 3D endoscope for the endonasal surgery have been reported.¹³⁻¹⁵⁾ All these studies used the 'insect eye' 3D endoscope through an endonasal approach. Recently High-Definition (HD) 3D endoscope (Machida, Co, Ltd.) using the 'twin lens' in the same way as the human eyes with a reduced diameter was introduced. But there was no clinical study of this novel endoscope, and no comparative study with the 'insect eye' technique was reported in the clinical and laboratory field.

In this study, these two 3D endoscope instruments were used for endoscopic sinonasal surgery targeting actual patients. The purpose of this study is to examine the clinical data of this surgery, the pros and cons of the two endoscope instruments, and the current limitation of the 3D endoscope

developed so far.

MATERIALS AND METHODS

This study was approved by the Institutional Review Board of Yonsei University College of Medicine (4-2011-0317).

The subjects of this study were 44 patients who have undergone a surgical operation of a sinonasal area by 3D endoscope in Severance Hospital from November 2011 to October 2013. Among them, 28 patients have undergone surgery by 'insect eye' 3D endoscope (Visionsense), and 16 patients have undergone surgery by 'twin lens' HD-3D endoscope (Machida).

In the 3D visualization via 'insect eye' endoscope and single video chip equipment, 4mm 0-degree and 30-degree rigid endoscopes (Visionsense stereoscopic system, Orangeburg, NY), the light emitting diode (LED) light source, and the 32 inch high-resolution display monitor with 1,360 × 768 pixels were used. The exclusive monitor and polarized glasses should be used owing to the characteristics of

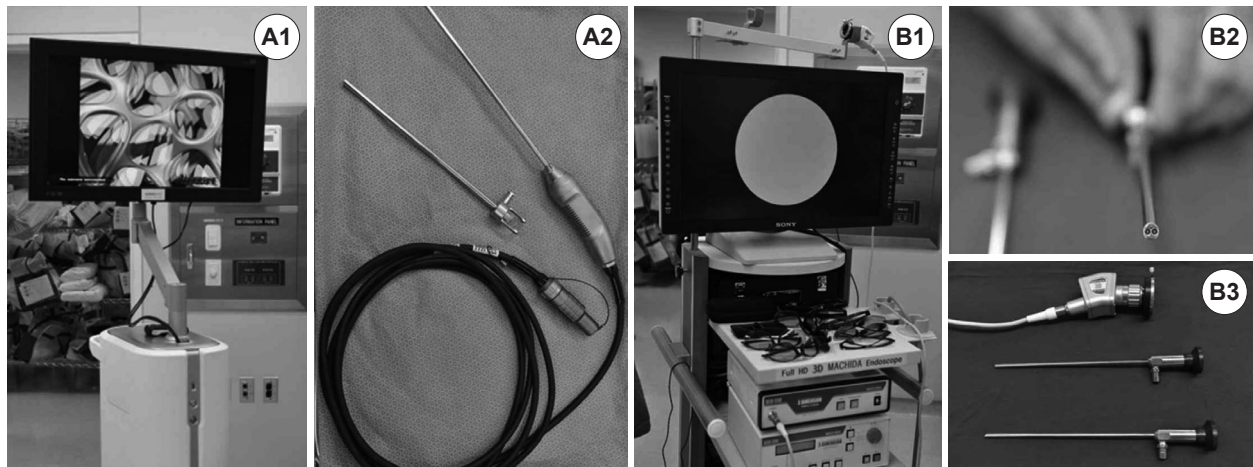


Fig. 1. Visionsense 'insect eye' VSII video tower combining with 32" high-resolution display monitor and 3D imaging processing unit (A1). 4-mm 0°, 30° 3D endoscope and cable with LED light source (A2). 40" high-definition display monitor (Sony, Tokyo, Japan), Machida 'twin lens' 3D video camera unit and 3D converter (B1). 4.7-mm 0° 3D endoscope consisting of twin-lens (B2). 0°, 30° 3D endoscope and xenon light cable (B3).

Table 1. Specification comparison of 3D endoscopes

	VSII 3D Endoscope (Visionsense, Orangeburg, NY)	Machida HD-3D Endoscope (Machida, Tokyo, Japan)
Mechanism	'Insect eye' 3D (Single chip video camera, microscopic array of lenses)	'Twin lens' HD-3D (Dual chip video camera, twin lens)
Light source	LED	Xenon
Endoscope diameter	4 mm	4.7 mm
Angled endoscope	0°, 30°	0°, 30°
Display monitor	Exclusive (32" high-resolution monitor, 1360 × 768 pixels)	Various (compatible)
Polarizing glasses	Exclusive	Various (compatible)

Table 2. Patients' demographic and procedural details for 'insect eye' VSI 3D endoscope

Pt	Sex/ Age	Diagnosis	Radiologic findings	Procedures	Strategy	Op. time (min)
1	F/57	CSF rhinorrhea (L)	Lateral lamella dehiscence	CSF leak repair, Septoplasty	3D+2D	160 (w/lumbar D)
2	F/54	Chronic sinusitis (R)	Fungal ball in Onodi cell	Endoscopic sinus surgery	3D	50
3	M/77	Chronic sinusitis (B)	Severe frontal sinusitis	Endoscopic sinus surgery, Septoplasty	3D+2D	90
4	M/69	Recurrent olfactory neuroblastoma	Nasopharynx mass	Endoscopic mass excision, Posterior septectomy	3D	90
5	M/69	Sinonasal cancer (SCC)	Sphenoid sinus mass	Endoscopic mass excision, Posterior septectomy	3D	140
6	M/13	Recurrent juvenile nasopharyngeal angiofibroma (L)	Extension to sphenopalatine foramen, foramen rotundum	Endoscopic mass excision	3D+2D	130
7	M/37	Mucocoele (R)	Sphenoid sinus mucocoele	Sphenoidotomy, Septoplasty	3D+Navi	80
8	M/65	Chronic sinusitis (B)	Orbital fat herniation	Revision endoscopic sinus surgery	3D	80
9	F/69	Chronic sinusitis (R)	Fungal ball in maxillary sinus	Endoscopic sinus surgery	3D	35
10	M/54	Chronic sinusitis (B)	Severe frontal osteitis	Revision endoscopic sinus surgery	3D+2D	95
11	M/52	Chronic sinusitis (B)	Onodi cell	Endoscopic sinus surgery, Septoplasty	3D	80
12	M/45	Chronic sinusitis (B)	Pansinusitis	Endoscopic sinus surgery, Septoplasty	3D	120
13	M/67	Chronic sinusitis (R)	Fungal ball in maxillary sinus	Endoscopic sinus surgery, Septoplasty	3D	65
14	M/61	Chronic sinusitis (R)	Fungal ball in maxillary sinus	Endoscopic sinus surgery	3D	30
15	M/43	Chronic sinusitis (B)	Type 3 Frontal cell	Endoscopic sinus surgery	3D	70
16	F/44	CSF rhinorrhea (L) s/p meningioma removal	–	CSF leak repair	3D	130 (w/lumbar D)
17	F/57	Nasal cavity cancer (R) (ACC)	–	Endoscopic mass excision, Posterior septectomy	3D+Navi	70
18	M/60	Olfactory neuroblastoma (L)	Kadish stage C	Craniofacial resection, Endoscopic mass excision	3D+2D	630 (w/CFR)
19	M/76	Nasal cavity cancer (L) (ACC)	Stage T4a	Endoscopic mass excision, Posterior septectomy	3D+Navi	170
20	M/60	Nasal cavity cancer (R) (SCC)	Stage T4a	Endoscopic mass excision, Medial maxillectomy via MFDA	3D	180 (w/MM)
21	M/36	Nasal cavity schwannoma (B)	–	Endoscopic mass excision, Endoscopic sinus surgery	3D	80
22	M/58	Inverted papilloma (L)	Ethmoid sinus origin tumor	Endoscopic mass excision, Endoscopic sinus surgery	3D	50
23	M/38	Mucocoele (L), CSF leakage	Frontal sinus mucocoele	Endoscopic sinus surgery, CSF repair	3D+2D	80
24	M/42	CSF rhinorrhea s/p CCRtX Recurrent CSF rhinorrhea	–	CSF leak repair	3D	120 (w/lumbar D)
25	F/74	Inverted papilloma (L)	Ethmoid sinus origin tumor	CSF leak repair w/nasoseptal flap	3D	120 (w/lumbar D)
26	M/54	Plasmacytoma (R)	Inferior turbinate origin	Endoscopic mass excision, Endoscopic sinus surgery	3D+2D	90
27	M/54	Inverted papilloma (L)	Lamina papyracea dehiscence	Endoscopic sinus surgery	3D	80
28	M/21	Recurrent juvenile nasopharyngeal angiofibroma (L)	Sphenopalatine foramen origin	Endoscopic mass excision, Septorhinoplasty Mass excision via endoscopic approach and sublabial approach	3D	90 (w/SRP) 190 (w/sublabial app.)

PT: patient, Op.: operation, Navi: navigation, L: left, R: right, B: both, CSF: cerebrospinal fluid, CCRtX: concurrent chemoradiation, SCC: squamous cell carcinoma, CFR: cranio-facial resection, MM: medial maxillectomy, MFDA: mid-facial degloving approach, w/: with, lumbar D: lumbar drainage, SRP: septorhinoplasty

the 'insect eye' 3D implementation. On the other hand, in the 3D visualization via 'twin lens' and dual video chip equipment, 4.7 mm 0-degree and 30-degree endoscopes (twin lens HD-3D stereoscopic system, Machida, Tokyo, Japan), and xenon light source were used. The display monitor and the polarizing glasses can be compatible with other equipments of various companies because this 'twin lens' binocular 3D implementation method is the same as that currently used in other fields (Fig. 1, Table 1). In all cases, 3D endoscope was used. 2D HD endoscopic system (0-, 30-, 70-degree rigid endoscopes, Karl Storz Endoscopy America Inc., CA, USA) was used together only in the part of limitation of 3D image. The image was displayed on a 23-inch HD monitor with $1,920 \times 1,080$ pixels.

The surgery was performed by one senior surgeon (C.-H. Kim), and the following variables or the subjective param-

eters were evaluated by the surgeon and two observing physician: depth perception, endoscopic orientation, impact on potential complications, image resolution, naturalness of color, over-magnification, brightness, blurred image when blood soiled, blackout by reflected light on the surface of metal instruments.

The patient data including diagnosis, radiologic findings, operation procedures, endoscope adaptation times and operation times were investigated and collected. The operation strategy was examined in details such as use of navigation system and reason of accompanying 2D endoscope.

RESULTS

In the case with the 'insect eye' 3D endoscope, 23 male and 6 female patients were enrolled and their median age

Table 3. Patients' demographic and procedural details for 'twin lens' Machida HD-3D endoscope

Pt	Sex/ Age	Diagnosis	Radiologic findings	Procedures	Strategy	Op. time (min)
1	F/52	Mucopyocele (R)	Sphenoid sinus anterolateral wall dehiscence	Sphenoidotomy	3D	30
2	M/51	Sinonasal malignant melanoma (L)	—	Endoscopic mass excision, Endoscopic sinus surgery	3D	50
3	F/18	Chronic sinusitis (B)	—	Endoscopic sinus surgery, Septoplasty	3D	80
4	M/79	Inverted papilloma (L)	Ethmoid sinus origin	Endoscopic sinus surgery	3D+2D	50
5	F/23	Mucocele (L)	Petrous apex origin	Endoscopic marsupialization	3D+Navi	470 (w/ Tympano.)
6	M/60	Chronic sinusitis (B)	—	Endoscopic sinus surgery, Septoplasty	3D	80
7	F/35	Chronic sinusitis (B)	—	Endoscopic sinus surgery, Septoplasty	3D	60
8	M/45	Chronic sinusitis (R)	—	Endoscopic sinus surgery, Septoplasty	3D	70
9	M/36	Petrous meningioma (L)	Temporo-petrous-sphenoid sinus mass	Endoscopic mass excision, Endoscopic sinus surgery	3D	930 (w/NS)
10	M/53	Recurrent inverted papilloma (L)	Lamina papyracea origin	Endoscopic mass excision, Endoscopic sinus surgery, Septorhinoplasty	3D	120 (w/SRP)
11	M/36	Nasal cavity Myofibroblastic Sarcoma (R)	—	Mass excision via endoscopic approach and canine fossa approach	3D	80 (w/canine fossa app.)
12	M/26	Foreign body materials in retromaxillary area (R)	Fibrous calcification	Endoscopic mass excision	3D+Navi	110
13	M/37	Chronic sinusitis (L)	Type 4 frontal cell	Endoscopic sinus surgery, Septoplasty	3D+2D	80
14	M/80	Nasal cavity cancer (L) (SCC)	Maxillary sinus origin, Stage T3	Endoscopic mass excision, Medial maxillectomy via MFDA	3D	150 (w/MM)
15	F/36	Mucocele (L)	Frontal sinus origin	Endoscopic sinus surgery	3D	30
16	M/53	NK-T cell lymphoma		Endoscopic biopsy	3D	50

Tympano: tympanoplasty, NS: neurosurgery department

was 54 years old. For the 'twin lens' HD-3D endoscope, 11 male and 5 female patients, with the median age 41 years old were enrolled. The disease categorization of patients was varied, including chronic sinusitis, cerebrospinal fluid (CSF) leak, mucocele, and tumor. No intraoperative or post-operative complications were observed in patients of this study. The patients' data and results were described in Table 2 and 3. Some operations were accompanied with 2D endoscope because of blurred vision, overmagnification, the absence of high-angled endoscope, and the frequent blood soiling of endoscope lens. The reasons for the switch from 3D to 2D endoscope in each 3D endoscopic system were described in Table 4.

According to the subjective opinions of the surgeon and observing physicians, the 3D endoscopic images of two methods were compared with the image by qualitative parameters in intraoperative stage (Table 5). The depth perceptions of two methods were all excellent. The diameter of 'insect eye' 3D endoscope was somewhat smaller (4 mm) than that of 'twin lens' HD-3D endoscope (4.7 mm). In the case of the brightness, the 'insect eye' 3D endoscope with LED was a little bit brighter compared to twin lens HD-3D endoscope. The 'insect eye' 3D endoscopic images showed brighter, more florescent blood color, ultimately

yielding a slightly less natural color than the 'twin lens' 3D endoscopic image. Overmagnification was also more pronounced in the 'insect eye' 3D endoscopic image, whereas the image resolution was more superior in the 'twin lens' HD-3D endoscope (Fig. 2). The 'twin lens' HD-3D endoscope showed less unfavorable phenomenon such as blurring of the image when soiled with blood and the blackout by reflected light than the 'insect eye' 3D endoscope. Ultimately it made more comfortable for the surgeon during the surgery, but it was not enough to have a significant effect on the operative outcomes.

DISCUSSION

Synopsis of key findings; comparisons with other studies

In sinonasal surgery, the first element enabling precise surgery while reducing the mortality and complications of a patient is to obtain the wide, high-resolution, stereoscopic view. It can be easily said that one of the most important things in minimal invasive surgery is the development of the endoscope. Currently, the 2D endoscope, which has a small diameter and yield images of high-definition, has been used as a standard in sinonasal surgery. However, be-

Table 4. Causes of switch from 3D to 2D endoscope

'Insect eye' VS II 3D patients	Causes
1	Overmagnification, Blurred vision when blood soiled
3	Not enough high-angled view (for frontal sinus view)
6	Blurred vision when blood soiled
10	Not enough high-angled view (for frontal sinus view)
18	Overmagnification, Not enough high-angled view
23	Overmagnification, Blurred vision when blood soiled
25	Not enough maxillary sinus view (for inverted papilloma)
'Twin lens' machida HD-3D patients	Causes
4	Not enough maxillary sinus view (for inverted papilloma)
5	Not enough high-angled view (for type 4 frontal cell)

Table 5. Comparison of qualitative assessments for 3D endoscopes

	'Insect eye' 3D (visionsense VSII)	'Twin Lens' HD-3D (machida)
Endoscope diameter	Smaller (4 mm)	4.7 mm
Depth perception		Similar
Image resolution		Superior
Naturalness of color		Superior
Overmagnification		Superior
Blurred image when blood soiled		Superior
Blackout by reflected light		Superior
Brightness	Superior	

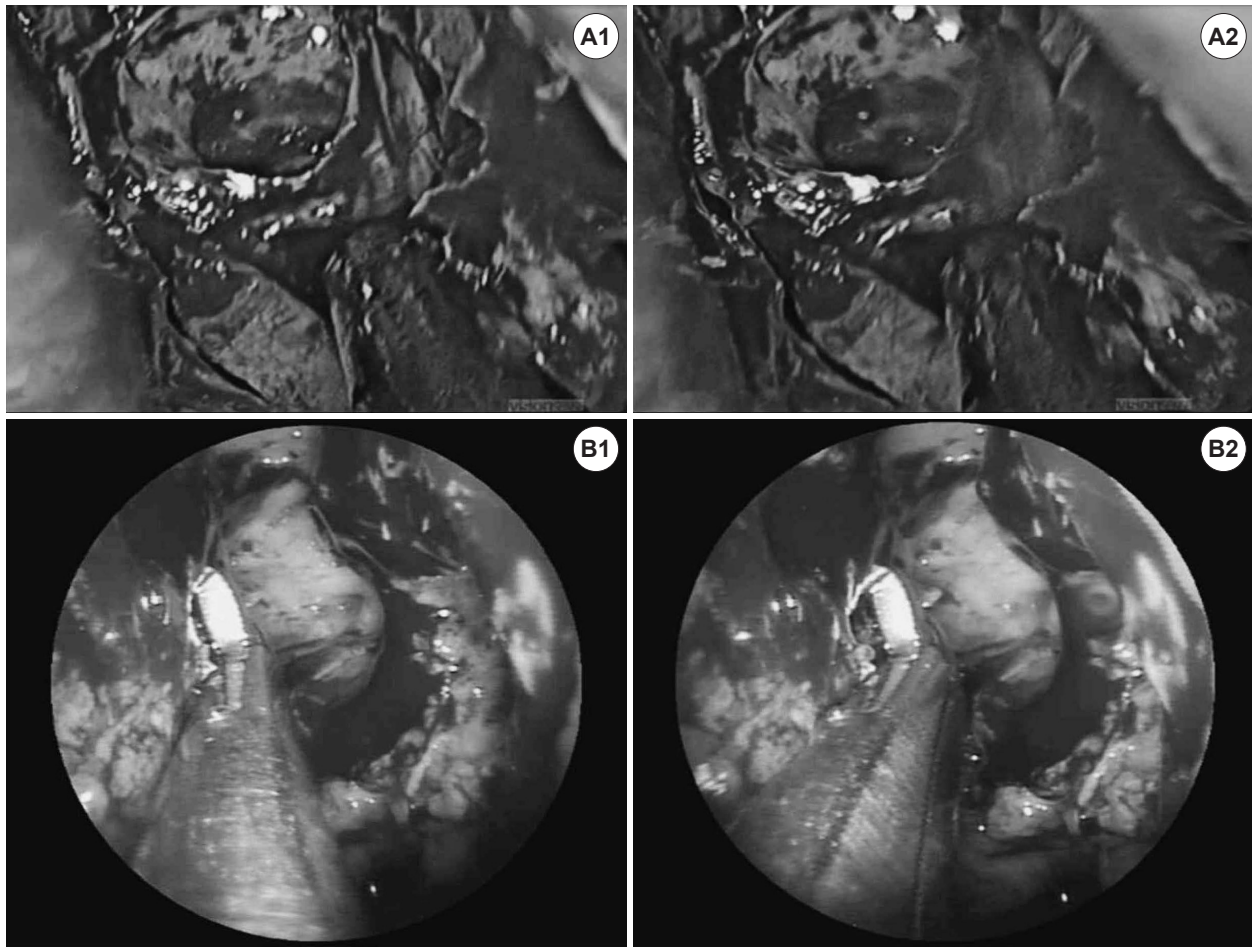


Fig. 2. Left ethmoid sinus view in 2 different patients with 'insect eye' 3D endoscope (Visionsense) (A) and 'twin lens' HD-3D endoscope (Machida) (B). Reconstructed right (A1) and left (A2) images using single video chip. Separate, independent right (B1) and left (B2) images using twin lens and dual video chip.

cause of the limitation of its monocular vision, the relationship with surrounding anatomical structures and the tactile sense had been used for the spatial perception.⁷⁽⁸⁾ As various techniques enabling the 3D view in a flat screen were recently developed, the 3D endoscope is now being actively used in robotic surgery and laparoscopic surgery, and the advantages have been already proven through various literatures and experiences.¹⁰⁻¹²⁾ The development of endoscope for sinonasal cavity has various technical difficulties, and because its diameter should be small, the main 3D endoscopic mechanism used in the endoscopic skull base and sinonasal surgery was to use 'insect eye' technique. Very recently, however, the 'twin lens' HD-3D endoscope yielding binocular vision like human eyes was developed. It uses twin lens and dual video chip, and it can be adapted in the operation of sinonasal cavity because its diameter is only 4.7 mm.

In this study, the stereoscopic views in the two methods above were both excellent, and both had facilitated depth perception in comparison with our previous 2D endoscopic surgery experience. In the 3D endoscope by the two methods, however, there still are technical limitations, such as the absence of high-angled endoscope (45- and 70-degree), the visual orientation distortion when rotating the endoscope (ex. view of maxillary sinus natural ostium), the slight color distortion, the lower quality of sharpness and contrast in display than HD-2D, and the easily blurred vision when soiled by blood. Therefore, the current 3D endoscope still has more inferior points than 2D-HD endoscope in some aspects. For example, overmagnification in 'insect eye' 3D endoscope, which brings 52% loss of field of view compared to 2D, have been reported.¹⁶⁾ Soiling phenomenon leading to longer bleeding control time, and ultimately leads to longer operation time. An

adaptation time (60–90 seconds) is necessary for the surgeon's eyes to adapt to the polarizing glasses after wearing it, and the slight physical discomfort (eye strain, headache and dizziness) can also occur. In addition, the image quality is low in the corner of the displays, and it can vary with the operator's position or distance. Because current 3D endoscope has these limitations, as yet it should be used in conjunction with HD-2D endoscope. Consequently the secondary disadvantages, i.e., the time for changing the instruments, the adaptation time, cost and space, are also occurred. In some studies, it has been reported that the novices prefer more 3D system and the learning curve is reduced, but these two studies were researches in the laboratory field rather than clinical research involving actual patients.¹³⁾¹⁵⁾ In fact, the 3D system might be more difficult to novices in the operation field of the actual patients because of these limitations, such as the blurring when blood soiled, overmagnification, and the absence of high-angled endoscope.

Although there are no significant differences according to the subjective opinions of the user and observers, 'twin lens' HD-3D endoscope does have superior image resolution compared with the 'insect eye' 3D endoscope. In addition, the overmagnification and blurring of images due to soiling with blood, and the blackout by reflected light were reduced. Especially, the phenomenon, such as the blurred image when blood soiled, and the blackout by reflected light is the problems due to the complex image processing process that occurs in recombining multiple images to right and left view in the 'insect eye' 3D technique. Therefore, it is considered that these phenomenon occurred less in the 'twin lens' HD-3D endoscope, which has a more direct and simple stereoscopic mechanism. There was one report that the 'insect eye' 3D endoscope had no color distortion.¹⁷⁾ However, in this study, when comparing the real blood color, in the case of 'insect eye' 3D endoscope, slight color distortion was observed. Its color was brighter than HD-2D and 'twin lens' HD-3D endoscopes, and the distortion into fluorescent color was identified (Fig. 2).

In our study, because of the heterogenous cases, the objective comparison of operation time between 3D and 2D endoscope was impractical. When comparing the operation time of the unilateral fungal sinusitis cases, which has comparatively uniform procedures and disease status, there was no significant difference (Table 2 and 3). Judging from these experiences, 3D endoscopic sinonasal surgery can require more time than 2D when the aforemen-

tioned disadvantages (blood soiling vision, etc.) of the 3D endoscope occur. However, it can also be conjectured that the operating time can be shortened in the surgeries of the more dangerous areas, in which the meticulous operation is required.

Strength and weakness of the study

The comparison using two kinds of endoscopes was not conducted in the same case, and the image quality was evaluated by subjective opinions of a surgeon and observers. However, this is a study in the clinical setting using 3D endoscope in the sinonasal area with the largest sample size, and is also significant in being the first study that compares 'twin lens' HD-3D endoscope with conventional 'insect eye' 3D endoscope. It will be able to help for the further technical development of 3D endoscope in the future.

Clinical applicability of the study

Until now, several papers have reported that the 3D endoscope has the advantage of facilitated depth perception in complex and dangerous area, such as the skull base.³⁻⁶⁾¹⁸⁾¹⁹⁾ However, it is not widely used because of the aforementioned current technical problems. If these subordinate limitations are solved, the 3D endoscope will be used and developed as a substitute and a standard tool beyond the supplement of 2D endoscope in the conventional endoscopic sinus surgery as well as in the cases with complex and dangerous anatomical structure.

Acknowledgments

This work was supported (2014-22-0131) by the Yonsei University Future-leading Research Initiative of 2014.

REFERENCES

- 1) Messerklinger W. Technics and possibilities of nasal endoscopy. *HNO* 1972;20(5):133-5.
- 2) Wigand ME, Steiner W, Jaumann MP. Endonasal sinus surgery with endoscopical control: from radical operation to rehabilitation of the mucosa. *Endoscopy* 1978;10(4):255-60.
- 3) Tabaei A, Anand VK, Fraser JF, Brown SM, Singh A, Schwartz TH. Three-dimensional endoscopic pituitary surgery. *Neurosurgery* 2009;64:288-95.
- 4) Wasserzug O, Margalit N, Weizman N, Fliss DM, Gil Z. Utility of a three-dimensional endoscopic system in skull base surgery. *Skull base* 2010;20:223-8.
- 5) Kari E, Oyesiku NM, Dadashev V, Wise SK. Comparison of traditional 2-dimensional endoscopic pituitary surgery with new 3-dimensional endoscopic technology: intraoperative and early post-operative factors. *Int Forum Allergy Rhinol* 2012;2:2-8.
- 6) Manes RP, Barnett S, Batra PS. Utility of novel 3-dimensional ste-

- reoscopic vision system for endoscopic sinonasal and skull-base surgery. *Int Forum Allergy Rhinol* 2011;1:191-7.
- 7) Hofmeister J, Frank T, Cuschieri A, Wade N. Perceptual aspects of two dimensional and stereoscopic display techniques in endoscopic surgery: review and current problems. *Semin Laprosc Surg* 2001;8:12-24.
 - 8) Taffinder N, Smith SGT, Huber J, Russell RC, Darzi A. The effect of second generation 3D endoscope on laparoscopic precision of novices and experienced surgeons. *Surg Endosc* 1999;13:1087-92.
 - 9) Menz MD, Freeman RD. Stereoscopic depth processing in the visual cortex: a coarse-to-fine mechanism. *Nat Neurosci* 2003;6:59-65.
 - 10) Hanna GB, Shimi SM, Cuschieri A. Randomised study of influence of two-dimensional versus three-dimensional imaging on performance of laparoscopic cholecystectomy. *Lancet* 1998;351:248-51.
 - 11) Buchs NC, Volonte F, Pugin F, Toso C, Morel P. Three-dimensional laparoscopy: a step toward advanced surgical navigation. *Surg Endosc* 2013;27:692-3.
 - 12) Byrn JC, Schluender S, Divino CM, Conrad J, Gurland B, Shlasko E, et al. Three-dimensional imaging improves surgical performance for both novice and experienced operators using the da Vinci robot system. *Am J Surg* 2007;193:519-22.
 - 13) Shah RN, Leight WD, Patel MR, Surowirz JB, Wong YT, Wheelless SA, et al. A controlled laboratory and clinical evaluation of a three-dimensional endoscope for endonasal sinus and skull base surgery. *Am J Rhinol Allergy* 2011;25:141-4.
 - 14) Brown SM, Tabaei A, Singh A, Schwartz TH, Anand VK. Three-dimensional endoscopic sinus surgery: feasibility and technical aspects. *Otolaryngol Head Neck Surg* 2008;138:400-2.
 - 15) Singh A, Saraiya R. Three-dimensional endoscopy in sinus surgery. *Curr Opin Otolaryngol Head Neck Surg* 2013;21:3-10.
 - 16) Van Gompel JJ, Tabor MH, Youssef AS, Lau T, Carlson AP, Loveren HR, et al. Field of view comparison between two-dimensional and three-dimensional endoscopy. *Laryngoscope* 2014;124:387-90.
 - 17) Castelnovo P, Battaglia P, Turri-Zanoni M, Volpi L, Bignami M, Dallan I. Transnasal skull base reconstruction using a 3-d endoscope: our first impressions. *J Neurol Surg B Skull Base* 2012;73:85-9.
 - 18) Barkhoudarian G, Del Carmen Becerra Romero A, Laws ER. Evaluation of the 3-dimensional Endoscope in transsphenoidal surgery. *Neurosurgery* 2013;73:74-9.
 - 19) Bolzoni Villaret A, Battaglia P, Tschabitscher M, Mattavelli D, Turri-Zanoni M, Castelnovo P, et al. A 3-dimensional transnasal endoscopic journey through the paranasal sinuses and adjacent skull base: a practical and surgery-oriented perspective. *Neurosurgery* 2014; 10 suppl 1:116-20; discussion 120.