

Case Report

Anatomical study on true hermaphroditism in an Indian pig (*Sus Scrofa Domestica*)

Neelam Bansal^{1,*}, K.S. Roy¹, D.K. Sharma², Rajnish Sharma³

¹Department of Veterinary Anatomy & Histology, College of Veterinary Science, Punjab Agricultural University, Ludhiana-141004, India

²Department of Livestock Products & Technology, College of Veterinary Science, Punjab Agricultural University, Ludhiana-141004, India

³Department of Veterinary Public Health, College of Veterinary Science, Punjab Agricultural University, Ludhiana-141004, India

A pig was confirmed to be a true hermaphrodite on the basis of gross and histomorphological studies of the genital organs. The genitalia was consisted of left ovary, oviduct, two coiled uterine horns, body of uterus alongwith right testis and an epididymis. Vagina and vulva were absent but male urethra with prostate gland was present. Grossly the size of all the genital organs appeared to be normal. Histomorphologically, testis and epididymis were underdeveloped as there was no clearcut spermatogenia and sertoli cells but Leydig cells were normal. The ovary presents normal histological features with some portion of testicular tissue. Degeneration of uterine epithelium was observed along with normal endometrial glands.

Key words: hermaphrodite pig, gross, histology, genital organs

True hermaphrodite means that gonadal tissue of both the sexes is present in an animal. This may be in the form of one testis and one ovary or gonads containing tissue resembling both testis and ovary (ovotestis) [3,8]. True hermaphroditism is rare in domestic animal but has been reported most frequently in swine [5, 6, 7]. In this report, gross and histomorphological observations on the genital organs of a hermaphrodite pig were studied.

An adult pig of a local breed was slaughtered and whole of the genitalia was removed and fixed in 10% neutral buffered formalin solution. Gross biometrical observations on various genital organs were made with the help of vernier calipers. For histomorphological studies, tissue samples were collected and processed as per routine paraffin procedures. The 5-7 µm sections were stained with haematoxylin and eosin for general histomorphology and Masson's trichrome for demonstration of connective fibres

and parenchyma [4].

The genitalia recovered from hermaphrodite pig contained left side ovary, oviduct, right side testis along with epididymis (Fig. 1). The gonads continued with two uterine horns and a body. The vagina and vulva were absent but prostate gland was observed. The gross morphological studies revealed that the ovary was oval with its length, breadth and thickness as 8.5 cm × 5.7 cm × 3.4 cm. On the surface of ovary, large follicles of 0.8-1.4 cm in diameter and a corpus luteum of 1.8 cm in diameter were observed. The fallopian tube was very flexous and its length and diameter were measured to be 33 and 2 cm respectively. The circumference of oviduct was 3.3 cm and it continued with the uterine horns which were observed to be long and coiled resembling to that of small intestine. The length and diameter of uterine horns were measured as 68.5 cm and 3.3 cm, respectively. The corresponding figures for body of uterus were observed to be 11.2 cm and 3.5 cm, respectively. In another similar study on a hermaphrodite piglet comparatively smaller size of uterine body (7 cm length × 2.5 cm diameter) was reported [5]. The biometrical parameters observed in the present study on ovary, oviduct and uterus of pig are also comparable to other reports [8].

The length, breadth and thickness of the testicles were observed to be 7.0 cm × 6.0 cm and 3.4 cm respectively. The epididymis was closely attached to the testicle and was comprised of head, body and tail. The head of epididymis was found to be longer (6.1 cm) as compared to body (4.3 cm) and tail (1.8 cm). The breadth of the body was comparatively lesser (1.8 cm) than that of head and tail (3.0 cm). The thickness was reported to be minimum in the body (0.6 cm) and maximum in the tail (3.1 cm) of epididymis. Contrary to this, very large tail of epididymis is present in the boar [2] which indicates the abnormal development of genital organs in hermaphrodite pig.

The histological section of ovary showed 3 atretic follicles and luteal cells along with the seminiferous tubules, presence of ovarian tissue along with testicular tissue referred as "ovotestis" (Fig. 2). There was degeneration and vacuolation

*Corresponding author

Tel: +91-161-2401960 (Ext 230); Fax: +91-161-2400822

E-mail: bansal.neelam@rediffmail.com

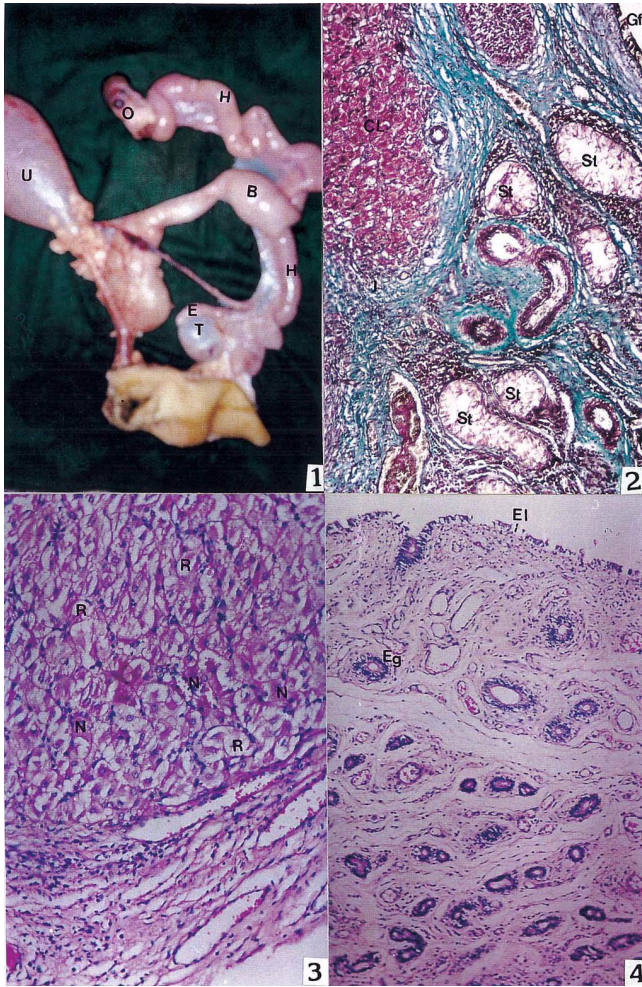


Fig. 1. Genitalia of a hermaphrodite pig showing testis (T), epididymis (E), ovary (O), uterine horns (H), body of uterus (B) and urinary bladder (U).

Fig. 2. Section of ovotestis of a hermaphrodite pig showing presence of seminiferous tubules (St), luteal cells in corpus luteum (CL) and an atretic Graafian follicle (Gf). Masson's Trichrome stain. $\times 70$.

Fig. 3. Section of corpus luteum of a hermaphrodite pig showing both regressive (R) and normal (N) luteal cells. H&E stain. $\times 140$.

Fig. 4. Section of uterus of a hermaphrodite pig showing degeneration of endometrial lining (El) with some of the normal endometrial glands (Eg). H&E stain. $\times 70$.

of luteal cells in the corpus luteum indicating the presence of normal and regressive luteal cells (Fig. 3). The oviduct appeared to be normal with ciliated columnar epithelial lining and folded mucosa and submucosa layers. Similarly, a scrotal ovotestis was also observed in the pigs with inguinal hernia [9]. Section of uterine horn and body showed degeneration of uterine epithelium with normal endometrial glands (Fig. 4). The circular and longitudinal layers of smooth muscles constituted the myometrium.

In testis, the seminiferous tubules were oval or circular in outline, but these were underdeveloped as there was no

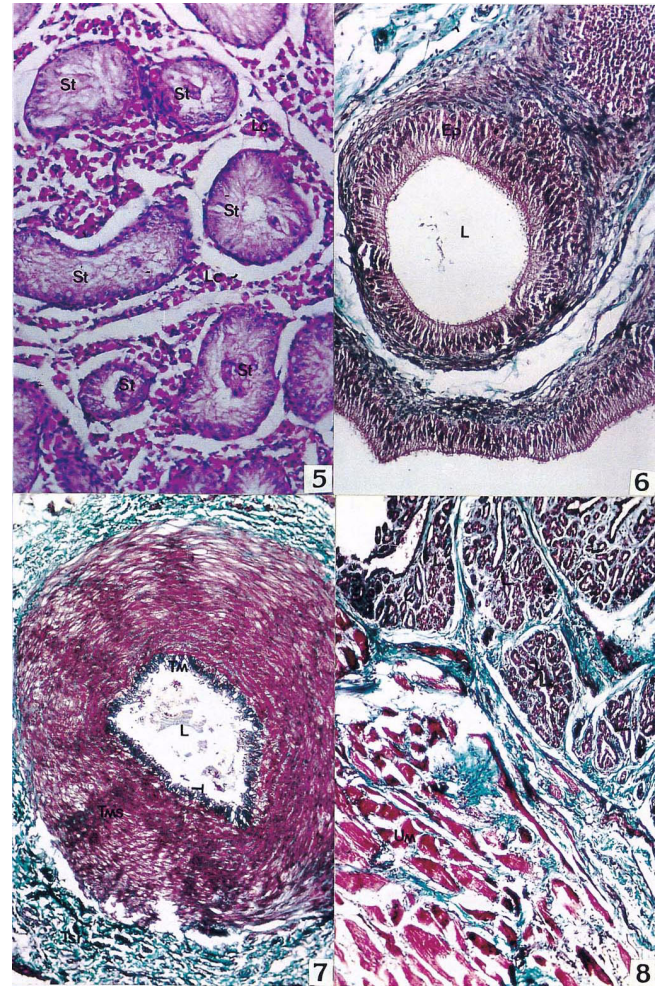


Fig. 5. Section of testis of a hermaphrodite pig showing seminiferous tubules (St) in a cross section without any germinal epithelium, the Leydig cells (Lc) appeared to be normal lying in between the seminiferous tubules. H&E stain. $\times 140$.

Fig. 6. Section of epididymis of a hermaphrodite pig showing normal pseudostratified ciliated columnar epithelium (Ep) without any spermatozoal content or cell debris in the lumen (L). Masson's Trichrome stain. $\times 140$.

Fig. 7. Section of ductus deferens of a hermaphrodite pig showing normal Tunica mucosa (Tm), tunica muscularis (Tms) and tunica serosa (Ts). Some degenerated cellular mass in the lumen (L). Masson's Trichrome stain. $\times 70$.

Fig. 8. Section of prostate gland of a hermaphrodite pig showing normal prostatic lobules (L) enclosed by urethral muscles (Um). Masson's Trichrome stain. $\times 70$.

differentiation of spermatogenic cells (Fig. 5), though normal Leydig cells could be seen at places. These findings confirmed the observations of earlier workers [5]. The epididymis appeared to be normal as it was lined by pseudostratified columnar ciliated epithelium with or without any spermatozoal cell or its debris in the lumen (Fig. 6). The absence of spermatozoal debris in the epididymis reflects the physical status of testis. The tunica mucosa of ductus deferens was observed to be folded and lined by

pseudostratified columnar epithelium (Fig. 7). The tunica muscularis was found to be the thickest layer as compared to the submucosa and serosa. The histoarchitecture of ductus deferens appeared to be normal in a hermaphrodite pig as described in other domestic animals [1]. Among the accessory sex glands, only internal portion of prostate gland could be seen. The prostatic lobules were separated by thick trabeculae observed to be made up of dense connective tissue fibres and some smooth muscle cells (Fig. 8). The prostate gland was surrounded by a thick layer of smooth muscle fibres. Prostatic concretions could not be observed in a hermaphrodite pig may be due to the functional impairment in this animal.

On the basis of present gross and histomorphological studies on genital organs of a pig, the animal is said to be a true hermaphrodite as both the male and female gonads were present in the pig.

References

1. **Dellmann HD, Wrobel KH.** Male and female reproductive systems. In: Dellmann HD, Brown EM (eds.). Textbook of Veterinary Histology. 3rd ed. pp. 293-349, Lea & Febiger, Philadelphia, 1987.
2. **Getty R.** Sisson and Grossman's Anatomy of the Domestic Animals. 5th ed. Saunders, Philadelphia, 1975.
3. **Latshaw WK.** Veterinary Developmental Anatomy, pp. 248, B.C. Decker, Toronto, 1987.
4. **Luna LG.** Manual of Histological Staining Methods of the Armed Forces Institute of Pathology, 3rd ed. pp. 38-39, McGraw Hill, New York, 1968.
5. **Manumohan S.** Hermaphroditism in a piglet. J Vet Anim Sci 1993, **24**, 210-212.
6. **Nair KP, Raja CKSV, Joseph M.** True hermaphroditism in a piglet - a case report. Kerala J Vet Sci 1980, **11**, 335-339.
7. **Pond WG, Roberts SJ, Simmons KR.** True and pseudohermaphroditism in a swine herd. Cornell Vet 1961, **51**, 394-404.
8. **Roberts SJ.** Veterinary Obstetrics and Genital Diseases. 2nd ed. pp. 4-11, pp. 64-65, Scientific Book Agency, Calcutta, 1971.
9. **Tiranti IN, Genghini RN, Gonzalez-Quintana H, Wittouck P.** Morphological and karyotypic characterization of intersex pigs with hernia inguinalis. J Agri Sci 2002, **138**, 333-340.