

Maxillary Ameloblastoma Case of a Dog

Aydın Gürel*, Gülbin Şennazlı, Kürşat Özer¹ and Ahmet Gülçubuk¹

Department of Pathology, Faculty of Veterinary Medicine, Istanbul University, 34850 Avcılar, Istanbul, Turkey

¹Department of Surgery, Faculty of Veterinary Medicine, Istanbul University 34850 Avcılar, Istanbul, Turkey

Received July 28, 2002 / Accepted February 26, 2003

Abstract

In this report, an ameloblastoma case, which has been occurred on the left maxilla of a 10 year-old, male, German shepherd, was described on the clinical and morphological features. The mass with the dimensions of 5×2.5 cm was removed totally by maxillectomy and examined by radiography, magnetic resonance (MR) and biopsy. The tumor was histopathologically classified ameloblastoma of follicular type and in some fields showed acanthotic form. The invasiveness of the tumor was also observed to be high. This report is the first case of maxillary ameloblastoma in dogs in Turkey.

Key words: sog, ameloblastoma, clinical and microscopical findings, therapy

Ameloblastoma is a locally invasive, highly destructive tumor of the jaw consisting of proliferating odontogenic epithelium in a fibrous stroma, frequently occurring in the mandible. Odontogenic tumors are uncommon in domestic animals [7, 12]. It is encountered frequently in dogs and cattle compared to the other species [3, 7, 9, 10, 11]. It is benign but aggressive tumor which is usually located in mandible and rear incisive teeth [4, 7, 8, 13]. In this report, the clinical and morphological features of ameloblastoma manifested to be the first case in Turkey diagnosed on the maxilla of a German Shepherd were aimed to be characterized.

The material involved in the case was submitted to our laboratory in the Department of Veterinary Surgery, Faculty of Veterinary Medicine, University of Istanbul, with the total excision of the tumoral mass measuring 5×2.5 cm in diameter, located on the left maxillary region of a 10-year-old, male, German Shepherd by performing maxillectomy. The obtained material was initially fixed in 10% neutralized-buffered formalin solution and then decalcified in 10% nitric acid solution. After this tissue was cut into several pieces of

0.5-1 cm thickness, paraffin embedded sections were cut into 5-7 mm thickness, stained with H&E and examined with light microscope [6]. Before the operation blood samples were taken for hematology.

The mass located in the mouth of the dog had development period of 4 months after the first examination and had a tendency of further progress in size. It was diagnosed to have periodontitis. There was no response to drug treatments including amoxycillin, vitamin C and dental cleaning.

The dog was fell into cachexia. Cranium had an asymmetric appearance. The mass located from left maxilla to the left ocular region was quite perceptible at the clinical examinations (Fig. 1). At the examination of the oral cavity was observed to have a mildly solid mass with ulceration which was located on the left maxillary bone including premolar 2, 3, 4 (P2, P3, P4) and molar 1, 2 (M1, M2) teeth. It was confirmed to be ameloblastoma with very invasiveness by the light microscopic examination. No metastasis to the regional lymph nodes was found. For haematological analysis, there was mild decrease in erythrocyte count and moderate leucocytosis. The mass was located by oblique ventrodorsal radiography to the left maxillary region. The tumor mass was confirmed to be solid form and to invade to maxillary bone (Fig. 2). No metastasis was found in the lung. To determine the exact margins of the tumor, magnetic resonance (MR) views of cranium through the short axis spin echo T1 (SET1), fast spin echo T2 (FSE T2) through the long axis SET1 and fast spin echo fat saturation T2 (FSE Fatsat T2) perpendicular to the long axis in sagittal view FSE T2 sequences were taken. Through MR findings as well as orbital involvement (Fig. 3) the mass was found to invade the left maxillary sinuses (Fig. 4), having expansively developing elastic and solid parts. Septum nasi was observed to have a site of invasion. Based on all the results obtained, maxillectomy was decided to perform the similar surgical technique being carried out previously for the tumor with widespread invasive character [14]. After total maxillectomy, parenteral fluid therapy was continuously done for 2 days and for the following week the patient was only fed on juicy food and milk via nasopharyngeal catheter. Antibiotic therapy was also applied for 6 days after surgery.

* Corresponding author: Aydın Gürel
Istanbul University, Faculty of Veterinary Medicine, Department of Pathology 34850 Avcılar, Istanbul, Turkey
Fax: 90212 591 69 76, E-mail: Agurel@istanbul.edu.tr

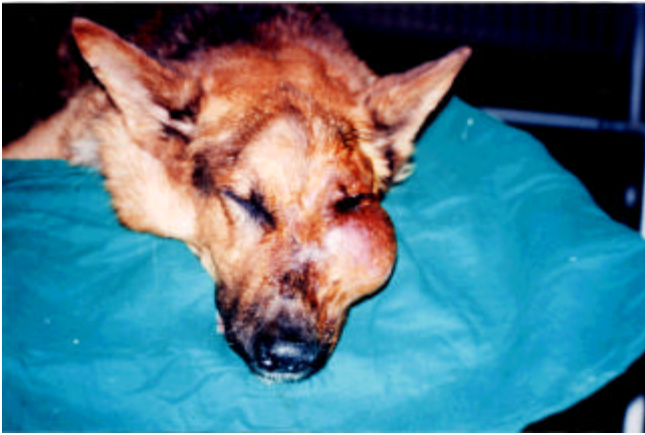


Fig. 1. The mass on the left maxiller region, expanding the ocular area.

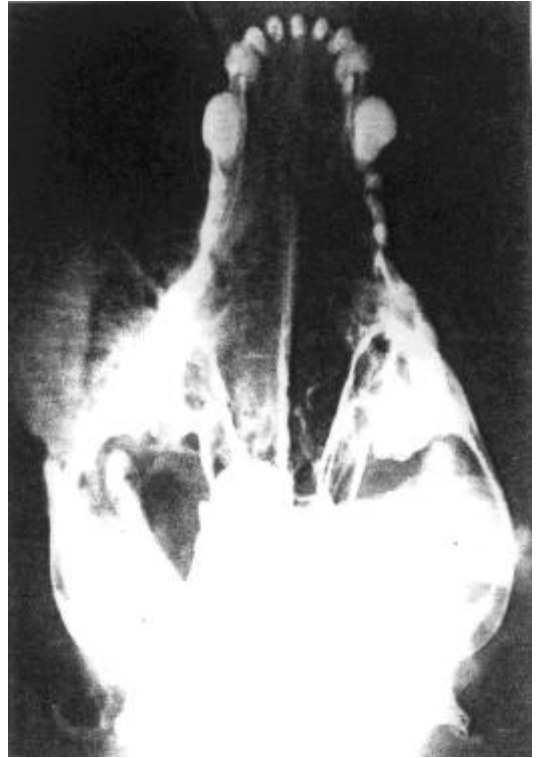


Fig. 2. The radiographic appearance of the mass.

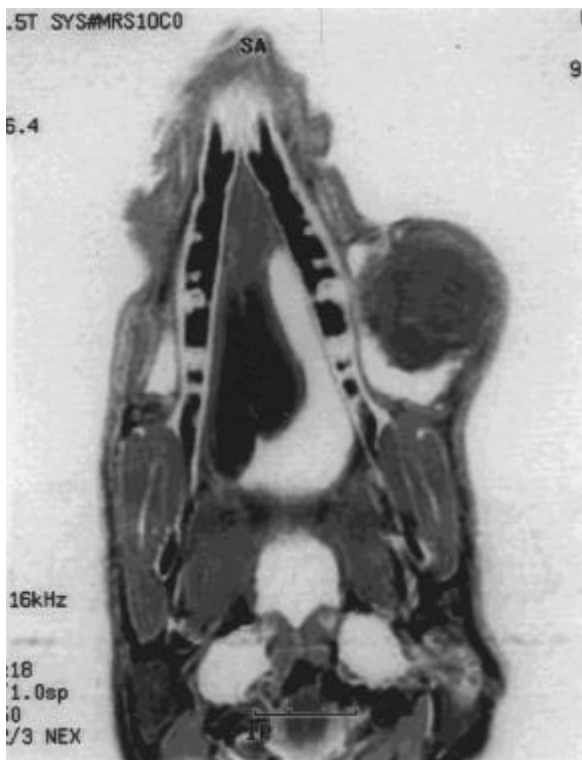


Fig. 3. The invasion of the left maxillary sinus by the mass (MR).

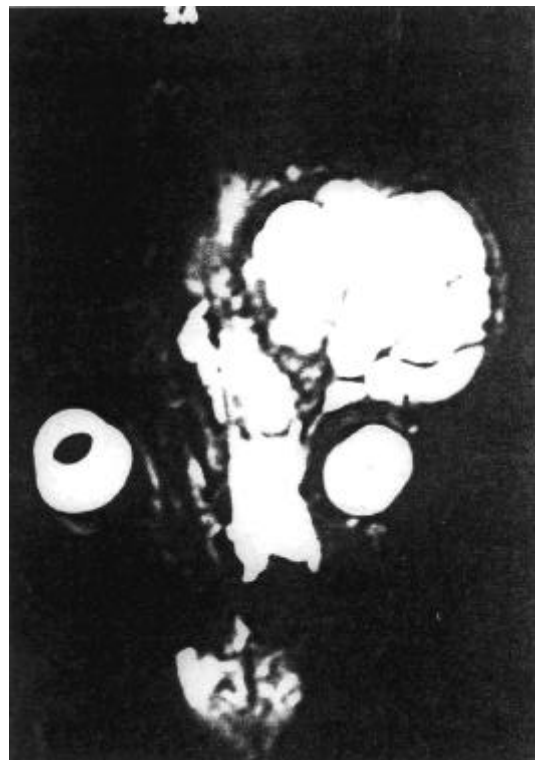


Fig. 4. The invasion of the orbital region and septum nasi (MR).

Histologically the large area of the mass was composed of solid groups of epithelial cells separated by sheets of dense fibrous stroma. The cell groups at the periphery were the epithelial cells with hyperchromatic, fusiform or round nuclei, the shapes of which were identical to those of the cytoplasm (Fig. 5). Among some epithelial cell groups at the center there were large cells with eosinophilic cytoplasm and big nuclei probably formed by the metaplastic transformation of the neoplastic cells (Fig. 6). In some areas, the tumorous tissues were observed to have metaplastic changes into the bone tissue which were observed as bone lamella. In some sections of the tumor mass within the normal mesenchymal tissue of the teeth at the periphery they were observed the irregularly arranged islands of cells, columnar or cuboidal in shape and in the center were present stellate cells with vacuolar cytoplasm (Fig. 7). On the basis of these findings the tumor was confirmed as ameloblastoma of

follicular type bearing acanthotic changes. In this case, the location site of the tumorous mass was left maxillary region unlike the literatures [1, 3, 7, 12, 13] in which mandibula was the preferential site of approximately 80%.

In ameloblastoma cases the primary and frequently applied therapeutic principle is partial mandibulectomy or maxillectomy because of the invasive potential of the tumor, even though it is considered to be a benign type. It was reported that survival time following the operation varies from 6 to 74 months and that recurrence can develop in most of the cases [2, 5]. In this particular case the patient was kept under watch following the operation and the tumorous mass was reported to have recurred after 8 months at the previous surgical site and had reached the size of the initial one within approximately 10 or 11 months after surgery.

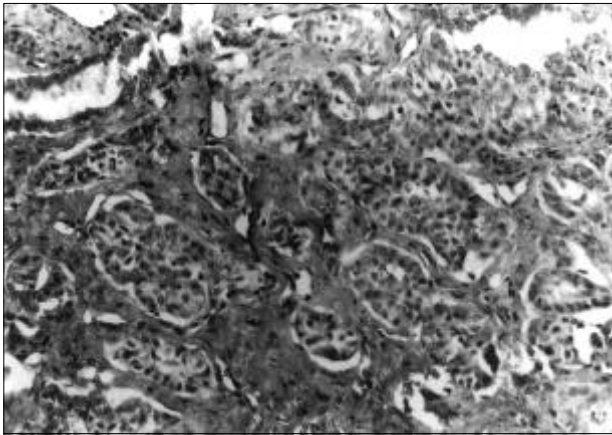


Fig. 5 Solid cell groups separated by the fibrous stroma H.E. \times 200.

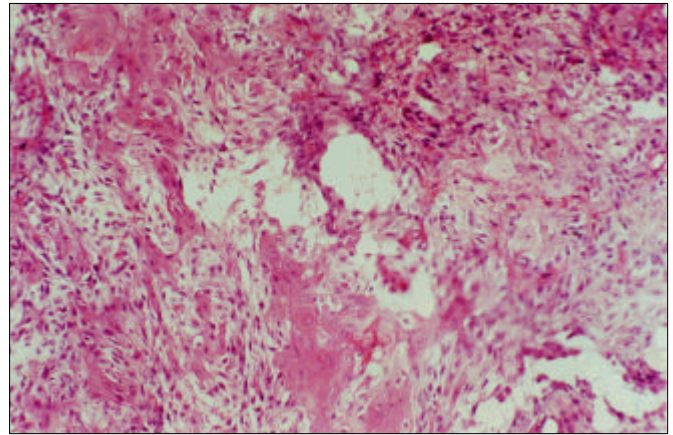


Fig. 6. Large eosinophilic tumor cells with big nuclei in the center of some cell islands. H.E. \times 200.

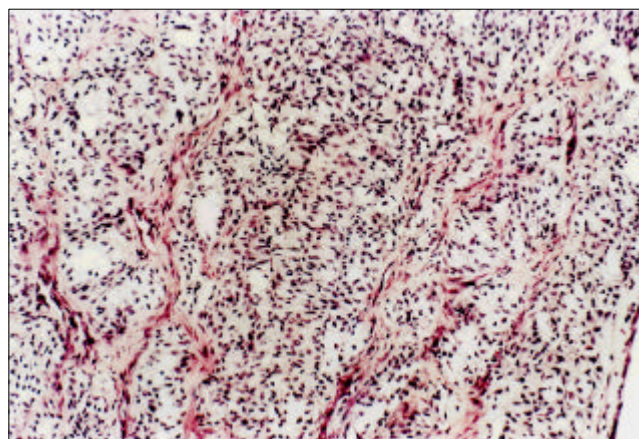


Fig. 7. Irregularly arranged islands of stellate reticulum cells with vacuolar cytoplasm H.E. \times 200.

References

1. **Crossley, D. A. and Penman, S.** Manual of Small Animal Dentistry. pp.206, 2nd ed. Cheltenham-U.K. 1995.
2. **Fox, L. E., Geoghegan, S. L., Davis, L. H., Hartzel J. S., Kubilis, P. and Gruber, L. A.** Owner Satisfaction with partial mandibulectomy or maxillectomy for treatment of oral tumors in 27 Dogs. J. Am. An. Host. Assoc. 1997, **33(1)**, 25-31.
3. **Gardner, D. G., Dubielzig, R. R. and McGee, E. V.** The so-called calcifying epithelial odontogenic tumours in dogs and cats. J. Comp. Path. 1994, **111(3)**, 221-230.
4. **Hughes, C. A. and Wilson, W. R.** Giant ameloblastoma: Report of a an extreme case and a description of its treatment. Ear, Nose Throat. 1999, **78(8)**, 568-571.
5. **Kosovsky, J. K., Matthiesen, D. T., Marretta, S. M. and Patnaik A. K.** Results of partial mandibulectomy for the treatment of oral tumors in 142 dogs. Vet. Surg. 1991, **20(6)**, 397-401.
6. **Luna, L. G.** Manual of Histologic Staining Methods of the Armed Forces Institute of Pathology. 3rd ed. McGraw Hill Book Company. 1960.
7. **Moulton, J. E.** Tumors in Domestic Animals. pp.240-246. 2nd ed. University of California Press. Los Angeles, 1978.
8. **Pindborg J. J. and Kramer, I. R. H.** Histological typing of odontogenic tumours, jawcysts, and allied lesions. International Histological Classification of Tumours. No.5 World Health Organization. Geneve. 1971.
9. **Sakai, H., Yanai, T., Yoshida, K., Iwasaki, T., Fujioka, H., Ota, J., Isowa, K. and Masegi T.** Ameloblastoma with prominent ossification in the mandible of a dog. J. Vet. Med. Sci. 1996, **58(11)**, 1113-1115.
10. **Sartin, E. A., Weiss, R. C., Baird, A. N., Baird, D. K., Spano, J. S., Rodu, B. and Vigneswaran, N.** Ameloblastic fibrosarcoma in a bull. J. Comp. Path. 1998, **118(1)**, 51-55.
11. **Summers, P. M., Wells, K. E. and Adkins, K. F.** Ossifying ameloblastoma in a horse. Austr. Vet. J. 1979, **55(10)**, 498-500.
12. **Theilen G. H. and Madewell, B.R.** Veterinary Cancer Medicine. pp.504-506, 2nd ed. Lea & Febiger. Philadelphia. 1987.
13. **Walsh, K. M., Duholm, L. J. and Cooper, B. J.** Epithelial odontogenic tumours in domestic animals. J. Comp. Path. 1987, **97(5)**, 503-521.
14. **Withrow, S. J., Nelson, A. W., Manley, P. A. and Biggs, D. R.** Premaxilectomy in the dog. J. Am. Anim. Hosp. Assoc. 1985, **21**, 49-55.