

ORIGINAL ARTICLE

The Use of a Corrective Procedure with Vicryl Mesh for Oncoplastic Surgery of the Breast

Tae Ik Eom, Byung Seup Kim, Bon Young Koo, Jong Wan Kim, Young Ah Lim, Han Hee Lee, Su Jung Lee, Hee Joon Kang, Lee Su Kim

Division of Breast and Endocrine Surgery, College of Medicine, Hallym University, Anyang, Korea

Purpose: In addition to the oncological results, cosmetic results are very important to cancer patients. Currently, the use of oncoplastic surgery is an emerging approach. In this study, we examined the clinical outcomes of the use of a corrective procedure with an absorbable implant, a Vicryl mesh®, as compared with the use of conventional breast conserving surgery (BCS). **Methods:** Fifty six patients who completed questionnaire were enrolled in the study. For 33 cases, BCS was performed concurrently with the use of a Vicryl mesh and for the other 23 cases, conventional BCS alone was performed. Contraindications of the use of corrective procedure were a patient age over 60 year, diabetes, neo-adjuvant chemotherapy and a previous excisional biopsy performed on the same breast. Patients rated their cosmetic outcomes by use of a four point scale. **Results:** For one of 34 cases, the Vicryl mesh was removed due to infection and

this patient was excluded from the study. Twenty seven of the remaining 33 patients (82%) who underwent the corrective procedure with Vicryl mesh were satisfied with their outcome. For patients that received conventional BCS only ten of 23 patients (43%) were satisfied with their outcome ($p=0.05$). Patient age, body mass index (BMI) and tumor location did not affect the cosmetic outcomes of the corrective procedure. When the resection area of the breast was 40-70 cm², 88% of the patients were satisfied with their outcome. **Conclusion:** This study suggested that the use of Vicryl mesh correction was superior to the use of conventional BCS alone for cosmesis. This method appears to provide a satisfactory outcome for oncoplastic surgery of the breast.

Key Words: *Oncoplastic surgery, Vicryl mesh*

INTRODUCTION

The goals of modern surgical treatment of breast cancer include the cure of the patients, preservation of normal breast tissues and satisfying patients' desire esthetically. (1) Breast conserving surgery (BCS) is now one of standard surgical treatment of early breast cancer patients. (2,3) In the results of National Surgical Adjuvant Breast and Bowel Project B-06 (NSABP B-06), (4) the oncologic results of BCS are equivalent to those of modified radical mastectomy (MRM). Although BCS achieved

more acceptable cosmetic outcomes compared with MRM, many patients are still poorly satisfied because of the distortions of breast size and shape. Especially, small breast or inferior quadrant breast tumors showed more unfavorable cosmetic outcomes. To overcome this problem, many oncoplastic approaches were introduced: i.e. the classical mammoplastic techniques, using of local flap like a latissimus dorsi muscle flap, glandular rotation technique and so on. These oncoplastic approaches made it possible to resect larger breast tissues for margins free of tumors with achieving an esthetic goal. (5) And long-term oncologic results of BCS with plastic surgical corrections are equivalent to those of conventional BCS randomized trials. (6) Nowadays, the needs of oncoplastic surgery to improve cosmetic outcomes are more and more increasing. In this study, we examined whether or not Vicryl mesh correction is superior to conventional BCS

Correspondence: Lee Su Kim

Division of Breast & Endocrine Surgery, Hallym University Sacred Heart Hospital, College of Medicine, Hallym University, 896 Pyeongchon-dong, Dongan-gu, Anyang 431-070, Korea
Tel: 031-380-5930, Fax: 031-384-0208
E-mail: lskim0503@hallym.ac.kr

Received: September 11, 2008 **Accepted:** March 2, 2009

alone for cosmesis.

METHODS

Among 56 patients who underwent breast surgery at Hallym Sacred Heart hospital and completed our questionnaire, 33 patients of them had been treated with Vicryl mesh correction and the other 23 patients conventional BCS alone. The conventional BCS is a lumpectomy or a partial mastectomy without correction of dead space. The patients were asked to complete a 3-question written survey to ascertain patient satisfaction with breast contour after surgery, postoperative pain and consistency of the breast. And patients were asked to rate their outcomes on a four point scale (1=very good, 2=good, 3=fair, 4=poor). Patient data obtained from the enrolled patients including age, body mass index (BMI), location of tumor and surface area of tumor resected. The data was collected 6 to 12 months later after surgery. The absorbable implant was made of the Vicryl mesh® (Polyglactin 910 Mesh, 26.5×21.5 cm; Ethicon, Johnson and Johnson, Somerville, USA) wrapped with the Interceed® (Oxidized regenerated cellulose, 7.6×10.2 cm; Ethicon, Johnson and Johnson, Somerville, USA). After making the Vicryl mesh into folding fan, we wrapped it with the Interceed® and sutured with Vicryl (Figure 1). And we put this absorbable implant into the dead space (Figure 2). Prophylactic antibiotics (1st generation cephalosporin) was admin-

istered for 7 days after corrective surgery. We calculated the resection area of breast tissue by long axis multiplied by short axis of removed mass.

Comparison of patients' satisfaction between conventional BCS group and Vicryl mesh group was carried out with the Pearson chi square test and analysis of cosmetic outcomes in vicryl mesh correction group was done with Kruskal-Wallis, *p*-values of less than 0.05 were considered statistically significant. All statistical analyses were performed using SPSS statistical software (version 14; SPSS, Chicago, USA).

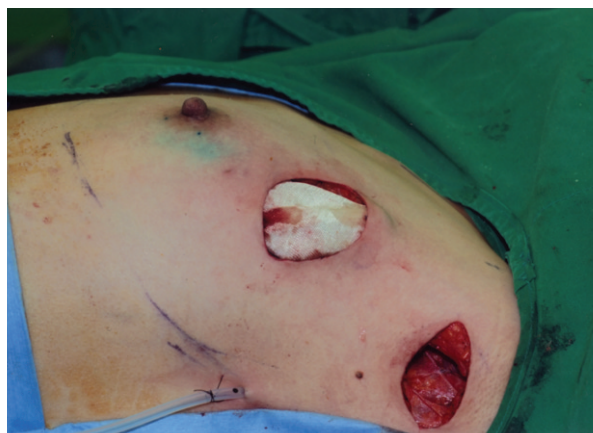

Figure 2. The application of the absorbable implant. This absorbable implant was put into the dead space. And we fixed this material to the breast parenchyma with vicryl suture. To prevent surgical site infection, subcutaneous layer was closed very tightly.

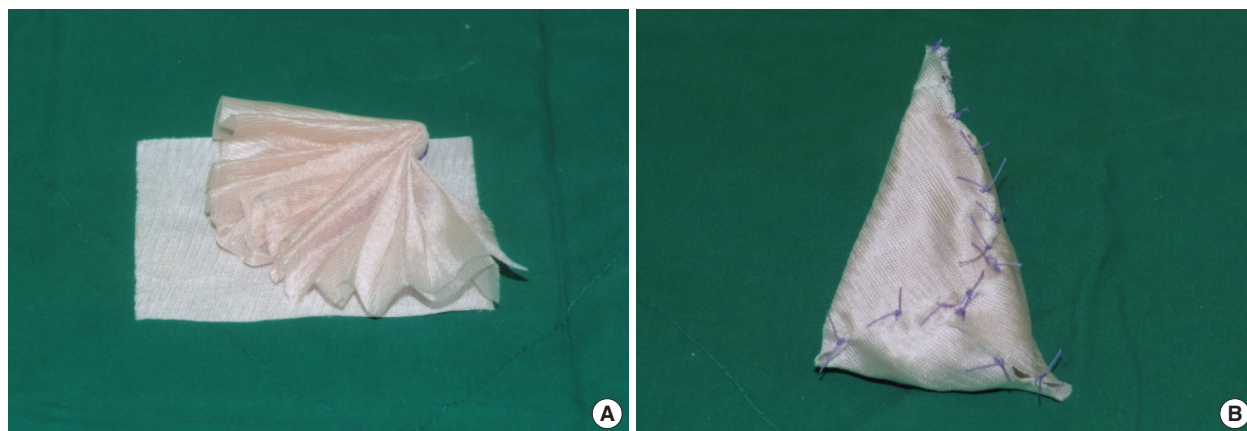


Figure 1. The method of making absorbable implant. (A) Vicryl mesh wrapped with Interceed® (7.6×10.2 cm). (B) Completion of absorbable implant.

RESULTS

The median age of the Vicryl mesh group was 47 yr (range 32–58 yr) and that of the conventional BCS group was 49 yr (range 30–69 yr). The mean BMI of the former was $23.59 \pm 3.3 \text{ kg/m}^2$ and that of the latter was $23.79 \pm 3.02 \text{ kg/m}^2$. In terms of the locations of tumor in the Vicryl mesh group, upper outer quadrant (UOQ) was 57.6%, upper inner quadrant (UIQ) 30.3%, lower outer quadrant (LOQ) 3% and lower inner quadrant (LIQ) 9.1%. In the conventional BCS group, the location of tumor was, UOQ 82.6%, UIQ 4.3%, LOQ 13.0% (Table 1).

Table 1. Demographics of the patients

	Vicryl mesh correction (n=33)	BCS only (n=23)
Mean age (range, yr)	47 ± 7.65 (32-58)	49 ± 10.02 (30-69)
BMI (mean, kg/m^2)	23.59 ± 3.3	23.79 ± 3.02
Tumor location		
UOQ	19 (57.6%)	19 (82.6%)
UIQ	10 (30.3%)	1 (4.3%)
LOQ	1 (3.0%)	3 (13.0%)
LIQ	3 (9.1%)	

BCS=breast conserving surgery; BMI=body mass index; UOQ=upper outer quadrant; UIQ=upper inner quadrant; LOQ=lower outer quadrant; LIQ=lower inner quadrant.

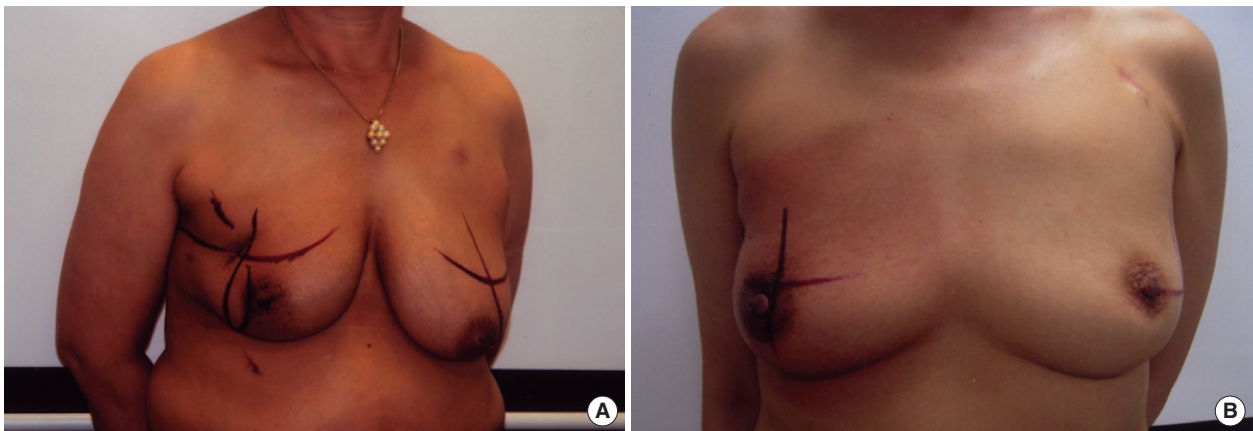


Figure 3. The comparison between Vicryl mesh correction group with conventional BCS during radiation therapy. (A) Frontal view of the patient with conventional BCS. (B) Frontal view of the patient with Vicryl mesh. These patients received radiation therapy 6 months after surgery. There was no additional changes of breast contour during radiation therapy and no radiation skin ulcer at the vicryl mesh graft area.

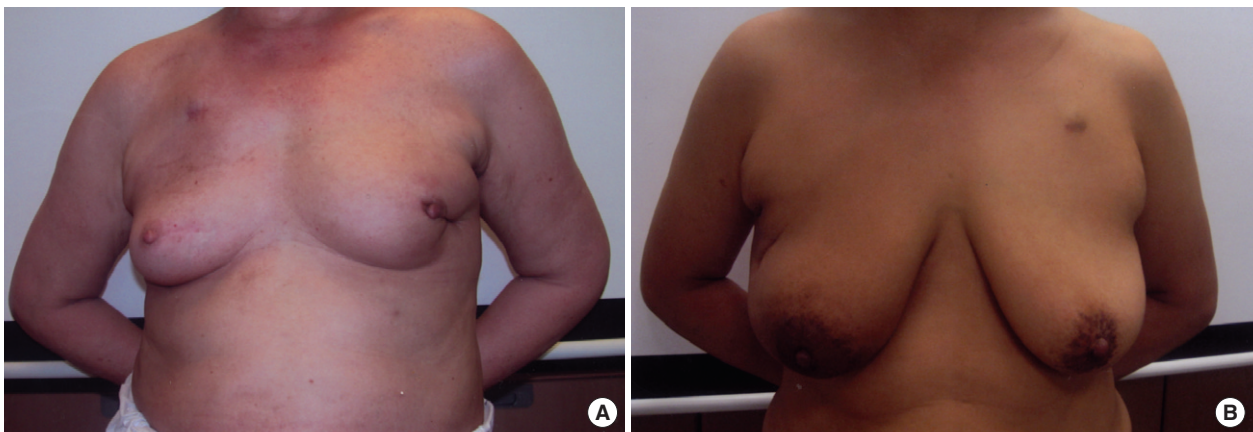


Figure 4. Postoperative figures one year after surgery. (A) Frontal view of the patient with conventional BCS. (B) Frontal view of the patient with Vicryl mesh correction. All of these patients had been treated with adjuvant chemotherapy and radiation therapy. There was little displacement of nipple and areola in vicryl mesh correction case. And also, there was no significant skin dimpling in vicryl mesh correction case.

Table 2. The results of patients' satisfaction

	Vicryl mesh correction n=33 (%)	BCS only n=23 (%)	p-value*
Breast contour			
Very good	10 (30)	2 (9)	0.05
Good	16 (49)	8 (35)	
Fair	6 (18)	12 (52)	
Poor	1 (3)	1 (4)	
Pain after surgery			
None	6 (18)	10 (43)	0.29
Mild	23 (70)	9 (40)	
Moderate	4 (12)	3 (13)	
Severe	0 (0)	1 (4)	
Breast consistency			
Very good	5 (15)	1 (4)	0.59
Good	11 (33)	9 (40)	
Fair	11 (33)	8 (35)	
Poor	6 (19)	5 (21)	

BCS=breast conserving surgery.

*Pearson's *r* correlation coefficient analysis.

In the response of the questionnaires, 80% (23 of 33) of patients who received the Vicryl mesh correction were satisfied with their cosmetic outcomes, on the other hands only 49% (10 of 23) of patients with the BCS alone were satisfied ($p=0.049$, Figure 3, 4). There was no difference between two groups in postoperative pain and consistency of the breast (Table 2). In the results of clinical outcomes in the Vicryl mesh group, locations of tumor and BMI of the patients did not affect the cosmetic outcomes (Table 3). The resection area of tumor was related to the cosmesis. In cases of which resection area was less than 40 cm², 4 of 7 patients were dissatisfied with their cosmetic outcomes. In cases of resection area more than 70 cm², 1 of 2 patients was not satisfied. When resection area of the breast was between 40 to 70 cm², 22 of 25 patients were satisfied ($p=0.035$, Table 3).

DISCUSSION

The Vicryl mesh was generally used in herniorrhaphy and other surgeries. And the safety of this absorbable implant was proved.⁽⁷⁾ The application of this material to correct the deformity after BCS was introduced by Dr. Fukuma at Kameda hospital.⁽⁸⁾ Several cases were reported about the insertion of the Vicryl mesh into the

Table 3. The results of cosmetic outcomes in Vicryl mesh correction group

	Satisfied	Unsatisfied	Total	p-value*
Resected surface area (long resection axis × short resection axis)				
<40 cm ²	2	4	6	0.02
40-50 cm ²	9	1	10	
51-60 cm ²	8	0	8	
61-70 cm ²	6	1	7	
>70 cm ²	1	1	2	
Tumor location				
UOQ	15	4	19	0.35
UIQ	8	2	10	
LOQ	1	1	2	
LIQ	2	0	2	
BMI				
>26	8	0	8	0.20
24-26	5	3	8	
20-23	7	1	8	
<20	6	3	9	

UOQ=upper outer quadrant; UIQ=upper inner quadrant; LOQ=lower outer quadrant; LIQ=lower inner quadrant; BMI=body mass index.

*Kruskal-Wallis test.

breast for cosmetic purposes.^(9,10) We wanted to evaluate the validity of the application of Vicryl mesh as an oncoplastic procedure.

Among the 33 patients who underwent the Vicryl mesh correction, only one patient was dissatisfied. She was 46 yr old and her BMI was 23.4 kg/m². The tumor was located in the upper outer quadrant of breast. The area, resection of tumor, was 30 cm² (5×6 cm). She complained of focal elevated area of breast and rubber like consistency.

In 1 of 34 patients, wound infection was developed and she was excluded from this study. She had to go through chemotherapy and at 3rd cycles of adjuvant chemotherapy (5-FU, epirubicin and cyclophosphamide), she had severe neutropenia (absolute neutrophil <500/μL) and high fever. She presented continuous pain and swelling of operation site in despite of empirical antibiotics. The absorbable implant was removed and then she was recovered. We thought that severe neutropenia could cause the surgical site infection. After this case, we usually used empirical antibiotics in neutropenic patients who had undergone Vicryl mesh correction. There were no more cases of wound infection after using of prophylactic antibiotics when absolute neutrophil count less than 1,000

μL . In spite of the risk of infection, the safety of this procedure was comparable to other plastic prosthesis techniques. There were several reports that prosthesis (the polemic on silicone gel implants) techniques presented 30% of complications and 17% of the permanent expanders were removed.⁽¹¹⁾

One of the advantages of this procedure, Vicryl mesh, is that it could be widely applicable regardless of tumor location. Besides this is very simple method. It takes just a few minutes to do this procedure. And finally, we concluded the optimal resection area of breast tissues for doing this procedure was 40–70 cm^2 .

Limitations of our study are that the number of patients is small and follow up period is not enough to evaluate the long term cosmetic advantages of this procedure, thus serial questionnaires need to be asked to the patients for several years and the more number of patients should be enrolled.

CONCLUSION

Recently, the surgery of breast has an esthetic goal. It is still challenging to select the appropriate plastic techniques to minimize breast deformity after BCS. Our experience with the Vicryl mesh correction showed that this absorbable implant procedure can give way excellent results in cosmesis compared with the conventional BCS. Furthermore, this procedure is very simple, safe and widely applicable regardless of location of tumor with a minimum rate of morbidity. Like this procedure, advanced volume replacement techniques can increase the rate of BCS in complex cancer cases. We suggest that this Vicryl mesh correction could be the good approach

to fill in resected breast volume after BCS.

REFERENCES

1. Vallejo da Silva A, Destro C, Torres W. Oncoplastic surgery of the breast: rationale and experience of 30 cases. *Breast* 2007;16:411-9.
2. Wang HT, Barone CM, Steigelman MB, Kahlenberg M, Rousseau D, Berger J, et al. Aesthetic outcomes in breast conservation therapy. *Aesthetic Surg J* 2008;28:165-70.
3. Cho HJ, Kwak KH, Kim JR, Sohn SC, Park KM, Han SH. Feasibility of concurrent adjuvant chemotherapy and radiotherapy after breast-conserving surgery in early breast cancer. *J Korean Breast Cancer Soc* 2004;4:289-93.
4. Fisher B, Bauer M, Margolese R, Poisson R, Redmond C, Fisher E. Five-year results of a randomized clinical trial comparing total mastectomy and segmental mastectomy with or without radiation in the treatment of breast cancer. *N Engl J Med* 1985;312:665-73.
5. Clough KB, Lewis JS, Fitoussi A, Faucoult MC. Oncoplastic techniques allow extensive resection for breast-conserving therapy of breast carcinomas. *Ann Surg* 2003;237:26-4.
6. Rietjens M, Urban CA, Rey PC, Mazzarol G, Maisonneuve P, Garusi C, et al. Long-term oncological results of breast conservative treatment with oncoplastic surgery. *Breast* 2007;16:387-95.
7. Gianetta E, Cian F, Cuneo S, Friedman D, Vitale B, Marinari G, et al. Hernia repair in elderly patients. *Br J Surg* 1997;84:983-5.
8. Sanuki J, Fukuma E, Wadamori K, Higa K, Sakamoto N, Tsunda Y. Volume replacement with polyglycolic acid mesh for correcting breast deformity after endoscopic conservative surgery. *Clin Breast Cancer* 2005;6:175.
9. Góes JC, Landecker A, Lyra EC, Henríquez LJ, Góes RS, Godoy PM. The application of mesh support in periareolar breast surgery: clinical and mammographic evaluation. *Aesthetic Plat Surg* 2004;28:268-74.
10. Góes JC. Periareolar mammaplasty: double skin technique with application of polyglactine or mixed mesh. *Plast Reconstr Surg* 1996;97:959-68.
11. Petit J, Rietjens M, Garusi C. Breast reconstructive techniques in cancer patients: which ones, when to apply, which immediate and long term risks? *Crit Rev Oncol Hematol* 2001;38:231-9.