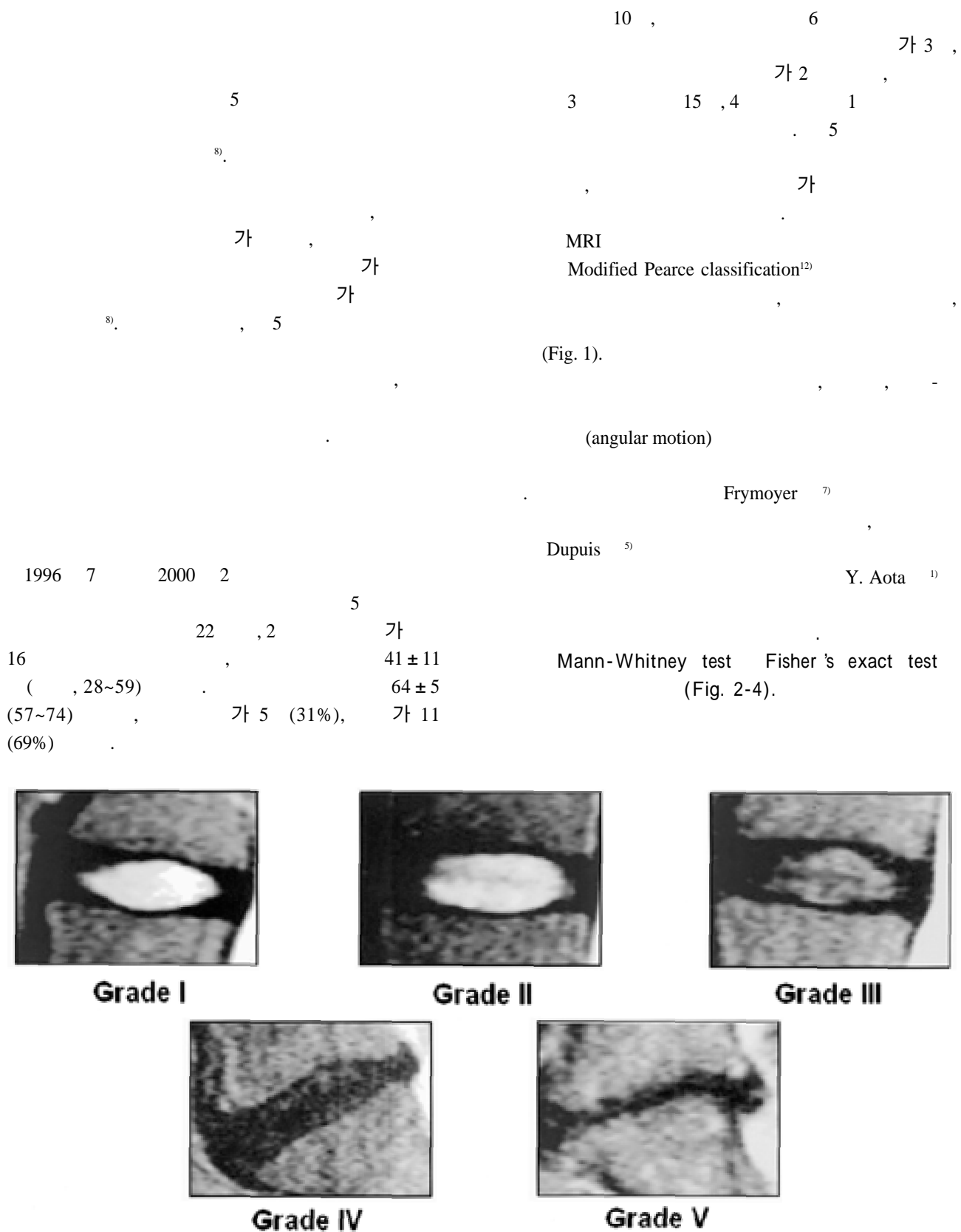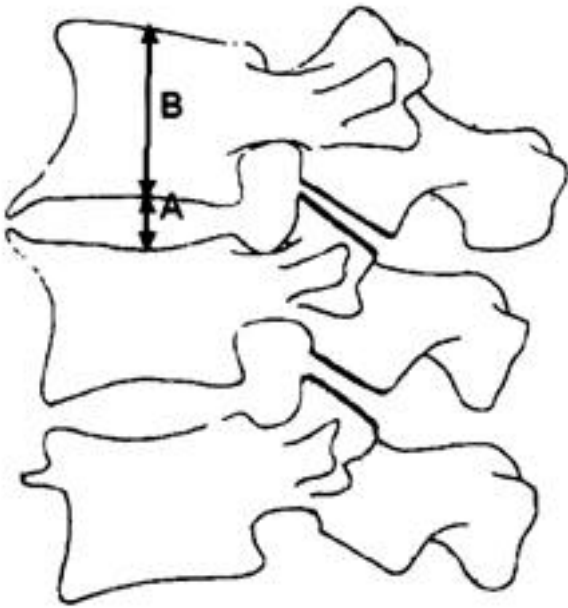
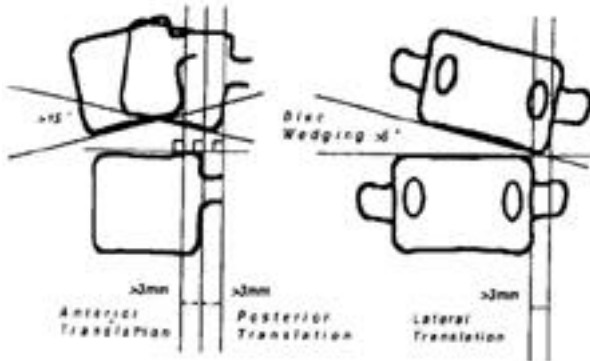


Fig. 1. Grading system for the assessment of lumbar disc degeneration.



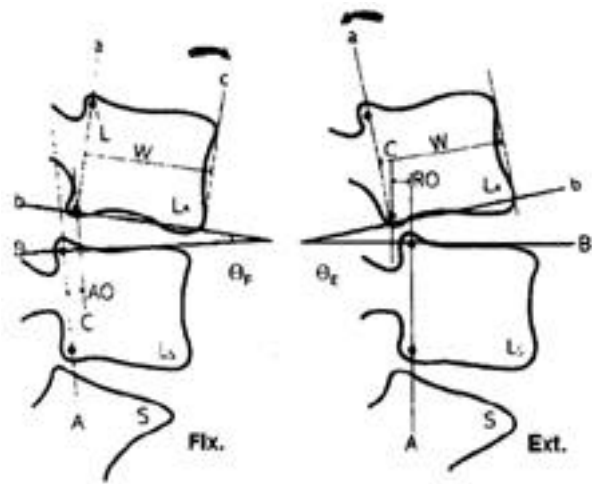
**Fig. 2.** Disc height measurement

- Frymoyer method
- $A/B \times 100(\%)$



**Fig. 4.** Aota's criteria of instability

- > 15° Rotatory hypermobility
- > 3 mm anterior translation
- > 3 mm posterior translation
- > 3 mm lateral translation
- > 5° disc wedging



**Fig. 3.** Angular motion measurement

- Dupuis method

E ~ F

**Table 1.** Preoperative disc degeneration.

Grade	I	II	III	IV	V
Upper	0	2	9	5	0
Lower	0	7	4	3	2

1.

(MRI grade)

Modified Pearce classification

grade II 2, grade

III 9, grade IV 5, grade II 7, grade III 4, grade IV 5  
(Table 1).

2.

MRI

MRI

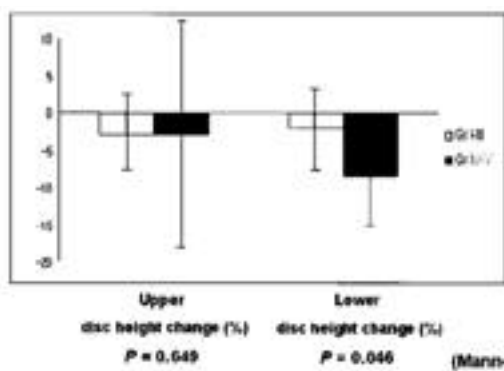
가

-3.0 ± 4.8 % , grade III  
-3.0 ± 13.9 % , grade IV

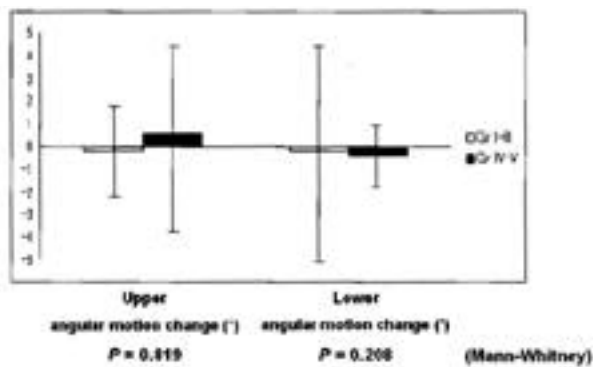
(P=0.649)(Fig. 5).

-2.0 ± 5.4 % , grade III  
-8.4 ± 5.5 % , grade IV

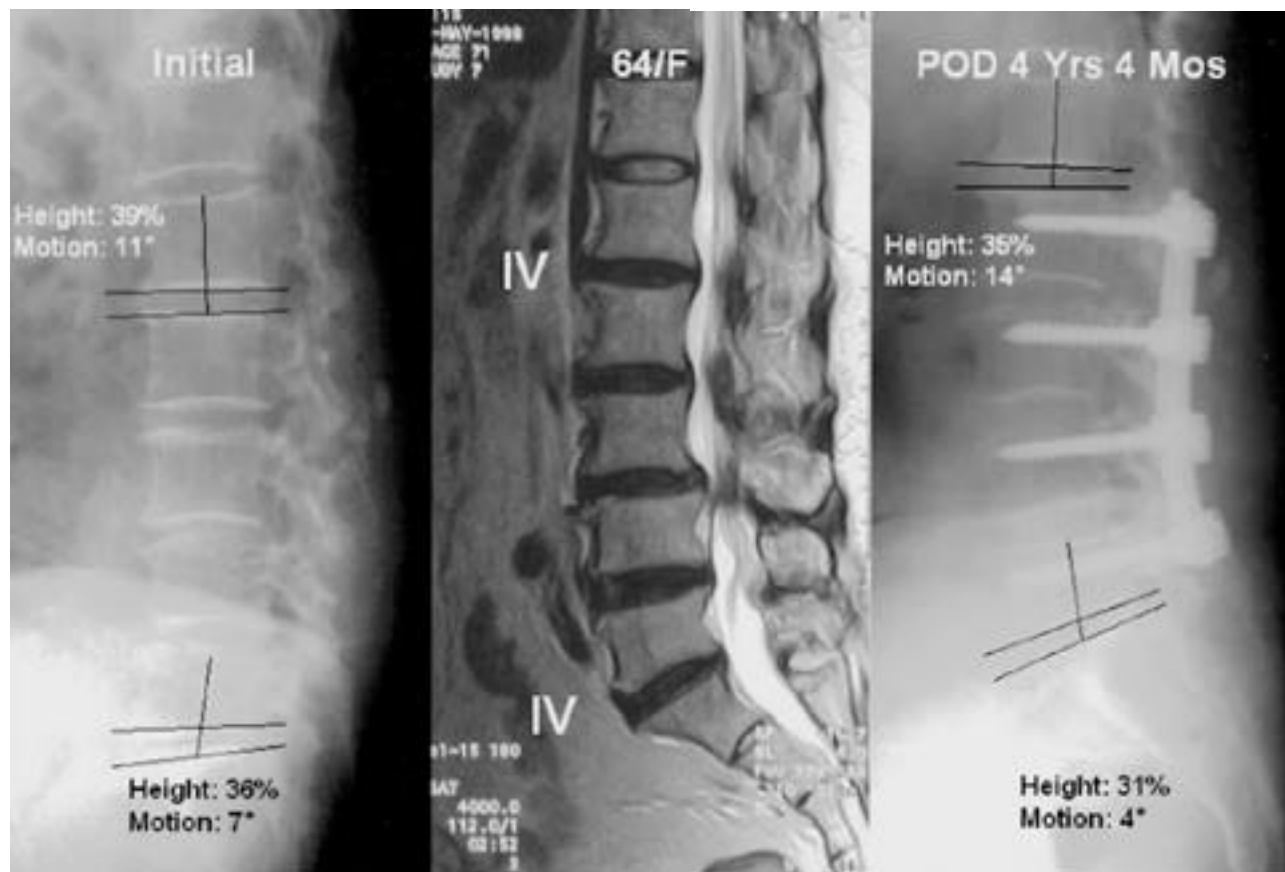
가 (P=0.046)(Fig. 5).



**Fig. 5.** Disc height change according to disc degeneration (MRI grade)



**Fig. 6.** Angular motion change according to disc degeneration (MRI grade)



**Fig. 7.** 65-year-old woman with degenerative lumbar scoliosis shows less changes of the disc space ratio and the angular motion in the upper & lower adjacent segments after follow-up 5 years 2 months (MRI grade- upper: IV, lower: III).

3. (P=0.819)(Fig. 6).

grade III

$-0.2 \pm 4.9^\circ$ , grade IV

$-0.4 \pm 1.5^\circ$

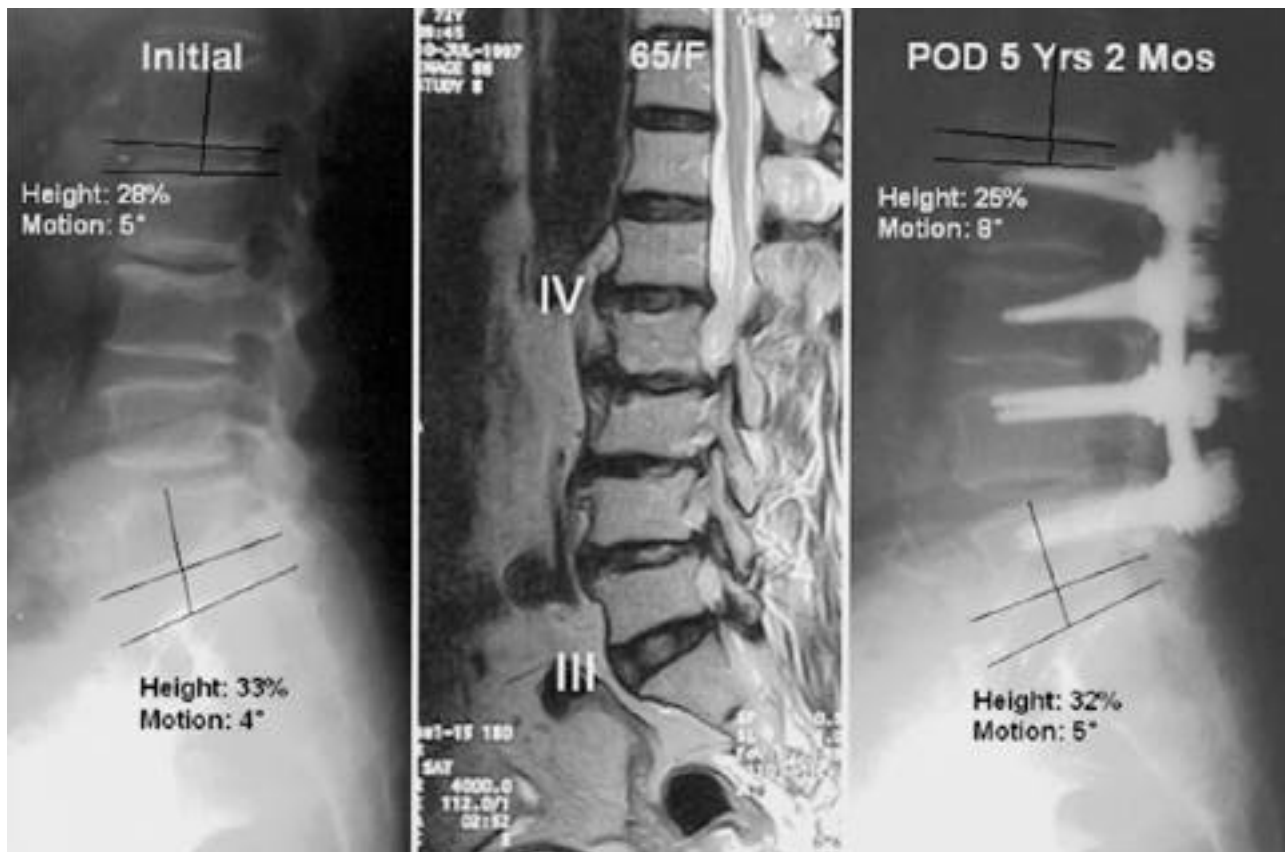
(P=0.208)(Fig. 6).

가 grade III

$-0.2 \pm$

$2.2^\circ$ , grade IV

$0.6 \pm 4.2^\circ$



**Fig. 8.** 64-year-old woman with degenerative lumbar scoliosis shows decreased changes of the disc space ratio in the upper & lower adjacent segments and less changes of the angular motion in the upper & lower adjacent segments after follow-up 4 years 4 months (MRI grade- upper: IV, lower: IV).

**Table 2.** Postoperative instability.

Upper level instability	Gr I-III	Gr IV-V
Yes	0	2
No	11	3

p=0.083(Fisher's exact test)

Lower level instability	Gr I-III	Gr IV~V
Yes	0	0
No	11	5

p=1.000(Fisher's exact test)

(Table 2).

grade IV

(Table 2).

grade III

5

11

(P=1.000)

가

4.

가

가

가

가

grade III

11

, grade IV

5

2

(P=0.083)

3

가

가 가 L5-S1 MRI

가 가 . Horton , ,

<sup>8)</sup> L5-S1  
75~90%

T2-weighted MRI

가 가 L5-S1  
, L5-S1 Brodsky <sup>2)</sup>

가 64%,  
59.6%가  
(2.7%)

L5-S1 가 L5-S1  
가 , Moskowitz <sup>11)</sup>

. Cochran <sup>4)</sup> 5  
89% , 73%  
, L5-S1

Frymoyer <sup>7)</sup>, Friberg <sup>6)</sup>, <sup>9)</sup>

grade IV

MRI 가 grade IV 가 가

, Holt <sup>8)</sup> L5-S1 <sup>3)</sup>  
가 , 가

, ,

L5-S1

S1 가

(lever arm) (pull out  
force) 가 가

, Aota  
25.5%, 2.6%  
, Lehmann <sup>10)</sup> Quin-  
nell Stockdale<sup>13)</sup>

가

가

가

16  
가 grade IV 2  
1 , junctional kyphosis

Pfarrmann <sup>12)</sup> 1 ) 가 ,

, T2-weighted MRI가

MRI  
 ,  
 , grade IV  
 ,  
 가 ,  
 가 .  
 ,  
 가 MRI  
 grade III 2  
 가 .  
 가 가  
 , 가

## REFERENCES

- 1) Aota Y, Kumano K and Hirabayashi S : *Postfusion instability at the adjacent segments after rigid pedicle screw fixation for degenerative lumbar spinal disorders. Journal of spinal disorders*, 8:464-473, 1995.
- 2) Brodsky AE, Hendricks RL, Khalil MA, Darden BV and Brotzman TT : *Segmental(" Floating ") lumbar spine fusions. Spine*, 14:447-450, 1989.
- 3) Cho KJ, Lee JY and Oh IS, et al. : *Change of segmental motion after lumbar posterolateral fusion. J of Korean Orthop Assoc*, 34:281-287, 1999.
- 4) Cochran T, Irstam L and Nachemson A : *Long-term anatomic and functional changes in patients with adoles - cent idiopathic scoliosis treated by Harrington rod fusion. Spine*, 8:576-583, 1983.
- 5) Dupuis PR, Yong-hing K, Cassidy JD and Kirkaldy-Willis WH : *Radiologic diagnosis of degenerative lumbar spinal instability. Spine*, 10(3):262-276, 1985.
- 6) Friberg S and Hirsch C : *Anatomical and clinical studies on lumbar disc degeneration. Acta Orthop Acand*, 19:222-242, 1949.
- 7) Frymoyer JW, Hanley EN, Howe J, Kuhlmann D and Matteri RE : *A comparison of radiographic findings in fusion and nonfusion patients ten or more years following lumbar disc surgery. Spine*, 4:435-440, 1979.
- 8) Horton WC, Holt RT and Muldowny DS : *Controversy fusion of L5-S1 in adult scoliosis. Spine*, 21:2520-2522, 1996.
- 9) Kim HT, Park BH, Cheon DW, An HS and Lee HS : *A comparative study of the floating(L4-5) vs lumbosacral (L4-S1) spinal fusions. J of Korean Orthop Assoc*, 29:1151-1159, 1994.
- 10) Lehmann TR, Spratt KF, Tozzi JE, et al. : *Long-term follow-up of lower lumbar fusion patients. Spine*, 12:97-104, 1987.
- 11) Moskowitz A, Moe JH, Winter RB, et al. : *Long-term follow-up of scoliosis fusion. J Bone Joint Surg*, 62-A:364-376, 1980.
- 12) Pfirrmann CWA, Metzdorf A, Zanetti M, Hodler J and Boos N : *Magnetic resonance classification of lumbar intervertebral disc degeneration. Spine*, 26:1873-1878, 2001.
- 13) Quinnell RC and Stockdale HR : *Some experimenatal observations of the influence of a single lumbar floating fusion on the remaining lumbar spine. Spine*, 6:263-267, 1981.



:  
 : 5 MRI  
 가  
 : 1996 7 2000 2 5  
 22 , 2 가 16 5 , 11 , 64  
 (57~74), 41 (28~59) .  
 가 MRI (Modified Pearce  
 classification) , , - ;  
 (angular motion)  
 :  
 가 grade IV  
 가 (P=0.649),  
 가 (P=0.046).  
 (P=0.819, P=0.208).  
 2  
 (P=0.083, P=1.000).  
 :  
 MRI 가 grade III , 가  
 가 가 , 가

: , , ,

:  
 24-14

Tel : 82-42-259-1286, Fax : 82-42-252-5498, E-mail : ortho@hananet.net