

## Erratum to: A Case of Rapidly Progressive Primary Sclerosing Cholangitis Requiring Liver Transplantation

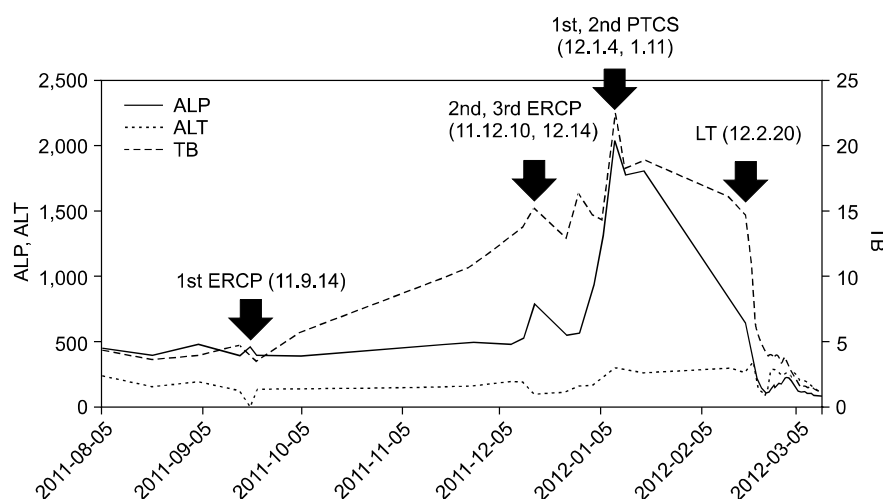
Tae Seop Lim, M.D.<sup>1</sup>, Jun Yong Park, M.D.<sup>1</sup>, Soon Il Kim, M.D.<sup>2</sup>,  
Huapyeong Kang, M.D.<sup>1</sup> and Moon Jae Chung, M.D.<sup>1</sup>

Department of Internal Medicine, Yonsei Institute of Gastroenterology<sup>1</sup>, Department of Surgery, Research Institute for Transplantation<sup>2</sup>, Yonsei University College of Medicine, Seoul, Korea

J Korean Soc Transplant 2013;27:24-28 | <http://dx.doi.org/10.4285/jkstn.2013.27.1.24>

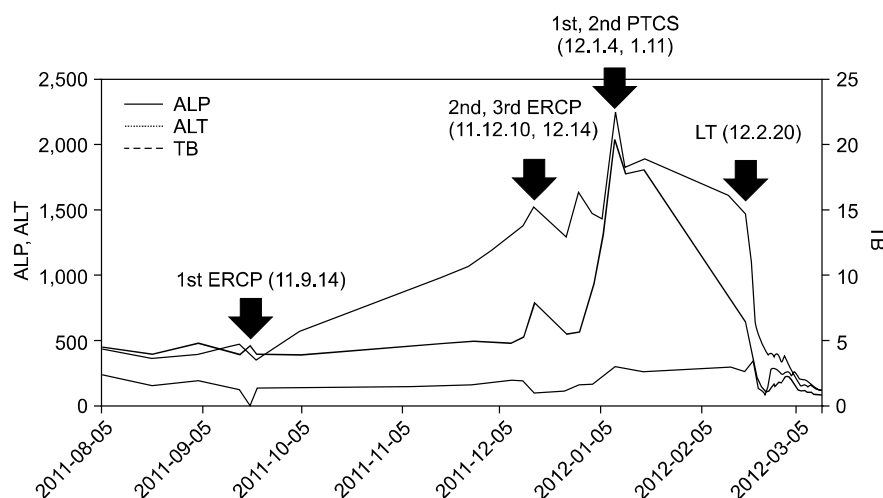
This is the correction about the article of Lim et al. (J Korean Soc Transplant 2013;27:24-8). An printing error was identified in the figure of the above article as follows.

The corrected figure is shown here:



**Fig. 3.** The trend of total bilirubin, alkaline phosphatase, and alanine aminotransferase (ALT) was described. Abbreviations: PTCS, percutaneous transhepatic cholangioscopy; ERCP, endoscopic retrograde cholangiopancreatography; LT, liver transplantation; ALP, alkaline phosphatase; TB, total bilirubin.

The originally published figure is also shown for reference:



**Fig. 3.** The trend of total bilirubin, alkaline phosphatase, and alanine aminotransferase (ALT) was described. Abbreviations: PTCS, percutaneous transhepatic cholangioscopy; ERCP, endoscopic retrograde cholangiopancreatography; LT, liver transplantation; ALP, alkaline phosphatase; TB, total bilirubin.

We express sincere apologies for any inconvenience caused by these errors.