

Severe Crescentic BK Nephropathy: A Case Report

Division of Nephrology, Department of Internal Medicine, Presbyterian Medical Center¹, Jeonju,
Department of Pathology², Division of Nephrology, Department of Internal Medicine³,
Seoul St. Mary's Hospital, College of Medicine, The Catholic University of Korea, Seoul, Korea

Hyun Ju Yoon, M.D.¹, In O Sun, M.D.¹, Min Kyung Yeo, M.D.², Byung Ha Chung, M.D.³,
Yeong Jin Choi, M.D.², Chul Woo Yang, M.D.³ and Kwang Young Lee, M.D.¹

A 44-year-old man was admitted for evaluation of asymptomatic graft dysfunction. An allograft biopsy revealed diffuse interstitial infiltration of lymphocytes (i3) with moderate tubulitis (t3) and SV40-positive renal tubular epithelial cells. The patient was diagnosed with BK virus nephropathy, and immunosuppression was modified with discontinuing mycophenolate and reducing tacrolimus. Leflunomide treatment was also started simultaneously. However, serum creatinine increased to 3.0 mg/dL; therefore, the patient underwent a second allograft biopsy, in which the crescent was no longer evident but tubulitis (t2) and fibrosis (i2) persisted. On day 20, leflunomide was switched to ciprofloxacin due to leukopenia. The serum creatinine increased to 3.3 mg/dL, and the third biopsy showed slightly improved tubulitis and interstitial inflammation. We then administered an intravenous infusion of immunoglobulin. On day 70, the renal function was stable and the BK serum viral load was low, and the patient was discharged. This is a case of severe crescentic BK nephropathy with successful outcome treated with aggressive treatment and this method will be useful in renal transplant patients.

Key Words: Polyomavirus, Glomerular, Kidney transplantation

중심 단어: 폴리오마바이러스, 사구체, 신이식

INTRODUCTION

The BK virus, a DNA virus from the *Polyomavirus* group, causes opportunistic infection of immunosuppressed transplant recipients. BK viremia and nephritis are increasingly problematic in renal transplant recipients. Primary infection is usually asymptomatic, and reactivation of the virus in renal transplant patients occurs because of severe immunosuppression or altered cellular immunity(1). Approximately 30%~60% of renal grafts with BK virus-associated nephropathy (BKVAN) develop progressive graft loss. Histological

findings are correlated with viruria, viremia, and graft survival, which depend on the degree of interstitial inflammation, tubulitis, and fibrosis. The presence of viral cytopathic changes in the glomeruli has also been associated with poor prognostic value(2). We report an unusual case of BKVAN with crescent formation that was treated aggressively with reduction of immunosuppressants, leflunomide, ciprofloxacin, and intravenous immunoglobulin (IVIG).

CASE REPORT

A 44-year-old man was admitted for evaluation of asymptomatic graft dysfunction (serum creatinine level of 2.2 mg/dL). His original renal disease was diagnosed as chronic glomerulonephritis, although a renal biopsy was not performed. He received a deceased donor kidney transplantation 14 months previously and had maintained a stable

Received August 21, 2015

Revised November 27, 2015

Accepted December 1, 2015

Corresponding author: Kwang Young Lee

Division of Nephrology, Department of Internal Medicine, Presbyterian Medical Center, 365 Seowon-ro, Wansan-gu, Jeonju 54987, Korea
Tel: 82-63-230-1331, Fax: 82-63-230-1339
E-mail: kwangpmc@hanmail.net

serum creatinine level (0.9~1.3 mg/dL) during the follow-up period. He had received triple immunosuppressive therapy of tacrolimus, mycophenolate mofetil, and prednisolone. On admission, Doppler ultrasonography performed to evaluate graft function showed favorable renal perfusion in the transplanted kidney. The tacrolimus trough level was 7.4 ng/mL, and polymerase chain reaction assays of urine and serum showed that BK viral load in the urine was elevated significantly at 5.0×10^8 copies/mL, and the serum viral load was 7.9×10^7 copies/mL. We previously tested screening for quantitative BKV DNA in plasma at 1, 3, and 6 months that showed low viral load ($<10^4$ copies/mL).

An allograft biopsy was performed on the day of admission. The biopsy supplied two cores of renal tissues, including nine glomeruli. The biopsy finding revealed diffuse interstitial infiltration of lymphocytes (i3) with moderate tubulitis (t3) and SV40-positive renal tubular epithelial cells. Moreover, there were evident cytopathic changes in the epithelial parietal cells of the Bowman's capsules, which were piled to form cellular crescents in two glomeruli. Based on these findings, the patient was diagnosed with BK virus nephropathy, and immunosuppression was modified with discontinuing mycophenolate and reducing tacrolimus (3~5 ng/mL). Leflunomide treatment was also started simultaneously. However, serum creatinine increased to 3.0 mg/dL on day 14, and so the patient underwent a second allograft

biopsy, in which the crescent was no longer evident but tubulitis (t2) and fibrosis (i2) persisted. On the day 20, we switched leflunomide to ciprofloxacin due to leukopenia. With these treatments, the serum creatinine increased to 3.3 mg/dL, and so a third biopsy was done on day 38. Compared to the previous allograft biopsy, the third biopsy showed slightly improved tubulitis and interstitial inflammation (Fig. 1). We then administered an intravenous infusion of immunoglobulin at a dose of 2 g/kg divided for 5 days. On day 70, the renal function of the patient was stable (serum creatinine 2.8 mg/dL) and the BK serum viral load was low (<150 copies/mL), and the patient was discharged (Fig. 2). Eight months after treatment for BKVAN, his renal function was stable (serum creatinine 2.9 mg/dL).

DISCUSSION

BK virus infection is currently one of the most common infectious complications in renal transplant recipients. The level of renal dysfunction, defined as serum creatinine >2.2 mg/dL at the time of diagnosis of BKVAN, the renal histological feature of moderate to severe fibrosis on biopsy, and peak serum BK viral load above 100,000 copies/mL have been correlated with poorer long-term graft survival(2,3). In our case, the serum creatinine level was more than 2.2 mg/dL at the time of biopsy, peak serum BK viral load was 7.9×10^7

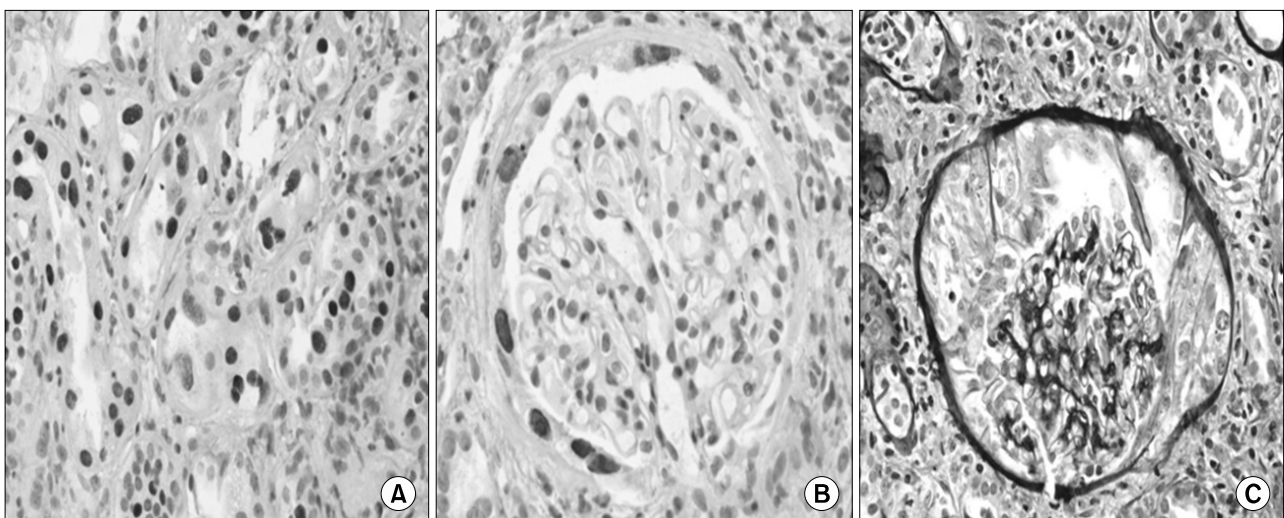


Fig. 1. First renal allograft biopsy findings ($\times 400$). SV40-positive cells are present in both (A) tubular and (B) parietal glomerular cells. (C) A glomerulus with a crescent was also evident.

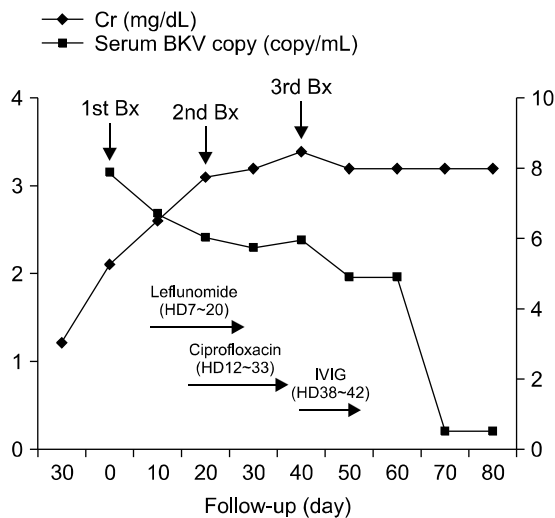


Fig. 2. Clinical course. The patient was admitted because of graft dysfunction. We initially reduced the tacrolimus and discontinued mycophenolate. In addition, we used leflunomide, ciprofloxacin, and intravenous immunoglobulin. After treatment, serum creatinine decreased to 3.2 mg/dL and BK serum viral load was low. Abbreviations: BKV, BK virus; HD, hospital day; IVIG, intravenous immunoglobulin; Bx, biopsy.

copies/mL, the result of graft biopsy was t3, i3, ct2, ci2 and the histological pattern was polyomavirus-associated nephropathy B3, which were predictive of poor graft outcome. Moreover, infection of glomerular epithelium cells, including piling to form crescents, was observed in our case. Therefore, our patient had several risk factors associated with poor prognosis of BKVAN.

In general, medullary collecting ducts and distal tubules are affected early in the evolution of BK virus nephropathy, and glomerular changes may also be detected during this time. Glomerular changes in BKVN develop in cases of high viral load in the tubular epithelium. Celik and Randhawa(4) reported that glomerular changes and crescents were found in 17% and 12% of samples, respectively. Our finding of crescent formation suggested two possibilities for our case. First, we assumed that this subject might have severe crescentic BK virus nephropathy. Second, we considered another possibility of the recurrence of underlying native kidney disease. Accordingly, we obtained a second biopsy 2 weeks later to verify rapidly progressive glomerulonephritis when renal function was aggravated. The crescent formation was not detected in the second allograft biopsy. There has been

no previous case report of rapidly progressive glomerulonephritis, even in cases of crescentic BK nephropathy. Based on the second biopsy, we confirmed that the patient had severe BK nephropathy with crescent formation.

The management of BK virus infection includes reducing immunosuppression alone and reducing immunosuppression as well as antiviral therapies such as cidofovir or leflunomide(1). However, there are no specific guidelines for treating severe crescentic BK nephropathy. Celik and Randhawa(4) reported that patients with glomerular infection in BK virus nephropathy had an unfavorable outcome compared with patients without infection. Accordingly, we think that aggressive therapy is warranted for crescentic BK nephropathy. Mazzucco et al.(5) reported a case of severe crescentic BK virus nephropathy treated with leflunomide. In our case, we also initially used leflunomide; however, we switched to ciprofloxacin due to leukopenia. We also administered IVIG(1). The patient maintained relatively stable renal function with IVIG therapy. Thus, we think that such aggressive therapy could be helpful in treating severe crescentic BKVAN.

In summary, we report an unusual case of BK nephropathy with crescent formation that was treated with an intensive strategy including reduction of immunosuppressants and administration of leflunomide, ciprofloxacin, and IVIG. Aggressive treatment using multiple drugs could be helpful for the treatment of severe crescentic BK nephropathy.

REFERENCES

- 1) Dall A, Hariharan S. BK virus nephritis after renal transplantation. *Clin J Am Soc Nephrol* 2008;3 Suppl 2:S68-75.
- 2) Hariharan S. BK virus nephritis after renal transplantation. *Kidney Int* 2006;69:655-62.
- 3) Schwarz A, Linnenweber-Held S, Heim A, Brocker V, Rieck D, Framke T, et al. Factors influencing viral clearing and renal function during polyomavirus BK-associated nephropathy after renal transplantation. *Transplantation* 2012; 94:396-402.
- 4) Celik B, Randhawa PS. Glomerular changes in BK virus nephropathy. *Hum Pathol* 2004;35:367-70.
- 5) Mazzucco G, Costa C, Bergallo M, Segoloni GP, Monga G. Severe crescentic BK virus nephropathy with favourable outcome in a transplanted patient treated with leflunomide. *Clin Nephrol* 2008;70:163-7.