

Advances in Percutaneous Nephrostomy

Won Jay Lee

Management of urologic patients is being gradually but dramatically altered with new advances in technical innovation and refinements of interventional urology. The broadening of indications for percutaneous nephrostomy became possible only after it was learned that it is a safe and effective means of establishing access to the renal collecting system. Percutaneous stone extraction (Nephrolithotomy) and Endopyelotomy are now well established procedures. These techniques have clear advantages over the surgical treatment for the same conditions and will increase the quality of patient care and reduce health care cost.

Key Words: Percutaneous nephrostomy, endopyelotomy, percutaneous nephrolithotomy, percutaneous pyelotomy

Since Goodwin and associates used a needle trocar in 1955 for the decompression of an obstructed kidney (Goodwin *et al.* 1955), the percutaneous management of various renal diseases has remained. However, it was not until the early 1970s that percutaneous urinary drainage gained popularity. By the late 1970s, percutaneous nephrostomy drainage was the treatment of choice for patients with obstructive uropathy. It supplanted the surgical treatment of these problems. Today, percutaneous nephrostomy and other related renal procedures are routine in most hospitals. This technique provides safe, rapid and direct access to the upper urinary tract for various diagnostic and therapeutic maneuvers (Banner and Pollack, 1984; Barbaric 1986; Lee *et al.* 1987). It has become a vital tool for the interventional urologists and urologists who have been able to diagnose and treat ever more diverse pathologies of the urinary tract without open operation (Brannen *et al.* 1988; Huffman *et al.* 1985; Kadir *et al.* 1982; Karlin *et al.* 1987; Lang 1984; Lee *et al.* 1987). Although a definite learning curve exists, once mastered, these techniques have proved themselves as safe and reliable methods providing morbidity and economic losses. Percutaneous nephrostomy has been safely and successfully performed in age groups ranging from infancy to geriatric patients (Ball *et al.* 1986; Lee and Smith 1987; Schiff and Lee 1986; Stable 1982).

Initially, the majority of percutaneous nephrostomies was performed for decompression of obstructed urinary tracts. With refinement and advancement of instruments and techniques, more complex problems of stone disease, ureteropelvic junction obstruction, and transitional cell carcinoma of the renal pelvis have been managed percutaneously (Lang 1984; Lee *et al.* 1985; Ortiz and Lee 1989; Orihuela and Smith 1988).

Radiologists have long played an integral role in caring for patients with urinary tract diseases, by obtaining and interpreting diagnostic studies which, in large measure, guide patient management. With the refinement of interventional urological techniques in the early 1980's, the radiologist's role expanded. Radiologists became an important part of a team that managed the patients with symptomatic upper urinary tract calculi percutaneously. The advent of nephroscopic procedures via percutaneous nephrostomy has initiated multiple new techniques for approaching the kidney and ureter.

This article will review recent advances in percutaneous nephrostomy procedures, based on our experience of more than 1,500 cases over an eight-year period. The methods for creating percutaneous access, the endopyelotomy, and the management of complex renal stones will be reviewed.

Indications

Table 1 outlines the principal indications for placement of percutaneous nephrostomy. Although these procedures are performed for a variety of reasons, pro-

Received September 4, 1990

Department of Radiology, Long Island Jewish Medical Center,
Albert Einstein College of Medicine, New Hyde Park, N.Y. 11042
U.S.A.

Table 1. Indications for percutaneous nephrostomy

| | |
|--------------|--|
| Diagnostic | :Antegrade imaging of the urinary tract |
| | Pressure perfusion studies (Whitaker test) |
| | Evaluation of kidney function and recoverability |
| | Endoscopic inspection of the renal collecting system |
| Therapeutic: | Temporary drainage for obstruction and sepsis |
| | * Primary obstruction (UPJ or UV) obstruction, bladder neck) |
| | * Secondary obstruction (postoperative, pelvic/retroperitoneal malignancy) |
| | Diverts urine flow to control fistulae and ureteral extravasation |
| | Access to the kidney |
| | * Percutaneous placement of ureteral stents |
| | * Percutaneous stone extraction/dissolution |
| | * Endopyelotomy |
| | * Management of transitional cell carcinoma |
| | * Fungus balls (removal and irrigation) |
| | * Foreign body removal (eg. broken stent) |

bably the most frequent indication is temporary decompression of urinary obstruction. Suspected infection of an obstructed urinary tract is an important indication for percutaneous nephrostomy. Septicemia may resolve dramatically when adequate drainage is achieved. Nephrostomy is for decompression of an obstructed urinary tract, as well as diagnosis and therapy of various renal and ureteral lesions (Lee 1989; Smith and Lee 1983). Percutaneous drainage diverts the urine flow to control fistulae and provides access for further manipulations such as dilatation of strictures (balloon or endopyelotomy), placement of stents in the ureter, and removal of urinary tract stones. More recently, transitional cell carcinomas of the renal pelvis have been managed percutaneously (Orihuela and Smith 1988).

Ureteral stenoses secondary to previous stone manipulation and postoperative stricture can be dilated and stented with the catheter technique (Mitty *et al.* 1982). Traumatic ureteral disruption and fistulae may also be managed with antegrade ureteral stenting, even when attempted retrograde stenting has failed.

Contraindications

Coagulation abnormalities represent a relative contraindication and, if possible, should be corrected before the procedure. Patients with bleeding tendencies, including those who are taking anticoagulants, are not good candidates for endourologic procedures until their clotting parameters are brought within normal limits. Certainly, this does not apply to simple

nephrostomy for decompression, since the injury to the kidney is minimal. Renal neoplasms or arteriovenous malformations should not be traversed percutaneously.

If at all possible, one should avoid percutaneous manipulations of an infected urinary tract, other than for decompression; however, there may be no choice, given the familiar difficulty of eradicating an infection in the presence of a stone. In such cases, beginning the day before the procedure, the patient should be given an appropriate antibiotics parenterally (Lee *et al.* 1987). It is particularly important in these patients not to overdistend the renal collecting system with contrast or irrigating fluid because overdistension may lead to septicemic shock. If a perinephric abscess is encountered, a drainage catheter should be left within the infected space.

Contrary to general belief, manipulations via a percutaneous nephrostomy are not contraindicated in the patient with a solitary kidney (Lee *et al.* 1986).

ANATOMY OF THE KIDNEY

Although radiologists and urologists are generally familiar with renal anatomy, certain specific elements are especially pertinent to the percutaneous nephrostomy (Ford and Weinerth 1985). A thorough three-dimensional comprehension of renal anatomy is critical to the successful placement of a percutaneous nephrostomy tube. The relationship of the kidneys to both intra-abdominal and thoracic structures must be understood. The more important

aspects of renal anatomy will briefly be reviewed.

Axis

The kidneys are situated in the retroperitoneum between the 12th thoracic and the second or third lumbar vertebrae with the right kidney lying 2 to 3 cm lower than the left. The upper pole of the kidney is more medial and posterior than the lower pole, creating an angle of 13 degrees with the sagittal plane. The left kidney is slightly closer to the midline. The concavity of the renal hilum is anterior with respect to the convexity of the lateral border, so that the kidney is angled 30 degrees posterior in the coronal plane.

Relations

The relationship between the kidney and the posterior abdominal wall is important because percutaneous access to the kidney must be through the posterior abdominal wall. In addition, the 12th rib crosses the kidney at a 45 degree angle. The nephrostomy should be placed below the 12th rib whenever possible. However, optimal access may require placement of nephrostomy above the 12th rib. Although any puncture above the 12th rib carries a risk of entering the pleural space, we do not hesitate to place a nephrostomy catheter there. If a nephrostomy must be placed between the 11th and 12th, it should be placed as close to the superior border of the 12th rib in order to avoid vascular and nerve structures along the inferior margin of the 11th rib. If possible, puncture above the 11th rib should be avoided.

The retroperitoneal space is primarily involved during the procedure. Computed Tomography clearly defines retroperitoneal anatomy and adjacent abdominal organs. In their normal position, anterolateral to the kidney, the liver, spleen, pancreas, duodenum and colon are located a safe distance away from the path of the nephrostomy catheter. Any variation that places these organs in a more posterolateral location increases the chance that they may be injured during the nephrostomy procedure. Therefore, we routinely obtain abdominal radiograph prior to the procedure. In very unusual cases, CT may be necessary to ensure the safest path for the nephrostomy.

Renal Anatomy

The kidney itself is covered with a true capsule of tough, fibrous tissue, intimately associated with the underlying parenchyma. This capsule contains multi-

ple capillaries and sensory nerves. Therefore, puncture of the capsule is usually associated with some sensation of pain and is resistant to stretching. Calyceal anatomy varies individually. Fusion of the septal cortex of individual calices in the polar regions of the kidney during renal development results in compound calyces.

Because the coronal plane between the anterior and posterior groups of lobes of the kidney falls on the posterolateral aspect, with the renal hilum directed anterior, and because the position of the psoas major muscle causes the kidney to rotate posterolaterally, there is a characteristic calyceal pattern on the intravenous urogram. The majority of the kidneys confirm to the pattern when the anterior calices are seen side-on and laterally, whereas the posterior calices are seen end-on and medially. Normally, the anterior calyx is 20 degrees and the posterior calyx 70 degrees from the coronal plane (Kaye and Reinke 1984).

Arterial Supply

One must know the blood supply of the kidney to avoid major vessels during renal access and manipulation. The main renal artery is an end artery (Fig. 1). Its two main branches are the posterior and the anterior divisions. The anterior division gives rise to four segmental arteries (apical, upper, middle, and lower); after traversing the renal sinus these divide into interlobar branches which course along the sides of the renal pyramids, becoming arcuate arteries at the level of the corticomedullary junction. The small interlobular branches of the arcuate artery emerge at right angles from their origin. The posterior division of the renal artery crosses the posterior aspect of the proximal upper infundibulum or the upper renal pelvis and branches into interlobar arteries. It is important to note that the risk of causing significant bleeding decreases when the calyx is entered end-on, thus disturbing only the small interlobar vessels. (Kaye and Reinke 1984) The risk of damage to the arcuate and interlobar vessels increases with a medial approach.

PERCUTANEOUS NEPHROSTOMY

Percutaneous nephrostomy tube placement had become entirely a radiological procedure and the key to the subspecialty of interventional urology and Endourology. Most percutaneous nephrostomies are performed under fluoroscopic guidance and, occasionally, with ultrasonic control. Presently, it is a commonly performed procedure in most hospitals. The

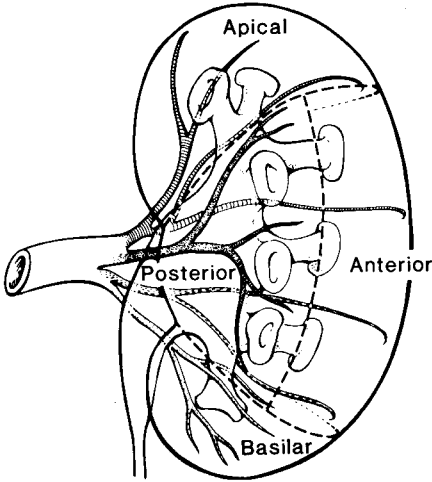


Fig. 1. Arterial anatomy of left kidney in relation to the renal pelvis and calyces. Note the close proximity of segmental arteries to the infundibulae. (see text) The anterior calyces are seen side on and laterally, whereas the posterior calyces are seen end on and medially.

use of percutaneous nephrostomy has markedly reduced the need for open surgery with associated morbidity and mortality.

Preoperative Evaluation

Prior to the procedure, the patient is checked for bleeding tendencies, urinary infections, and general medical clearance. Proper patient positioning and a basic knowledge of renal anatomy are required prior to embarking on these procedures.

Patient Positioning and Localization Puncture

A percutaneous nephrostomy tract may be created with the patient under local anesthesia in the radiology suite. The patient is placed prone on a C-arm fluoroscopy unit, and skin over the appropriate flank is cleansed with antiseptic solution and sterilely draped. (Fig. 2) If renal function is adequate, the collecting system may be opacified by the administration of intravenous contrast material. However, in most circumstances, we prefer an antegrade pyelogram for adequate delineation of the pelvis and caliceal system. An antegrade pyelogram is easily performed from a

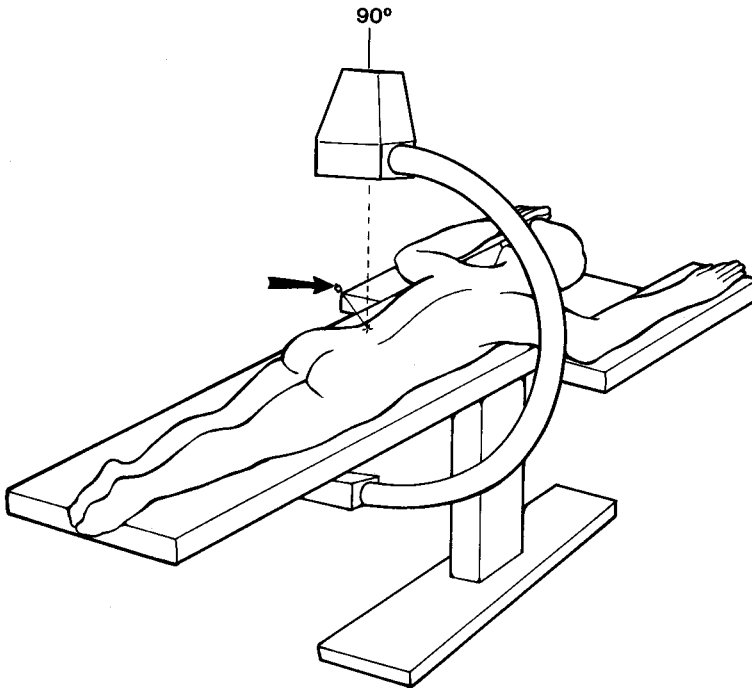


Fig. 2. Proper patient positioning and C-arm fluoroscopy.

The C-arm is rotated to 115 degrees so that the tip of the nephrostomy puncture needle (arrow) is superimposed on the desired calyx. Advancement of the needle is along a plane that traverses Brodel's line (avascular plane). The depth of penetration is checked by rotating the C-arm to 90 degrees.

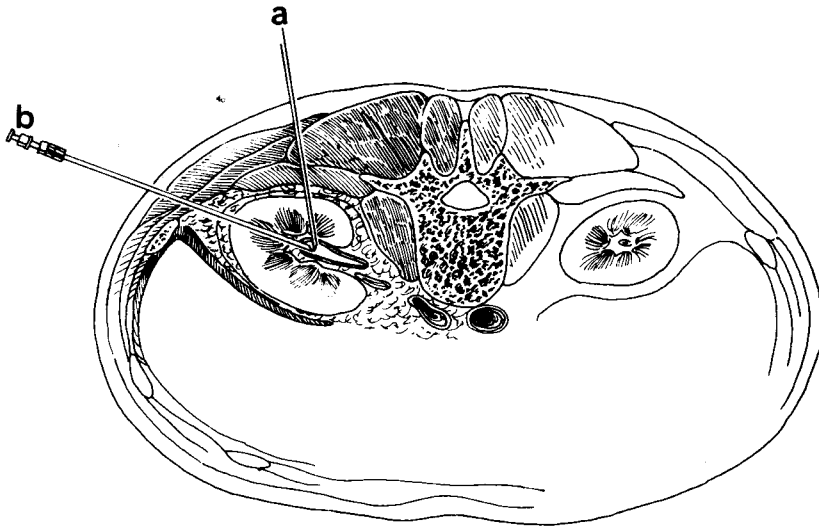


Fig. 3. Nephrostomy access created through a posterior calyx at the posterior axillary line.
 (a) Direct posterior approach for the antegrade pyelogram.
 (b) Definitive nephrostomy puncture. Note posterolateral needle approach.

direct posterior approach (Fig. 3). No local anesthesia is used unless repeat punctures are required. A 21-gauge thin-walled needle is passed vertically through the anticipated position of the renal pelvis (usually 4 finger breath lateral to the spine, below the 12th rib), while the patient suspends respirations. One can feel two "pops", the first representing the renal capsule and the second representing the collecting system. The stylet is removed, and a 10ml plastic syringe is connected to the needle. Gentle aspiration is applied as the needle is withdrawn. The volume of removed urine is replaced with 25% contrast medium. Overdistention of the collecting system may result in septicemia. After the collecting system has been visualized, the percutaneous nephrostomy is performed. We have used fluoroscopy exclusively, because we believe it gives more detailed information about caliceal anatomy and the site of pathology, and permits more accurate puncture.

Puncture Site Selection

The importance of selecting the proper percutaneous nephrostomy tract for the planned procedure must not be underestimated. In nearly all cases, the preferred approach is via posterior calyx. In comparison with the direct posterior approach used for the antegrade pyelogram, a posterior lateral approach

is used for percutaneous nephrostomy because (1) the major vascular structures surrounding the renal pelvis are avoided; (2) the transparenchymal course stabilizes the catheter in appropriate position; (3) it is easy to use standard instruments; and (4) it is more comfortable for the patient.

Our techniques of percutaneous nephrostomy access, tract dilatation, and various manipulative procedures, have been described previously (Lee *et al.* 1987; Lee and Smith 1987; Lee *et al.* 1985; Lee *et al.* 1987; Lee *et al.* 1986). Besides, topic is beyond the scope of this article. Several important points will be emphasized. First, the position of the kidney in the retroperitoneum is lower in children than adults. This fact facilitates safe puncture of the upper pole calyx while reducing the risk of thoracic complications in the child. Second, anterior (lateral) approaches are associated angles between the tract and the infundibulum that are difficult to traverse with instruments. They also carry an increased risk of inducing renal parenchymal and vascular trauma because of the length of the nephrostomy tract and of perforation of laterally situated viscera. The third point is that supracostal punctures should be performed with caution because of the 10% incidence of hydrothorax/pneumothorax. Recently, we have been able to mobilize the kidney caudad by creating a lower pole nephrostomy tract and, via a Y tract, using the working sheath in the lower

nephrostomy tract, applying downward traction on the kidney, making the upper pole more accessible (Moskowitz *et al.* 1989). Punctures directly into the renal pelvis run the risk of injury to the posterior branch of the renal artery, and the tracts created are devoid of surrounding renal parenchyma, which serves to support the nephrostomy tube and avoid extravasation.

For a simple decompression, we most commonly use a Cope nephrostomy set (Cook, Inc., Bloomington, Indiana). In the Cope system, a 21-gauge thin-walled needle is directed through the desired calyx. When urine is returned, a small amount of 25% contrast is injected to confirm the position within the collecting system. A 0.018 inch guidewire is passed through the 21-gauge needle and coiled within the renal pelvis. The 21-gauge needle is then removed and replaced with a specially designed curved polyethylene dilator with a generous side hole and a small end hole tapered to the 0.018-inch guidewire. This dilator assembly is advanced over the 0.018 inch guidewire well into the renal pelvis. A inner stylet and 0.018 inch guidewire are removed and a 0.038 inch guidewire with a 3mm radius "J" configuration at the tip is advanced through the dilator. This wire will exit the sideport into the renal pelvis. The dilator is removed leaving a guidewire. The nephrostomy tract is then dilated with serial dilators and 10-Fr. nephrostomy catheter is advanced into the renal pelvis. Once the catheter is in place, as much urine as possible is aspirated. A nephrostogram is then obtained for documentation.

Results and complications

In experienced hands, a successful procedure may be expected in 95-100 per cent of the cases. Percutaneous nephrostomy for simple decompression is easy to perform, very safe and effective. The few complications have limited generally to infection and occasional bleeding, which sometimes can be severe. However, bleeding can be controlled by percutaneous embolization after the site has been documented by a selective renal angiography (Lee *et al.* 1987).

Tract Dilatation

When nephrostomies are placed for the purpose of endourological manipulations such as endopyelotomy, stone extraction or other endoscopic procedures, the nephrostomy tract must be dilated to 24 to 34 French. Amplatz renal fascial dilators (Cook Urological, Spencer, Indiana) are used. We prefer a fascial dilating system to balloon or metallic coaxial

dilators for quick and reliable tract dilatation. The Amplatz renal dilator system consists of dilators from 6 French to 30 French and Teflon sheaths that fit over the dilators. These dilators are tapered to an 8-French Teflon catheter, adding stability of the dilating system and also minimizing inadvertent rupture of the renal pelvis. The final diameter of the tract is determined by the type of procedure to be performed. Tract dilatation should be under fluoroscopic guidance to assure a straight path, avoiding kinking of the guidewire and inadvertent perforation of the renal pelvis (Lee *et al.* 1989, Smith and Lee 1983).

ENDOPYELOTOMY

When percutaneous nephrostomy was found to provide valuable access to the urinary tract for various diagnostic and therapeutic maneuvers, attempts were made to use nephrostomy to relieve Ureteropelvic junction (UPJ) obstruction with less morbidity. The first attempts at percutaneous relief of UPJ obstruction and elsewhere in ureter made with balloon catheters, were met with mixed results (Banner and Pollack 1984; Kadir *et al.* 1982; Lang 1984).

The finding of a well-visualized and easily accessible UPJ during percutaneous endoscopic procedure made it possible to develop and refine a means of percutaneously correcting UPJ obstruction. This endoscopic incision of the UPJ with a pyelotome and stenting via the percutaneous nephrostomy tract has been termed "endopyelotomy". It is essentially a closed version of the Davis intubated ureterotomy (Davis 1943). Davis showed that the muscularis and mucosa of the ureter healed after a narrowed segment was incised and stented, and that these healed ureters were peristaltic and without adynamic dilatation. Initial reports of the success of endopyelotomy concentrated on its application to secondary UPJ obstruction.

Endopyelotomy appears to be a successful method for treating UPJ obstruction in adults. We have been able to obtain success rates of 85% in primary and 89% in secondary UPJ obstruction at our institution (Lee *et al.* 1988).

For endopyelotomy to succeed, the operator must have easy access to the UPJ with a rigid cutting instrument. Therefore, proper sitting of the nephrostomy is critical (Fig. 4).

Patient selection

The most appropriate candidates include those patients with short strictures (less than 2cm) and good

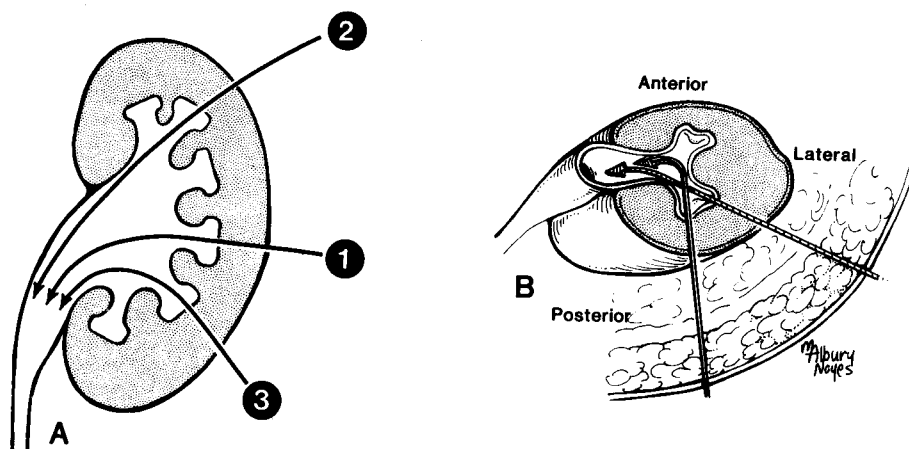


Fig. 4. A. Diagram illustrating access to UPJ. Nephrostomy tract 1 is the preferred route.

There is minimal chance of pleural perforation and good access to UPJ. Tract 2 through the upper calyx: This route is best access to UPJ, but there is a significant chance of pleural perforation. Tract 3: There is no chance of pleural perforation, but very poor access to UPJ. Use of this route is only possible in mobile kidney with no previous surgery.

B. This diagram in the supine orientation shows approaches to the kidney. To achieve a smooth curve to the UPJ (and best visibility of the UPJ for incision) the approach should be posterolateral and not from directly posterior.

[From Lee WJ, Badlani GH, Smith AD: Percutaneous nephrostomy for endopyelotomy. *AJR* 148:189-192, 1987; with permission of authors and American Roentgen Ray Society]

renal parenchyma. The caliber of the ureter should be large enough to accept a stent of at least 6 French. Therefore, endopyelotomy may not be suitable in very young children, because it is difficult to properly stent a very small UPJ. Most children over the age of 10 should be suitable candidates for endopyelotomy and should be considered if the obstruction is secondary to a previous open procedure.

Preoperative Evaluation

The preoperative evaluation of patients undergoing endopyelotomy is much the same as for those undergoing open pyeloplasty. As with any percutaneous procedure, screening for a bleeding diathesis should be performed. Documentation of anatomic ureteropelvic junction obstruction is first assessed by intravenous urography and/or retrograde pyelography. Functional obstruction is investigated with a diuretic DTPA renal scan or a Whitaker test.

Technique

The technique of endopyelotomy has been detailed by the author (Lee *et al.* 1987, Lee *et al.* 1988). The technique we now prefer for endopyelotomy begins with the retrograde placement of an open-ended ureteral catheter. Failure to pass the ureteral catheter

beyond the UPJ may be managed by retrograde passage of the ureteral guidewire. We have found a guidewire (Meditech, Inc.) useful in a tight stenosis. The patient is then placed on the operating table in the prone position, and, under C-arm fluoroscopic guidance, a percutaneous nephrostomy tract is created as described above. A straight path to the UPJ and proximal ureter is essential for subsequent vision and endoscopic manipulation. Ideally, the medial aspect of a posterior calyx in the mid pole is used, as this affords the best possible angle with which to approach the UPJ. Following the nephrostomy tract dilatation, the Storz endopyelotome is advanced under direct vision toward the UPJ following the guidewire. We have chosen the hook knife over the straight blade for incising the UPJ as it affords better visualization of the tissue being incised. Another advantage of the hooked blade rests with its ability to lift the mucosa prior to incision, and it provides better control of the incision. The UPJ is carefully inspected for pulsations of aberrant vessels, usually located anteriorly. If an open pyeloplasty has been performed previously, they may be transposed posteriorly. The incision is made on the posterolateral aspect of the UPJ down to the ureter until the normal-caliber ureter is seen through the nephroscope (Fig. 5). Once the incision is completed, the UPJ is stented. We prefer not to use a dou-

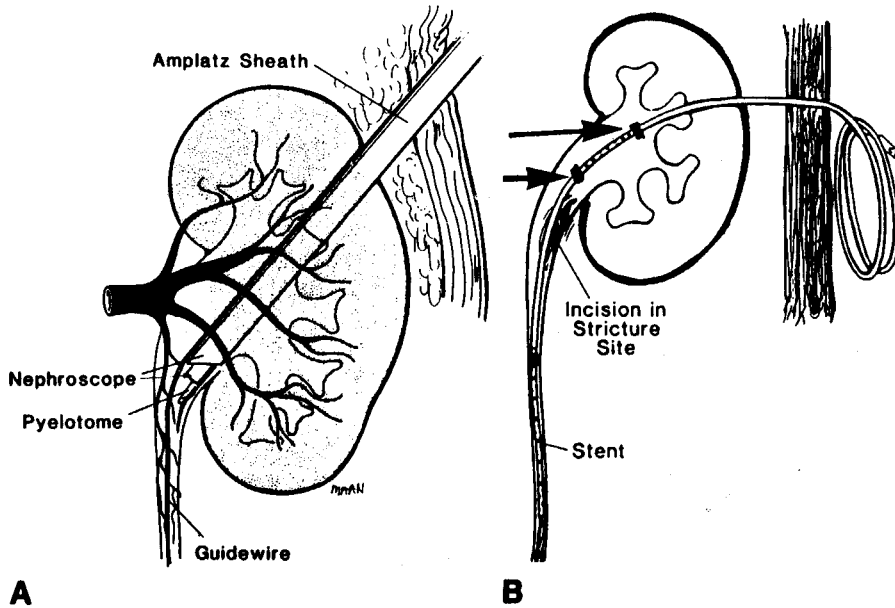


Fig. 5. Diagram of endopyelotomy

- A. Anterior view of pyelotomy. Pyelotome blade is advanced to stenotic area, and entire thickness of posterolateral wall is incised until periureteral fat is visible. The safety guidewire outside the sheath is crucial as a guide for the incision and for subsequent placement of a ureteral stent.
- B. A universal stent simultaneously keeps ureter enlarged during healing and diverts urine from surgical site. Location of renal pelvic drainage holes is shown by radiopaque markers (arrows). Distal marker (shorter arrow) should be placed above incision site in order to prevent leakage of urine into surgical field.

[From Lee WJ, Badlani GH, Karlin GS, Smith AD: Treatment of Ureteropelvic Strictures with Percutaneous Pyelotomy. *AJR* 151:515-518, 1988; with permission of authors and American Roentgen Ray Society]

ble pigtail ureteric stent because of the possibility of stent occlusion where upper end may come out through the incision site. The endopyelotomy stent has gone through numerous modifications in search of optimal stent. Initially, an 8 F universal stent was used (Smith and Lee 1983). Because of softness of this silicon stent, there is a need for an 11-F Teflon sheath peel-away introducer system (Lee and Rich 1986; Rich *et al.* 1987) (Cook Inc. Bloomington, IN). We now use a specially designed endopyelotomy stent that communicates with the exterior (Fig. 6), (Cook Urol, Bloomington, Indiana). The prototype of pediatric endopyelotomy stent is available from Cook Urological.

Postoperative studies

As with open surgery on the urinary tract, postoperative radiologic evaluation is very important.

A nephrostogram is performed within 48 hours postoperatively. If the stent is in adequate position to effect drainage and there is no extravasation, the stent is then clamped overnight, thereby converting the system to an internalized diversion. If the patient tolerates the tube clamping, the tube is coiled under a sterile dressing and the patient is discharged home. The patient returns 6 weeks later for a nephrostogram and removal of the stent from the flank. An excretory urogram is performed 3 months following stent removal to assure patency of the ureteropelvic junction. Asymptomatic patients with urograms which are unchanged from preoperative studies may represent long-standing UPJ obstruction with parenchymal atrophy. In these instances, a diuretic renal scan is performed to investigate the functional patency of the UPJ. Studies should be performed 3-6 months after the procedure and as indicated thereafter.

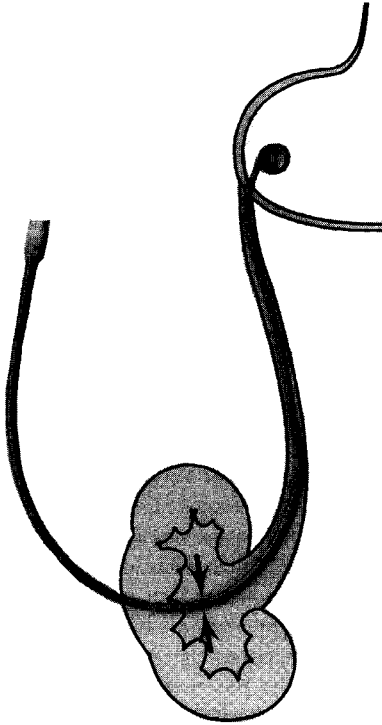


Fig. 6. Endopyelotomy stent in current use.

It is made of polyurethane and is 14 French at the ureteropelvic junction with multiple holes in the renal pelvis and has tapered tail with a single coil of 8F diameter. Radiopaque marker (arrows) indicates beginnings of drainage holes.

RESULTS

More than 262 of endopyelotomy cases have been reported in the literature. Success rates vary from 60 to 100% for primary lesion and 66-100% for secondary strictures. The success rates have been similar to those of the open pyeloplasty. We have now performed more than 130 endopyelotomy procedures. Patients fall into three major groups: 1) Congenital UPJ obstruction, 2) obstruction secondary to failed pyeloplasty, and 3) scarring of the UPJ secondary to renal surgery. Experience at our institution is an 85% success rate (39/46 patients) for primary stenosis and 89% success (67/75 patients) for secondary stenosis. The average hospital stay was six days, and the average convalescence time after discharge was 18 days. However, 26 patients returned to work in 1 week. Follow-ups on these patients range from six months to five years. All failures to date (persistence of pain and urographic evidence of continued UPJ obstruction) have been evident within three months, usually shortly after stent removal.

Complications and their prevention

In order to maintain a proper perspective on the complications of percutaneous endopyelotomy, it is important to compare them to the complications resulting from open pyeloplasty. Complications of open pyeloplasty include persistent leakage, infection,

**Table 2. Endopyelotomy complications managed by interventional techniques
(total:121 patients)**

| Complications | Number | Management |
|--|--------|----------------------------------|
| Major | | |
| * Persistent Bleeding | 1 | Immediate operative intervention |
| * Avulsion of distal ureter (transureteroureterostomy) | 1 | " |
| Pneumothorax | 2 | Chest tube insertion |
| Stent-induced ureteral stricture | 2 | Dilatation and stenting |
| Minor | | |
| Bleeding | 12 | Transfusion for hematocrit < 30 |
| Premature stent dislodgment | 2 | Immediate reinsertion |
| Significant leakage around stent | 6 | Stent repositioning |
| Stent migration or occlusion | 21 | Cleaning or replacement |
| Irritative bladder symptoms | 8 | Repositioning of stent |

* Intraoperative complications; Most stent related complications are with Universal stents which were used in our first 50 patients. Low grade fever was common after the procedure.

anastomotic disruption, urinoma formation, hemorrhage, delayed opening of the anastomosis and stone formation (Hendren *et al.* 1980). The most common postoperative complication of pyeloplasties was delayed opening of the anastomosis, which occurred in seven of 153 patients (Cromie 1983). Although endopyelotomy is subject to similar complications, the rate of complications has been very small in most reported cases.

The complications can be divided into intraoperative and late. We have encountered two major intraoperative complications in 121 adult patients, which necessitated immediate open operation: a case of ureteral avulsion and a case of bleeding.

Late complications are usually minor and associated with stent: leakage of urine around the stent, which requires stent repositioning under fluoroscopic guidance, and bladder irritation symptoms caused by stent.

Bleeding necessitating transfusion was surprisingly low (Table 2 (Lee *et al.* 1988)). In most instances, postoperative bleeding from the endopyelotomy can be easily managed by temporarily clamping the tube. This maneuver almost invariably tamponades the bleeding.

DISCUSSION

In 1955, Oppenheimer and Hinman described the ureter's ability to regenerate its wall (Oppenheimer and Hinman 1955). They found that after the ureter is incised and stented, both the mucosa and the muscularis will regenerate around the ureter wall until a full-thickness muscle coating surrounds the whole of the ureter. The endopyelotomy of today is derived from these principles. Endopyelotomy is practiced with a cold knife as opposed to a hot knife. Although there has been no objective proof that the hot knife is a cause for post incision scarring, the only two cases of endopyelotomy performed with a hot knife reobstructed with UPJ scarring evident during pyeloplasty. Approximately 80% of adolescent and adult patients presenting with UPJ obstruction may be candidates for endopyelotomy (Brannen *et al.* 1988).

The definition of success of endopyelotomy has varied from author to author and is often subjectively expressed as some combination of improvement in symptoms, and urographic and/or radionuclide renal scan findings. Whereas symptomatically improved patients with improved Excretory urographic findings may indicate improved dynamics of renal pelvic drainage, an unchanged pattern in an asymptomatic patient may

reflect an irreversible change in architecture after successful relief of obstruction, a treatment failure, or even absence of obstruction prior to treatment (Lee *et al.* 1988). Therefore, true comparisons must be based on the correlation of the clinical picture with all available measures such as excretory urograms, renal scans and Whitaker tests. Nevertheless, excretory urography proved most reliable in preoperative diagnosis and postoperative follow-up in patients with UPJ obstruction. A satisfactory excretory urogram at 3-6 months is a good predictor of long term success.

The duration of stenting following the procedure has generally been 3 to 6 weeks. Although this period has never been scientifically tested, our reasoning for stenting for 6 weeks was based on research work in animals (Ansong *et al.* 1985; Oppenheimer and Hinman 1955). The original intubated ureterotomy required 6 weeks stenting time (Davis 1943). The complications that occurred with universal stents included hematuria, irritable bladder symptoms, proximal migration and ureteral stricture. These problems led to the present endopyelotomy stent, which is made of polyurethane.

Endopyelotomy has several distinct advantages over open surgery, including the decreased morbidity, shorter hospital stay and convalescent time, and a small scar. Because endopyelotomy does not disturb periureteral fat and preserves the blood supply to the ureter, less scar tissue forms and consequently there is less likelihood of postoperative restenosis. If the procedure does fail, open surgery is no more difficult than in a kidney that has not been surgically treated.

On the other hand, the disadvantages are few. Endopyelotomy does not permit remodeling of a large redundant pelvis. If a large amount of extravasation occurs, subsequent surgical correction may be difficult. Also, because the surgical field is small, experience and manipulative skills are required.

Radiology plays an important role in patient selection, pre and post-operative patient evaluation, nephrostomy related procedure and management of complications. A coordinated effort between the urologist and radiologist is essential for this delicate procedure.

SUMMARY

Endopyelotomy is a safe endourologic procedure that produces long term results similar to that of open surgery for UPJ obstruction. Careful selection of patients (excluding those with very redundant renal pelvis and long stricture) may further improve success rates.

Endopyelotomy has less morbidity than open pyeloplasty, shorter operating time, and also decreases hospitalization, engenders less postoperative pain, and permits a faster return to work. It requires a good percutaneous access to the kidney, adequate incision of the UPJ, and proper stenting.

COMPLEX STONE EXTRACTION

Although extracorporeal shock wave lithotripsy (ESWL) has found world-wide clinical acceptance for the treatment of many renal and upper ureteral calculi, it has not replaced percutaneous nephrolithotomy (PCNL) and ureteroscopy. ESWL serves as effective monotherapy for approximately 75% of patients with such calculi (Leroy *et al.* 1987). Percutaneous techniques for stone extraction or disintegration are still needed, both as primary therapy for patients with complex stones and as secondary therapy when ESWL or ureteroscopy are ineffective. Obviously, patients who require percutaneous nephrolithotomy are more technically difficult than the percutaneous stone population before ESWL (Douenias *et al.* 1989).

Patient Selection

Because we were intimately involved in the development of percutaneous urinary stone extraction, few patients were deemed unsuitable for this procedure. Indications for percutaneous stone extraction are the same as those for surgery. Since April 1982, open surgery was reserved for patients with a staghorn calculus involving the upper portion of a high-lying duplex kidney, or staghorn calculi in which there was extension into compound calyceal projections, with the stone larger than the infundibulum. Although our initial experience with complex staghorn calculi was limited to high-risk patients, all subsequent patients presenting with staghorn calculi at our institution underwent this procedure regardless of operative risk (Lee *et al.* 1985; Lee *et al.* 1987).

One contraindication would have been a significant uncorrectable bleeding diathesis but, in our series of more than 1,200 patients, we encountered no patient with this problem. Patients with acute renal failure due to obstruction were treated initially with decompression via the percutaneous nephrostomy. Once their condition stabilized and their bleeding tendency resolved, tract dilatation and stone extraction were performed.

Preoperative Evaluation

Usual preoperative evaluation included complete

blood count with platelets, bleeding studies, blood chemistry profile, urinalysis, and urine culture. Chest radiograph and EKG are obtained.

The configuration and location of the calculi, as well as the collecting system anatomy were evaluated from a recent intravenous urogram. Careful planning of the placement of the percutaneous nephrostomy tract(s) is then begun on the basis of excretory urography and plain abdominal radiograph obtained prior to the creation of the percutaneous nephrostomy tract(s).

Technique of Percutaneous Ultrasonic Lithotripsy

Our methods of visualization of the collecting system, techniques of percutaneous nephrostomy access, tract dilatation, and stone removal, have all been described previously (Lee and Smith 1987; Lee 1989; Lee *et al.* 1987; Lee *et al.* 1986; Lee 1988). Briefly, for those patients having nephrostomy tracts established in the operating room with the portable C-arm fluoroscopy, a retrograde pyelogram is performed to visualize the renal collecting system and to select

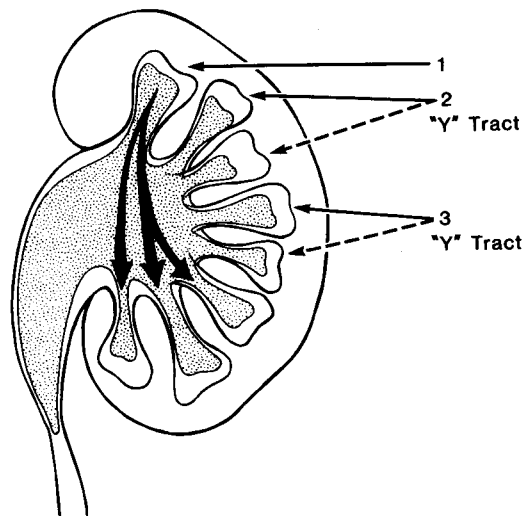


Fig. 7. Access to an inaccessible staghorn calculus.

Upper-pole calyceal, pelvic and lower calyceal stones can be approached by upper calyceal route 1 (possible "Y" tract). To provide access to an adjacent inaccessible calyceal stone, a Y tract nephrostomies are created (2,3 "Y" tract). This is achieved by separate branching tract off the original tract, forming a Y-shaped tract.

nephrostomy tract sites. Successful stone extraction is dependent upon an optimally placed nephrostomy tract through which calculi can be manipulated under direct vision, fluoroscopy, or a combination of both.

For large staghorn calculi branching into upper and lower pole calices, initial puncture into the lower pole calyx may provide adequate exposure to the entire stone. Occasionally, access to an upper caliceal stone can be obtained only by direct supracostal puncture (Fig. 7). If the stone extends into the middle and lower pole calices, two nephrostomy tracts will often be needed into each system. In the case of a bulky staghorn calculus that fills the entire collecting system, percutaneous puncture is done directly on the stone situated in the lower pole calyx, and the ultrasonic lithotrite burrows a path through the stone to allow the guidewire to pass into the collecting system.

In the case of ectopic pelvic kidneys, special techniques must be utilized to aid in the establishment of the nephrostomy tract (Eshghi *et al.* 1985). It is relatively easy to obtain access in horseshoe kidneys and transplanted kidneys.

The nephrostomy tract is dilated with the Amplatz renal dilator system available from Cook, Inc. The tract is dilated routinely to 34 Fr, the 34 Fr Amplatz working sheath is left in place, and all procedures are performed through it. During the dilatation procedure, a "safety" guidewire is inserted. The "working" guidewire is usually left within the 34 Fr sheath, alongside the nephroscope. The Amplatz sheath is used to prevent a build-up of intrarenal pressure during nephroscopy or lithotripsy. Normal saline irrigant is our fluid of choice because of the physiologic compatibility.

The nephroscope is initially inserted via the sheath and, with the aid of the C-arm fluoroscopy, the relationship between the stone and the nephroscope is ascertained. Invariably, there is some blood clot in the renal pelvis, and this is either washed away or, more often, extracted using a grasping forceps or suction probe. Once the stone is clearly visible, it is ultrasonically disintegrated until fragments can be extracted with grasping forceps. Smaller stone fragments can best be dealt with by suction aspiration using the ultrasound probe connected directly to suction. Struvite stones are usually soft and can be readily fragmented and extracted with ultrasound lithotripter suction. Some cystine stones, uric acid stones and occasional calcium phosphate stones are so hard that they may take a long time to fragment. It may take two or three sessions to remove all stone fragments completely. Between the procedures, chemolysis can

be performed if the stone is chemically suitable. Hemiacidrin (Renacidin) is used for the chemolysis of struvite stones, sodium bicarbonate for uric acid stones, and a combination of 5 percent acetylcysteine and tromethamine or tromelhomine-E for cystine stones (Sheldon 1982). Two nephrostomy tubes are employed if chemolysis is used, each passing through a separate site; one tube for delivering the chemolytic solution and another for draining the system (Smith and Lee 1983). The "safety" guidewire protects the access to the kidney for the insertion of an appropriate nephrostomy drainage.

Follow-up studies

Postoperative studies include nephrostogram within 48 hours after nephrolithotomy. If there is no extravasation and contrast medium passes easily down the ureter, the catheter is clamped. The catheter may be removed the following morning provided there is no significant leakage of urine. Significant leakage indicates edema of the ureteropelvic junction, wherein, the nephrostomy tube is usually left attached to a urinary drainage bag for a few additional days. The patient is discharged from hospital with the tube in place. Plain nephrotomography to look for residual stones is a routine part of the nephrostogram. An excretory urogram is obtained 3-6 months later.

Results and Complications

The results of 154 kidneys afflicted with staghorn calculi in 150 patients are as follows; Use of two or more access routes was necessary in 110 patients (71%). Thirty seven patients (24%) required multistaged nephrolithotripsy for complete stone removal (Table 3). A total of 110 kidneys (71%) were rendered stone free after one operative procedure (Lee 1989). At the time of discharge, 132 of 154 kidneys (86%) were completely stone free (Fig. 8). The procedure was considered successful only if the kidney was stone free at discharge.

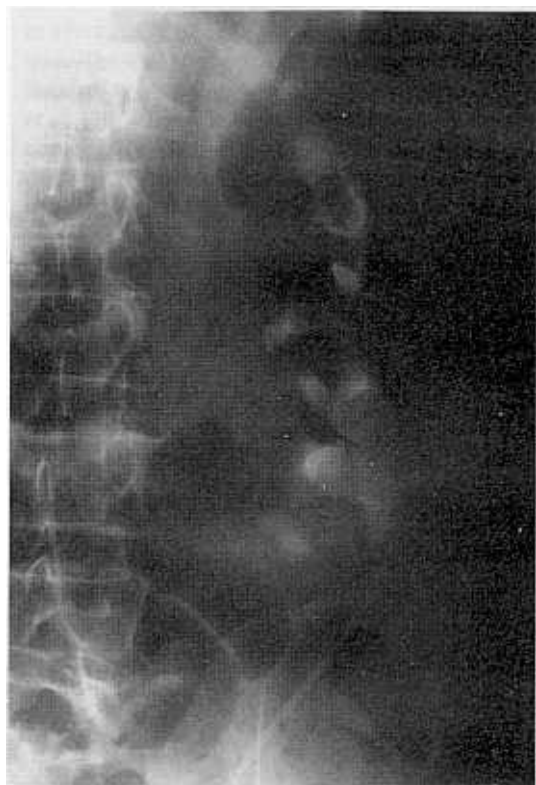Of the 22 patients with procedure failure, residual stones were less than 5mm in diameter at discharge. Twelve patients were stone free within 6 months after spontaneous passage of these fragments. The operative time averaged 160 minutes per patient, and the length of hospitalization averaged 12 days (range 8-32 days). Average post-discharge convalescence was 15.5 days. Results in the first 75 kidneys and the last 79 kidneys were similar because more difficult cases were accepted during the later period.

Major complications occurred in 25 patients (16%).

Table 3. Results of Percutaneous Ultrasonic Lithotripsy of Staghorn Calculi in 154 kidneys

| Number of Nephrostomy Tracts | Number of Kidneys (%) | |
|------------------------------|-----------------------|--------|
| 1 | 44 | (29) |
| 2 | 76 | (49) |
| 3 | 34 | (22) |
| | 154 | (100%) |

| Number of Sessions | Number of kidneys (%) | Stone free (%) at discharge |
|--------------------|-----------------------|-----------------------------|
| 1 | 117 (76) | 110 (71) |
| 2 | 29 (19) | 14 (48) |
| 3 | 8 (5) | 8 (100) |
| | 154 (100) | 132 (86) |

**Fig. 8A.** Percutaneous Ultrasonic Lithotripsy for full staghorn calculus.

Plain abdominal radiograph shows a staghorn calculus occupying the entire collecting system in malrotated kidney. Retrograde ureteral catheter has been placed.

The most common complications—bleeding necessitating transfusion (hematocrit of less than 30%)—occurred in 86 patients, but only two patients required selective embolization of a pseudoaneurysm. The occurrence of infection in approximately 25% of patients, despite prophylactic administration of antibiotics, probably reflects release of organism from the stone. Other major complications included pneumothorax/hydrothorax (7%), renal pelvic laceration (3%), sepsis (3%), and UPJ stricture (1%). Our aggressive approach to rid all stone fragments was responsible for a higher rate of complications. A review of pneumothorax cases indicates the nephrostomy tract above the 11th rib. Therefore, we do not hesitate to puncture the kidney above the 12th rib.

The single death occurred in a 67 year old obese woman with hypertension and diabetes mellitus who suffered myocardial infarction in the postanesthesia recovery room after successful nephrolithotomy.

DISCUSSION

Although ESWL has become the treatment of choice for most symptomatic renal calculi, in 10-20% of patients it is ineffective or insufficient (Chaussy *et al.* 1984). A variety of methods of stone removal have been advocated. Baskets and grasping forceps are suitable only for small stones, generally free floating ones. Ultrasonic lithotripsy is effective in large renal stones. Clearly, percutaneous nephrolithotomy has high success rate in rendering patients stone free with minimal complications if the patients are properly chosen (Schiff and Lee. 1986). Calculi associated with significant anatomic anomalies may be subject to

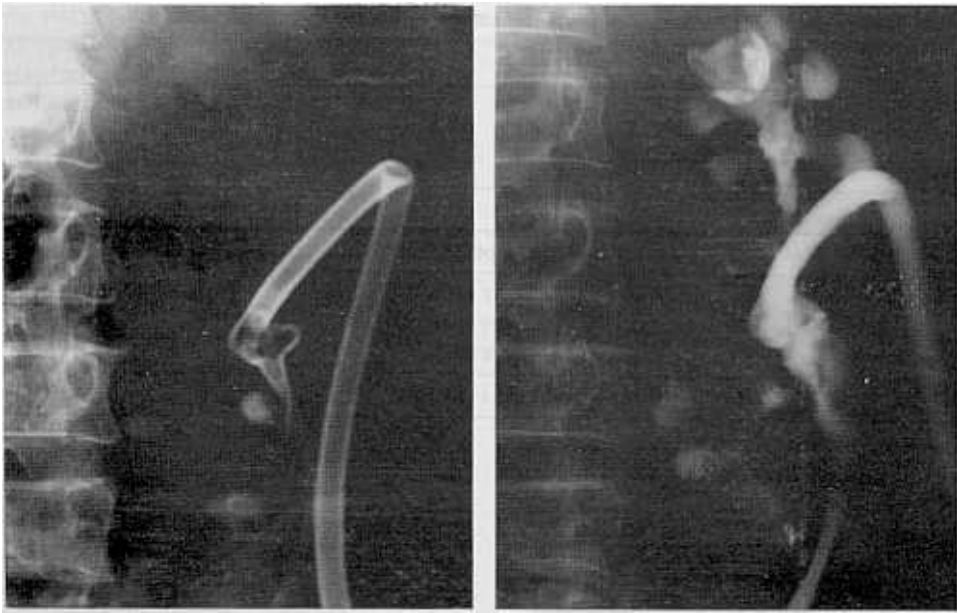


Fig. 8B. Plain abdominal radiograph following first session percutaneous ultrasonic lithotripsy shows three residual fragments. A reentry nephrostomy catheter (24-F shaft) is in place. Nephrostogram shows patency of the renal collecting system. Stone fragments are in the minor calices.

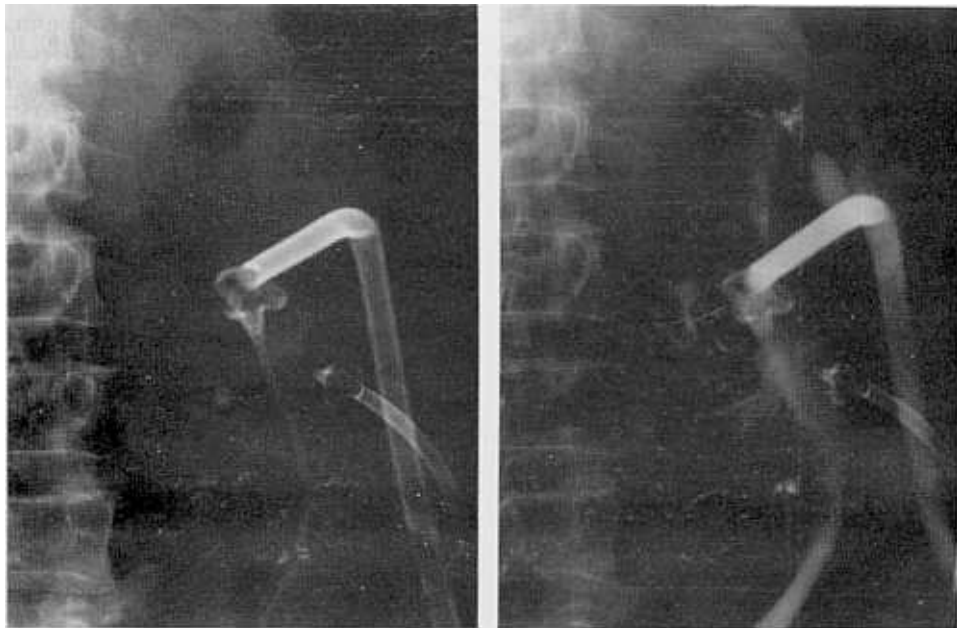


Fig. 8C. Plain abdominal radiograph following second session shows complete removal of the stone fragments. Second nephrostomy access route was created in order to remove residual stones. Note 14F Malecot nephrostomy catheter. Repeat nephrostogram shows collecting system patency. There is no evidence of extravasation, obstruction or clot retention. The nephrostomy catheters were removed 24 hours later.

simultaneous percutaneous nephrolithotomy and endourologic correction of the anomaly (Dounenias *et al.* 1989).

At present, percutaneous ultrasonic lithotripsy appears superior to open nephrolithotomy in nearly all cases of complex stones including staghorn calculi; it is faster and less expensive, has a lower rate of complications, entails a shorter convalescence and leaves a small scar. The role of ESWL in complex stones is limited. Even after the installation of ESWL at our institution, percutaneous nephrolithotomy plays primary role in the management of stone disease.

The complications of percutaneous ultrasonic nephrolithotomy are generally minor and easily managed. The most serious are acute and delayed bleeding and sepsis. If bleeding does not resolve with conservative management, renal angiography (embolization) should be performed (Lee *et al.* 1986). Urinary tract infection may be intrinsic to removal of calculi. Most struvite stones are formed in response to infection, with urea-splitting organisms such as *Proteus*. These stones contain viable bacteria that are liberated when a stone is broken during lithotripsy (Lee *et al.* 1987). There is a possibility that the risk of infection would be higher after ESWL for the same stones because of the inflammation and friability of the urothelium. Although fever is common after staghorn or infected stone removal, gram-negative septicemia is rare.

SUMMARY

Clearly, ours and others experiences substantiate a continued and important need for expertise in percutaneous techniques in the ESWL era. The percutaneous techniques are vital to effective treatment for the spectrum of patients with upper urinary tract stone disease. This technique is a safe and effective means of treating renal stones including complex stones such as staghorn calculi. ESWL appears to be useful as a supplement to Ultrasonic lithotripsy, rather than a substitute for percutaneous techniques, in patients with these complex stones. Successful stone extraction requires a clear understanding of renal anatomic features, properly placed access routes, and close cooperation of radiologist and urologist.

It is important to emphasize that close cooperation between these two specialties will encourage great strides in this rapidly growing new field of Endourology.

REFERENCES

- Ansong K, Khashu B, Lee WJ, Smith AD: Prophylactic use of ureteral stent in iatrogenic injuries to ureter. *Urol* 26:45-49, 1985
- Balll WS Jr, Towbin R, Strife J *et al*: Interventional genitourinary radiology in children: A review of 61 procedures. *AJR* 147:791-794, 1986
- Banner MP, Pollack HM: Dilatation of ureteral stenosis: techniques and experience in 44 patients. *AJR* 143:789-792, 1984
- Barbaric ZL: Percutaneous nephrostomy for urinary tract obstruction. *AJR* 143:803-809, 1986
- Brannen GE, Bush WH, Lewis GP: Endopyelotomy for primary repair of ureteropelvic junction obstruction. *J Urol* 139:29-32, 1988
- Chaussy C, Schmiedt E, Jocham D *et al*: Extracorporeal shock-wave lithotripsy (ESWL) for treatment of urolithiasis. *Urol* 23 (suppl):59-62, 1984.
- Cromie W: Complications of pyeloplasty. *Urol Clin North Am* 10:385-397, 1983
- Davis DM: Intubated ureterotomy: A new operation for ureteral and ureteropelvic stricture. *Surg Gynecol & Obstet.* 76:513-518, 1943
- Dounenias R, Lee WJ, Smith AD: Percutaneous nephrolithotomy in ESWL Era. *Applied Radiol* 18:17-20, 1989
- Eshghi AM, Roth JS, Smith AD: Percutaneous transperitoneal approach to a pelvic kidney for endourological removal of a staghorn calculus. *J Urol* 134:525-527, 1985
- Ford KK, Weinerth JL: *Renal anatomy: Surgical and Radiographic*. In Carson CC, Dunnick NR. (ed.): *Endourology*. New York, Churchill Livingstone 1985, 9-26
- Goodwin WE, Casey WC, Woolf W: Percutaneous trocar (needle) nephrostomy in hydronephrosis. *JAMA* 157:891-894, 1955
- Hendren WH, Radhakrishnan J, Middleton AW Jr: Pediatric pyeloplasty. *J Pediatr Surg* 14:133-136, 1980
- Hogan J, Cubelli V, Lee WJ, Smith AD: Endourologic stenting anastomotic stricture: Cope modification. *J Endourol* 1:275-277, 1988
- Huffman JL, Bagley DH, Lyon ES *et al*: Endoscopic diagnosis and treatment of upper-tract urothelial tumors: A preliminary report. *Cancer* 55:1422-1426, 1985
- Kadir S, White RI, Engel R: Balloon dilatation of a ureteropelvic junction obstruction. *Radiol* 143:263-266, 1982
- Karlin G, Rich M, Lee W, Smith A: Endourologic management of upper-tract fungal infection. *J Endourol* 1:49-54, 1987
- Kaye KW, Reinke DB: Detailed caliceal anatomy for endourology. *J Urol* 132:1085-1089, 1984
- Lang E: Antegrade ureteral stenting for dehiscence, stricture, and fistula. *AJR* 143:795-799, 1984
- Lee WJ, Badlani G, Smith AD: Percutaneous nephrostomy for

- endopyelotomy. *AJR* 148:189-192, 1987
- Lee WJ, Smith AD: Percutaneous removal of urinary calculi: Results and analysis of failures. *Interventional Radiol* 2:19-25, 1987
- Lee WJ, Loh G, Smith AD: Percutaneous extraction of renal stones: experience in 100 patients. *AJR* 144:457-462, 1985
- Lee WJ, Smith AD, Cubelli V, et al: Complications of percutaneous nephrolithotomy. *AJR* 148:177-180, 1987
- Lee WJ, Badlani GH, Karlin GS, Smith AD: Treatment of ureteropelvic strictures with percutaneous pyelotomy: Experience in 62 patients. *AJR* 151:515-518, 1988
- Lee WJ, Rich M: The universal stent introducer: A simplified approach to antegrade ureteral stent insertion. *AJR* 147:830-831, 1986
- Lee WJ, Moskowitz GW, Pochaczewsky: Role of radiology in diagnosis and management of complications of percutaneous endopyelotomy. *Seminars in Interventional Radio* 6:182-187, 1989
- Lee WJ: Percutaneous management of staghorn renal calculi. *J Kor Radiol Soc.* 25:680-688, 1989
- Lee WJ, Snyder JA, Smith AD: Staghorn calculi: Endourologic management in 120 patients. *Radiol* 165:85-88, 1987
- Lee WJ, Smith AD, Cubelli V et al: Percutaneous nephrolithotomy: Analysis of 500 consecutive patients. *Urol Radiol* 8:61-66, 1986
- Lee WJ: *Percutaneous Uroradiologic Techniques*. In Castaneda-Zuniga WR, Tadavarthy SM (eds): *Interventional Radiology*, Baltimore, Williams & Wilkins, 1988, 423-621
- Leroy AJ, Segura JW, Williams JH Jr, Patterson DE: Percutaneous calculus removal in an extracorporeal shock wave lithotripsy practice. *J Urol* 138:703-707, 1987
- Mitty HA, Train JS, Dan SJ: Antegrade ureteral stenting in the management of fistulas, stricture and calculi. *Radiol* 149:433-438, 1982
- Moskowitz G, Ortiz O, Lee WJ et al: Percutaneous access to the upper pole calyx: Renal displacement technique. *Radiol* 173 (P):512, 1989
- Moskowitz G, Lee WJ, Pochaczewsky R: Diagnosis and management of complications of percutaneous nephrolithotomy. *Crit Rev Diag Imag* 29(1):1-12, 1989
- Oppenheimer R, Hinman F, Jr: Ureteral regeneration: Contraction vs. hyperplasia of smooth muscle. *J Urol* 74:476-480, 1955
- Ortiz O, Lee WJ: Percutaneous nephrostomy in the management of renal candidiasis. *Arch Surg* 124:739-740, 1989
- Orihuela E, Smith AD: Percutaneous treatment of transitional cell carcinoma of the upper urinary tract. *Urol Clin North Am* 15:425-431, 1988
- Rich M, Lee WJ, Smith AD: Application of the peel-away introducer sheath. *J Urol* 137:452-454, 1987
- Schiff R, Lee WJ: Morphological and functional changes of the kidney following percutaneous stone extraction. *AJR* 147:283-286, 1986
- Sheldon CA, Smith AD: Chemolysis of calculi. *Urol Clin North Am* 9:121-125, 1982
- Smith AD, Lee WJ: Percutaneous stone removal procedures including irrigation. *Urol Clin North Am* 10:719-727, 1983
- Smith AD, Lee WJ: Characteristics and uses of universal (Smith) ureteric stent. *Br J Urol* 55 (Suppl):79-81, 1983
- Smith AD, Lee WJ: *Complex percutaneous manipulation*. In Carson CC, Dunnick NR (eds): *Endourology*, New York, Churchill Livingstone, 1985, 159-180
- Smith AD, Lee WJ: Percutaneous stone extraction. *Br J Urol* 55 (Suppl):82-85, 1983
- Smith AD, Lee WJ: Techniques and complications of nephrostomy tract dilatation and tube insertion. *Br J Urol* 55 (suppl):86-88, 1983
- Smith AD, Lee WJ: Introduction to endourology: Percutaneous nephrostomy and ureteral stents. *Am Urological Assoc. Update Series* 3:1-8, 1984
- Smith AD, Lee WJ, Benderev T: Percutaneous management of urinary Calculi: Clinical status of a new approach. *Internal Med* 4:146-154, 1983
- Stable DP: Percutaneous nephrostomy: Technique, indications and results. *Urol Clin North Am* 9:15-29, 1982