

A Case of Urethral Replacement with Polytetrafluoro-Ethylene Graft for Multiple Anterior Urethral Strictures

Hyung Ki Choi and Soo Kee Chang

Recently, the authors had an opportunity to treat a 73-year-old male patient who was transferred to our institution with problematic multiple strictures of the anterior urethra subsequent to a suprapubic cystostomy. A proximal urethra was reconstructed with scrotal skin, but due to the shortage of distal skin, as a last resort we reconstructed a distal urethra using a polytetrafluoroethylene graft in place of 10cm long urethral strictures. About 5 months after surgery, we had to reexplore the polytetrafluoroethylene graft area because of pain and found, much to our surprise, that the urethra had been completely regenerated around the length of polytetrafluoroethylene graft which now remained freely detached in the urethral canal. Following removal of the polytetrafluoroethylene graft, the patient could urinate normally and was subsequently discharged without further problems. We concluded that this case was incidentally successful with good regeneration of urethral mucosa of the anterior urethra by grafting a polytetrafluoroethylene tube.

Key Words: Polytetrafluoroethylene graft, multiple urethral strictures.

CASE REPORT

A 73-year-old male presented with the chief complaint of the inability to void spontaneously.

Ten months prior to admission to our institution with a suprapubic cystostomy, the patient sustained urinary bladder perforation and fracture of the right ischium in an automobile accident. He was admitted to another hospital following the accident where he received appropriate treatment including an indwelling urethral catheter for about 3 months. The patient then developed difficulty in urination which eventually led to a suprapubic cystostomy.

On physical examination, he had a suprapubic cystostomy, otherwise he was in good general health without costovertebral angle tenderness on either side. Laboratory findings revealed many WBC's per HPF on urinalysis. Urine culture showed gram-negative

bacilli of more than 100,000 per milliliter. Hematology and chemistry profiles were all within normal limits. An excretory urogram revealed no abnormalities in the upper urinary tract, whereas a retrograde urethrogram clearly demonstrated multiple strictures involving the proximal and distal urethra (Fig. 1).

When such operative methods as urethral dilation and endoscopic urethrotomies proved to be of no avail, we first identified and exposed the penile urethra by Johanson's procedure and performed an artificial perineal urethrotomy. Three months later, the proximal portion of the anterior urethra was reconstructed using a scrotal skin graft, but for the distal portion, usual reconstruction of the urethra was not feasible due to lack of skin availability. Having exhausted all therapeutic means available to us, it was decided to replace the 10cm long urethral stricture with a polytetrafluoroethylene graft of 6mm diameter (Fig. 2).

Two weeks after operation, he could void well, so we removed the suprapubic cystostomy tube. In a follow-up examination 5 months after operation, the patient complained of pain in the grafted area which led us to reexploration with surprising results. On reexploration, we observed that urethral formation was complete around and outside the polytetrafluoroethylene graft (Fig. 3), while the graft itself remained inside the newly formed urethra in a freely detached

Received February 20, 1989

Accepted May 2, 1989

Department of Urology, Yong Dong Severance Hospital, Yonsei University College of Medicine, Seoul, Korea

Address reprint requests to Dr. H K Choi, Department of Urology, Yong Dong Severance Hospital, Yonsei University College of Medicine, Seoul, Korea, 137-270

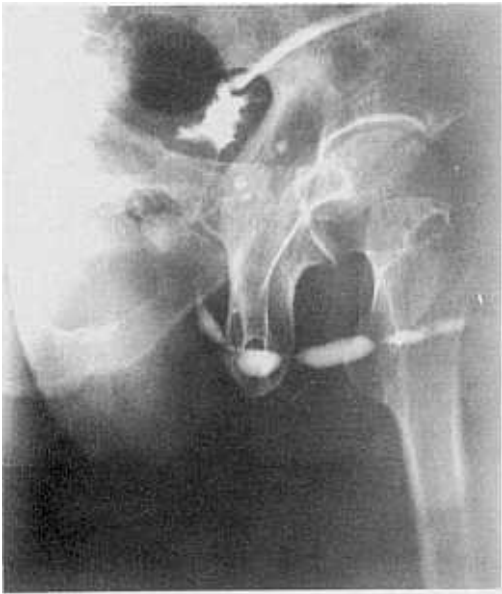

Fig. 1. Retrograde urethrogram shows multiple strictures on the entire urethra.

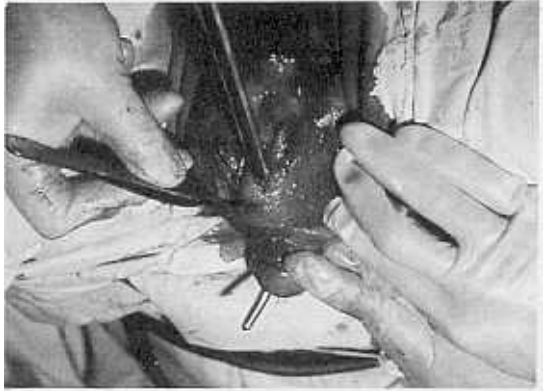


Fig. 3. Regeneration of urethra was complete around the Gore-Tex graft. The detached Gore-Tex graft has been removed.

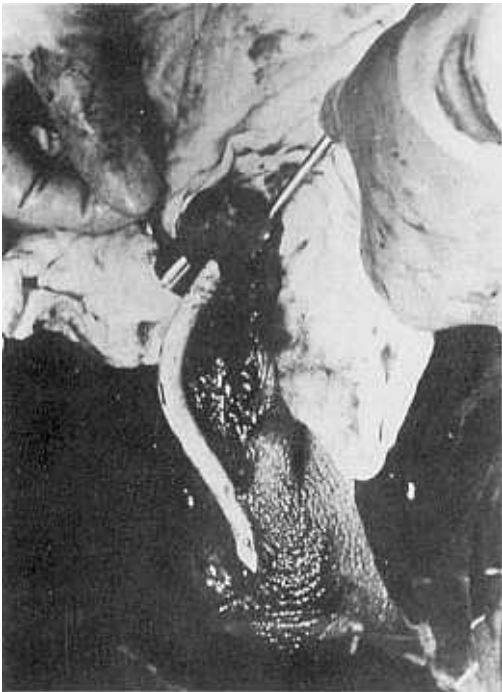


Fig. 2. Urethral replacement with Gore-Tex (Polytetrafluoroethylene).

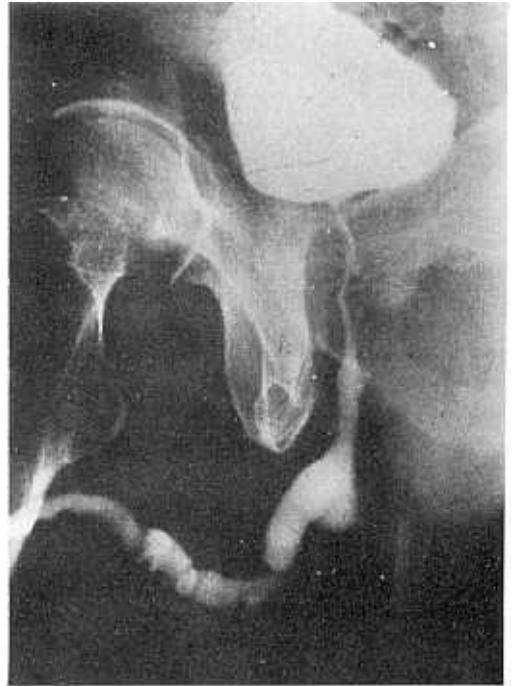


Fig. 4. Retrograde urethrogram after removal of Gore-Tex graft.

state. Following removal of this graft and operative wound repair, the patient could urinate normally without further difficulties, and also the retrograde urethrogram showed satisfactory findings (Fig. 4). This fortuitous result from a urethral replacement graft using polytetrafluoroethylene was unexpected.

DISCUSSION

It is known to be difficult to treat, by means of urethral dilatation or endoscopic urethrotomies, those multiple urethral strictures manifesting themselves as complications of urethritis or long-term indwelling catheterizations, which as a rule show inflammatory reactions involving entire layers of the urethra. The locations as well as the severity of the urethral strictures and general condition of the patients must be taken into consideration in treating patients.

In this particular case, long-term indwelling urethral catheterization led to multiple strictures of the proximal and distal urethra. Urethral dilatation or internal urethrotomies were not feasible in this case and the patient developed fibrosis in all layers of the urethra and periurethral tissues as well, following Johanson's urethral reconstruction procedure.

Experimental urethral replacements for areas of strictures have been reported with no satisfactory results, in which researchers performed tissue grafts using venous patches, tunica vaginalis, siliconized rubber patches, or synthetic materials such as siliconized dacron, etc. (Anwar *et al.* 1984). However, there are no actual clinical case reports that we are aware of. Polytetrafluoroethylene has recently been developed for the purpose of vascular grafts and it has been in wide use in experimental and clinical microvascular grafts (Campbell *et al.* 1976; Choi *et al.* 1984).

Mah *et al.* (1984) reported the possibility of clinical use of the polytetrafluoroethylene graft as a temporary measure to expand the capacity of a contracted bladder, if one could solve the problems of stone formation in the bladder. After observing complete regeneration of the mucosal, muscular, and serosal layers of the defective area of the bladder where an experimental polytetrafluoroethylene replacement was made for the bladder defect, the polytetrafluoroethylene graft became completely detached from the bladder wall instead of becoming part of the tissues as in vascular graft cases, thereby freely remaining in the bladder cavity forming stones.

In our patient, who had a satisfactory clinical course from the stand-point of urination, we found the completely detached polytetrafluoroethylene graft in the urethral canal, while the urethra had successfully

regenerated around the polytetrafluoroethylene graft with good epithelialization at the time of reexploration of the operative area because of complaints of pain 5 months after the graft procedure.

These findings were similar to those of Mah's bladder reconstruction experiment, in that the polytetrafluoroethylene detachment was inside the urethra in our case of urethral reconstruction.

Therefore, we believe one could consider treating patients with hard-to-treat, multiple urethral strictures, on whom conservative measures have failed, with polytetrafluoroethylene graft reconstructive surgery as an initial step, then after completion of urethral epithelialization around the graft, the graft would be removed through an incision or by endoscopic measures.

CONCLUSION

In a 73-year-old male patient with multiple urethral strictures, we performed a urethral replacement with a polytetrafluoroethylene graft about 10cm long.

On follow-up 5 months later, the operative field was reexplored due to pain. We found complete urethral regeneration around the polytetrafluoroethylene graft while the graft itself remained inside the urethral lumen in a freely detached state. After removal of the polytetrafluoroethylene graft, the patient could void in a normal fashion quite satisfactorily.

We think that urethral replacement with polytetrafluoroethylene could be a last resort procedure for patients who have hard-to-treat, problematic urethral strictures.

REFERENCES

- Anwar H, Davé B, Seebode JJ: Replacement of a partially resected canine urethra by polytetrafluoroethylene. *Urology* 24:583, 1984
- Campbell CD, Brooks DH, Webster MW, Bahinson HT: The use of expanded microporous polytetrafluoroethylene for limb salvage: A preliminary report. *Surg* 79:485, 1976
- Choi HK, Yang SC, Lee JM: Microvascular polytetrafluoroethylene graft in the rat. *Yonsei Med* 25(1): 1, 1984
- Mah SY, Park YY, Choi HK, Lee JM: An experimental study on bladder regeneration using polytetrafluoroethylene. *Yonsei J of Med Science* 17:68, 1984