

Diagnosis of Cervical Tuberculous Lymphadenitis with Fine Needle Aspiration Biopsy and Cytologic Examination under Ultrasonographic Guides

Kwang Wook Suh¹, Cheong Soo Park², Jong Tae Lee³ and Kwang Gil Lee⁴

The efficacy of the fine needle aspiration biopsy and cytological examination (FNABC) under ultrasonographic (US) guides for the diagnosis of cervical tuberculous lymphadenitis was assessed. In one hundred and one patients with a neck mass or masses, tuberculous lymphadenitis has been proved by FNABC. US disclosed the physical characteristics of the masses: All the cases that involved two or more lymph nodes were multiple lesions. Eighty lesions (79.1%) were multiregional, and in 19 cases (18.8%), bilateral neck was involved. The posterior triangle of the neck was the most prevalent site (N=69, 68.3%). Ninety two cases (90.9%) were hypoechoic lesions and 9 (9.1%) showed mixed echo patterns. There was no hyperechoic lesion ($p<0.001$). The sensitivity of FNABC was 77.2% and the specificity was 99.0%. The diagnostic accuracy was 85.0%. There was no complication during the procedure. FNABC for the diagnosis of cervical tuberculous lymphadenitis is a safe, convenient procedure and has a relatively high specificity. The limitation of FNABC, the low sensitivity, seemed to be compensated by US examinations.

Key Words: Fine needle aspiration biopsy and cytology, ultrasound, tuberculous lymphadenitis

The fine needle aspiration biopsy and cytologic examination (FNABC) has proved its usefulness in the diagnosis of variable benign and malignant neoplasms. Merits of FNABC include technical convenience, noninvasiveness and high specificity. But diagnostic limitations also have been reported and especially in diagnosing tuberculous lymphadenitis, FNABC proved to have the lowest sensitivity. (Lau *et al.* 1991). The aim of this study is to evaluate the diagnostic efficacy of FNABC and to elucidate whether ultrasonography(US) compensates the diagnostic limi-

tation of FNABC in cervical tuberculous lymphadenitis.

PATIENTS AND METHODS

One hundred and one patients whose neck masses had been confirmed as cervical tuberculous lymphadenitis were reviewed retrospectively. They underwent FNABC after routine physical examinations, checking the complete blood count and coagulation profiles (PT, PTT).

TECHNIQUES OF FNABC: The patient is placed in the supine position with the neck slightly extended. After preparation of the skin overlying the mass with povidine iodine, sterile drapes are made over the area. First the physical characteristics and locations of the masses are identified with the ultrasonography (Toshiba SAL-30A, 3.5 MHz Real

Received August 25, 1992

Department of Surgery¹, Ajou University College of Medicine, Suwon, Korea

Department of Surgery², Diagnostic Radiology³, Pathology⁴, Yonsei University College of Medicine, Seoul, Korea

Address reprints to Dr. K W Suh, Department of Surgery, Ajou University College of Medicine, Paldal Koo Woncheon Dong San-5, Suwon, Korea

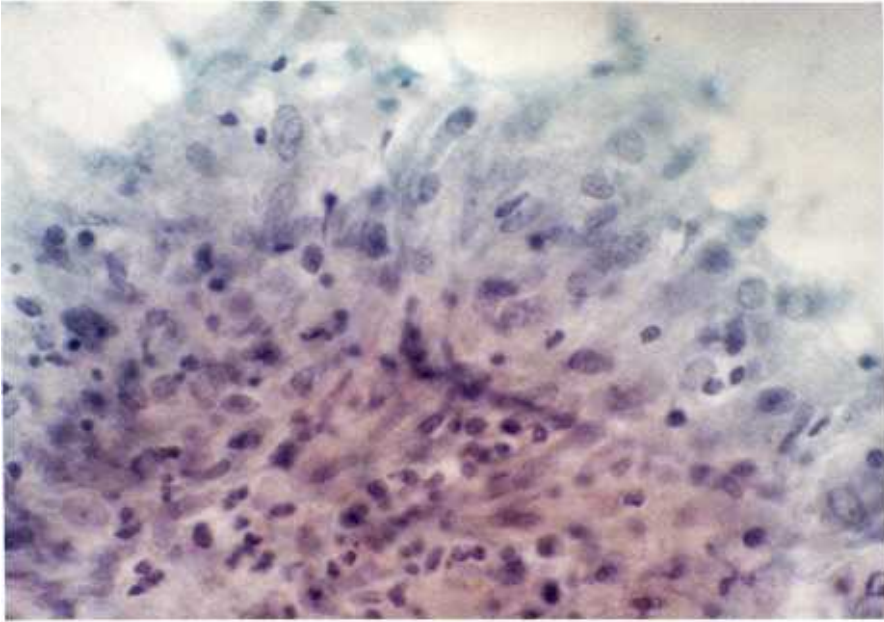


Fig. 1. Cytologic finding of aggregation of epithelioid cells (Papanicolaou stain, $\times 400$).

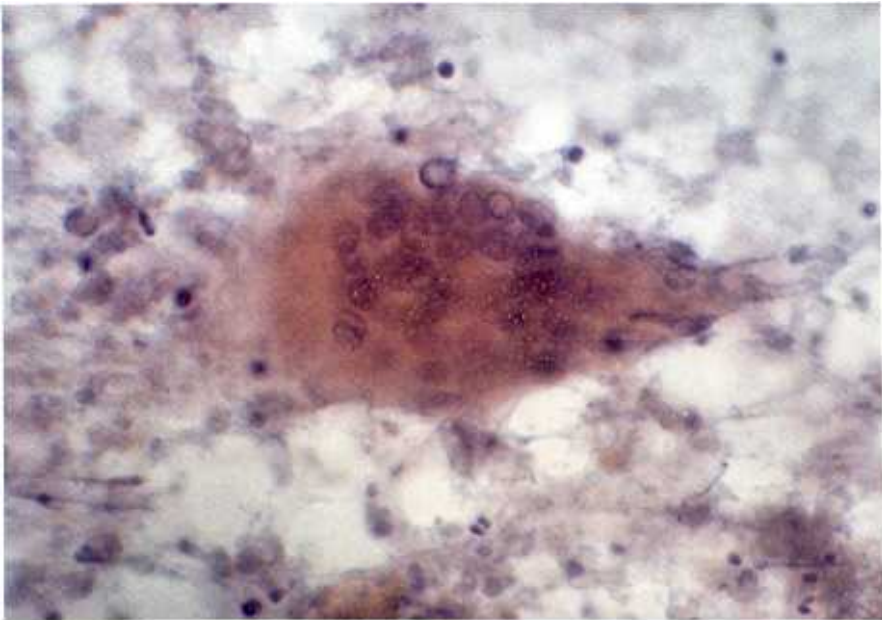

Fig. 2 Cytologic finding of the Langhan's giant cell (Papanicolaou stain, $\times 400$).

Time Linear Transducer). Then a Chiba needle (22 or 23 Gauge) is introduced through the hole in the transducer and inserted into

the center of the mass. A 20-ml-syringe is connected to the needle and the contents of the mass are aspirated. Aspirations are per-

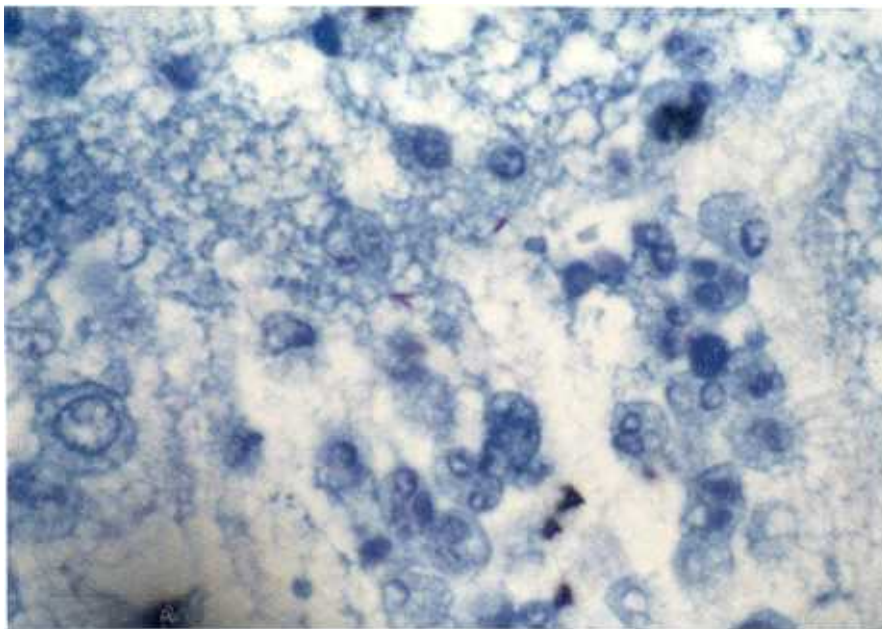


Fig. 3. Cytologic finding of the necrotic materials with AFB bacilli (Ziehl-Neelsen stain, $\times 400$).

formed not only from the main mass but from clinically uncheckable, satellite masses. The aspirates are smeared over the glasses immediately after aspiration and are dried. Then Diff-Quick (Giemsa), Papanicolaou and Ziehl-Neelsen stains are made. A pathologist examines the slides at the bedside, and if the submitted specimens are insufficient, aspirations are repeated until satisfactory. If the masses were suspected as abscesses, Gram's stain and cultures for bacteria, including acid-fast bacilli, were performed. Paraffin blocks were also prepared with the remaining materials in all cases for the permanent tissue diagnosis.

Diagnostic criteria for the tuberculous lesion:

Components of a typical granulomatous reaction, such as epithelioid cells (Fig. 1), Langhan's giant cells (Fig. 2), and necrotic materials (Fig. 3) were regarded as pathognomonic findings of the tuberculous lesion. When the acid-fast bacilli were found on a Ziel-Neelsen stain (Fig. 3) or in cultures, the diagnosis was confirmed. If there was otherwise a nonspecific cytological finding, remaining tissue

fractions were fixed with formalin and Paraffin blocks were made. After the routine Hematoxylin-Eosin stain, the histologic examination was performed.

Statistical significance of the difference between variables were analysed with the chi-square test and when the P value was less than 0.05, the difference was regarded as significant.

RESULTS

Ultrasonographic Characteristics of Tuberculous Lymphadenitis

US afforded detailed information about the physical characteristics of the mass which couldn't be checked by physical examination alone: Precise numbers, location, presence of satellite nodules, and the shape of the inner aspect of the mass could be indentified with US. All the lesions proved to be multiple lesions. Their locations could be classified according to Suen's neck compartmentalization (Suen *et al.* 1987) and the Level V, IVb and

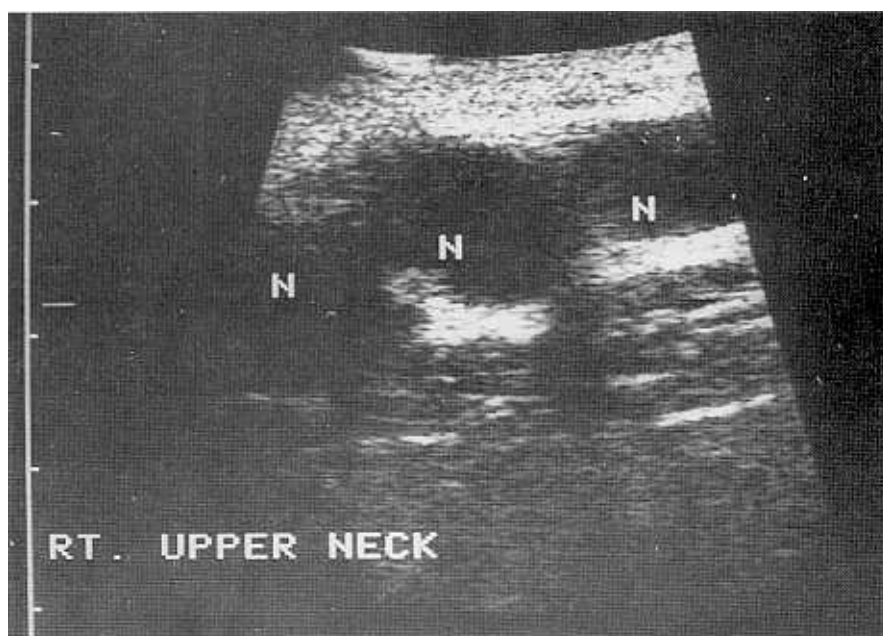


Fig. 4. Ultrasonographic finding of conglomerated hypoechoic lymph nodes. Posterior enhancements are seen.

Table 1. Ultrasonographic findings of cervical tuberculous lymphadenitis

Finding	Number of patient(%)	P value
Hypoechoic	92(90.9)	
with posterior enhancement	58	
with posterior enhancement	34	<0.001
Hyperchoic	0	
Mixed echo pattern	9(9.1)	

IVa were the predilection sites (69, 48, 23 cases respectively). Twenty one patients had single compartmental lesions and 80 had multicompartmental lesions. Ninety two cases (90.9%) showed hypoechoic lesions (Fig. 4). Among them 58 cases accompanied the posterior enhancements. Nine cases showed mixed echo patterns. There was no hyperchoic lesion. The difference between US findings reached statistical significances ($p < 0.001$) (Table 1).

Table 2. Comparison between FNABC diagnosis and final diagnosis

Final diagnosis	Tuberculosis	Malignant Lymphoma
FNABC diagnosis		
Tuberculosis	78 ¹	1 ³
Abscess	7 ³	
Reactive	1 ³	
Hyperplasia		
Malignant	1 ³	
Lymphoma		
Malignant cells are not seen	14 ³	

1, Accurately diagnosed cases

2, False positive case

3, false negative cases

Diagnostic Efficacy of FNABC

There were 23 false negative cases and one

false positive case. The sensitivity of FNABC was 77.2% and specificity was 99.0%. Diagnostic accuracy was 85.0% (Table 2). No complication was observed during the procedures.

DISCUSSION

For the tissue diagnosis of an enlarged lymph node, especially the cervical lymphadenitis, the fine needle aspiration biopsy with cytological examination (FNABC) has been substituted for the surgical biopsy procedures. This transition is based upon several clinical observations: FNABC has proven to be an easy, quick, reliable, and cost-effective diagnostic tool for lymphadenopathies [Guthrie, 1921]. FNABC also avoids the physical and psychological trauma occasionally encountered after open surgical biopsy [Gupta *et al.* 1991].

The use of FNABC has been extended to the diagnosis of tuberculous lymphadenopathies (Baily *et al.* 1985; Rajwanishi *et al.* 1987; Randhika *et al.* 1989). But complications following excisional biopsy of tuberculous lymphadenitis, such as wound infection, delayed healing, or fistula formation (Campbell *et al.* 1977), distressed clinicians into applying FNABC to the diagnosis of tuberculous lymphadenitis. The reliability of FNABC in the diagnosis of tuberculous lymphadenitis is still unsatisfactory because of its low sensitivity (Lau *et al.* 1991). The reported sensitivity ranged from 71% (Lau *et al.* 1988) to 90% (Patra *et al.* 1983). This range is not acceptable because FNABC has a sensitivity of almost 100 % for other diseases.

In our series, we tried to raise the sensitivity as follows: First, the cytologist examined the slides at the bedside of the patient as soon as possible. Second, aspirations were repeated until the submitted materials were sufficient for cytologic diagnosis. Third, in cases of multiple lesions, aspirations were carried out not only from the main lesion but from satellite lymph nodes. The satellite or hidden lesions could be disclosed by the ultrasonography (US). Finally, US facilitated the localization of the needle tip into the core of the affected lymph node without injuring vascular or neuronal structures.

In spite of aforementioned efforts, we failed to increase the sensitivity. The sensitivity of 77.2% in our series is comparable to other reports (Baily *et al.* 1985; Lau *et al.* 1988; McLeen *et al.* 1989). The low sensitivity of FNABC for the tuberculous lesion is thought to be an unavoidable diagnostic limitation.

Tuberculous lymphadenitis has unique pathologic stages [Jones *et al.* 1962]. Characteristically, more than one lymph node is involved in this disease. So, variable numbers of lymph nodes with variable stages are also a characteristic finding. These pathologic characteristics may be closely related to the outcome of FNABC. Aspirates from stage one or two tuberculous lymphadenitis usually provides inflammatory cells as seen by an ordinary lymphadenitis. Thus, FNABC of these stages can only be a nonspecific inflammation. Typical necrotic materials, or tubercle bacilli can be seen in the advanced stages in which an abscess is readily formed in the core of the lymph node. So aspirates from an early stage lymph node were the main cause of low sensitivity. It is necessary to follow the patients whose clinical findings are compatible with tuberculous lesions.

Acid-fast bacilli can be disclosed by direct smear or culture when the aspirates are obtained from a central abscess. As mentioned earlier, if abscess formation does not occur until stage three, repetition of FNABC is necessary.

Additional diagnostic procedures accompanying the FNABC have been reported for increasing the sensitivity in diagnosing cervical tuberculous lymphadenitis. A sensitivity of 90 % has been reported when FNABC was interpreted in conjunction with the Matoux test [Lau *et al.* 1991]. Routine AFB cultures also raise the efficacy [Radhika *et al.* 1989]. Theoretically cervical tuberculous lymphadenitis can provide a positive Mantoux test and the possibility of the cervical tuberculous lymphadenitis would be excluded in negative Mantoux test with negative FNABC findings. But in an endemic area of pulmonary tuberculosis, such as in Korea where most of the population had experienced primary pulmonary tuberculosis during childhood and were immunized with BCG, the positive Mantoux test is unreliable.

Routine performance of AFB culture elicits the identification of bacilli more frequently but more than four weeks are required for completion of the study. In our experience, US could aid the differentiation of a tuberculous lesion. It can find clinically undetectable satellite nodes and proves to be a safer and more accurate way for needle puncture and moreover, it afforded detailed informations about the physical characteristics. Exclusively, there was no hyperechoic lesion ($p < 0.001$).

FNABC is the method of first choice for the differentiation of any cervical lymphadenopathy because of its high specificity. If any typical finding of tuberculosis is disclosed, antituberculous medications should be started. If the tuberculous lymphadenitis is suspected in the cervical region clinically but the FNABC reveals no typical finding, further diagnostic plans can be made by ultrasonographic findings: If a hyperechoic lesion is found ultrasonographically, the possibility of tuberculosis is negligible so further surgical procedures for confirmative tissue diagnosis will be required. If hypoechoic or mixed echo patterns are found, antituberculous chemotherapy should be considered and periodic retrials of FNABC is recommended. In any case, a premature decision of surgical intervention must be avoided.

REFERENCES

- Baily TM, Akhtar M, Ali MA: Fine needle aspiration biopsy in the diagnosis of tuberculosis. *Acta Cytol* 29: 732-736, 1985
- Campbell IA, Dyson AJ: Lymph node tuberculosis: A comparison of various methods of treatment. *Tubercle* 58: 171-179, 1977
- Gupta AK, Nayar M, Chandra M: Reliability and limitations of fine needle aspiration cytology of lymphadenopathies, An analysis of 1261 cases. *Acta Cytol* 35: 777-783, 1991
- Gupta AK, Nayar M, Chandra M: Critical appraisal of fine needle aspiration cytology in tuberculous lymphadenitis. *Acta Cytol* 36: 391-394, 1992
- Guthrie CG: Gland puncture as a diagnostic measure. *Johns Hopkins Med J* 32: 266-269, 1921
- Jones PG, Campbell PE: Tuberculous lymphadenitis in childhood: The significance of anonymous mycobacteria. *Br J Surg* 50: 302-314, 1962
- Lau SK, Wei WE, Hsu C, Engzell UC: Fine needle aspiration biopsy of tuberculous lymphadenopathy. *Aust N Z J Surg* 57: 947-950, 1988
- Lau SK, Wei WE, Kwan S, Yew WW: Combined use of fine-needle aspiration cytologic examination and tuberculin skin test in the diagnosis of cervical tuberculous lymphadenitis, A prospective study. *Arch Otolaryngol Head Neck Surg* 117: 87-90, 1991
- McLean NR, Harrop-Griffiths RF, Shaw HJ, Trott PA: Fine needle aspiration cytology in the head and neck region. *Br J Plast Surg* 42: 447-450, 1989
- Patra AK, Nanda BK, Mohapatra BK, Panda AK: Diagnosis of lymphadenopathy by fine needle aspiration cytology. *Indian J Pathol Microbiol* 26: 273-278, 1983 Quoted by Lau SK, Wei WE, Kwan S, Yew WW: Combined use of fine-needle aspiration cytologic examination and tuberculin skin test in the diagnosis of cervical tuberculous lymphadenitis, A prospective study. *Arch Otolaryngol Head Neck Surg* 117: 87-90, 1991
- Radhika S, Gupta SK, Chakrabarti A, Rajwanshi A, Joshi K: Role of culture for mycobacteria in fine-needle aspiration diagnosis of tuberculous lymphadenitis. *Diag Cytopathol* 5: 260-262, 1989
- Rajwanishi A, Bhambani S, Das DK: Fine needle aspiration cytology diagnosis of tuberculosis. *Diagn Cytopathol* 5: 260-262, 1989
- Suen JY, Goepfert H: Editorial standardization of neck dissection nomenclature. *Head Neck Surg* 10: 75-79, 1987